

Pulp canal obliteration after extrusive and lateral luxation in young permanent teeth: A scoping review



E. Spinas, M. Deias, A. Mameli,
L. Giannetti*

Department of Surgical Sciences, Sports Dental
Research Center, University of Cagliari, Cagliari, Italy
*Department of Surgical Sciences, Pedodontics
Division, University of Modena-Reggio, Modena, Italy

E-mail: enricospinas@tiscali.it

DOI 10.23804/ejpd.2021.22.01.10

Abstract

Aim In the literature, no single therapeutic approach is preferred for treating dental pulp responses such as pulp canal obliteration (PCO). Some authors still recommend preventive endodontic treatment, whereas others choose not to intervene, to avoid causing possible iatrogenic complications. This review was conducted to explore, in the current scientific literature, the degree of knowledge concerning the onset and development of PCO and pulp necrosis (PN) following dental trauma (i.e. extrusive luxation and lateral luxation) in children and young adults (6-20 years). The authors also evaluated whether and to what extent the stage of dental root development at the time of traumatic dental injury (TDI) influences these pulp responses, and whether PN can arise in teeth already affected by PCO.

Material and methods The literature search was carried out during the period October 2019 to January 2020, using the following databases: PubMed/MEDLINE, SCOPUS and Web of Science. Articles in English reporting on young patients with PCO or PN in permanent teeth affected by trauma were included. The research, whose questions were summarised according to the PICO method, considered the following aspects: patient age, type of TDI, stage of root development, initial treatment, presence of calcification or necrosis, time to onset of the two outcomes (PCO and PN), and duration of follow-up. The articles found were evaluated by two reviewers; in the event of disagreement regarding the inclusion of an article, a third reviewer was called upon to decide.

Results The initial screening of the databases, using the selected search keywords, yielded a total of 343 articles. After exclusion of duplicates and articles not meeting the inclusion criteria, 11 articles remained. Of these, only four completely met the inclusion criteria. Closer analysis of these four publications revealed that they would not easily yield standardised sets of clinical data that might be homogenised in order to produce clear meta-analytical data. Hence the need to limit the data collected to the following seven items: number and type of injuries, type of initial intervention, duration of follow-up, main pulp responses, number and type of pulp responses.

Conclusions PCO is a physiological pulp response associated with a traumatic event, usually a luxation injury. It is diagnosed on the basis of combined radiographic and clinical-anamnestic data. Signs of PCO start to appear at around one year after the traumatic event, and its development reaches completion by about five years post-trauma. PN, on the other hand, is clearly apparent within the first year. Endodontic treatment, be it carried out as a preventive measure or following detection of PCO, is inappropriate and can cause serious iatrogenic damage. Treatment is indicated only in cases of definite PN.

KEYWORDS Dental trauma, Pulp Canal Obliteration, Pulp Necrosis, Luxation injuries, Young permanent teeth.

Introduction

Pulp canal obliteration (PCO), which is often associated with luxation injuries to the teeth [Andreasen et al., 1987; Bastos and Cortes, 2018], is a specific histological phenomenon characterised by gradual, progressive and excessive deposition of reparative dentin within the root canal walls. Resulting from a process of pulp revascularisation, it mainly affects immature teeth [Andreasen, 1970; Jacobsen and Kerekes, 1977; Andreasen et al., 1987; Oikarinen et al., 1987; Crona-Larsson et al., 1991; Robertson et al., 1996; Hecova et al., 2010; Lee et al., 2003; Rocha Lima et al., 2015; Lin et al., 2016; Yu and Abbott, 2016; Cantekin et al., 2014; Spinas et al. 2020]. Unlike pulp necrosis (PN), which is also often caused by traumatic luxation injuries, and is in all respects a pathological process, PCO should not be regarded as a pathological response [Andreasen, 1989]. Pulp canal obliteration is a transformation that can be seen on routine intraoral radiographs as a gradual reduction in the size of the pulp chamber and narrowing of the root canal. It leads, within a few years, to partial or total obliteration of the pulp canal system and progressively reduced responses on pulp sensitivity testing [Bastos and Cortes, 2018; Oginni et al., 2009]. On clinical examination, the crown will eventually appear discoloured, usually turning yellow (67%–79%) [Jacobsen and Kerekes, 1977; Oginni et al., 2009] or, much less frequently (2.5%), grey [Andreasen et al., 1987; Robertson et al., 1996]. A partially negative response on pulp sensitivity testing is a constant finding, sometimes leading to total loss of pulp sensitivity by 24–36 months post-trauma. Percussion and palpation tests are normal.

It has been shown that certain types of TDI, such as extrusive luxation [Andreasen et al., 1987] and lateral luxation, are more likely than others to lead to the onset of PCO rather than PN. The same applies to vital young permanent teeth that were immediately replanted after avulsion, which, still having open root apices or an immature root canal system, are more likely to develop PCO than PN [Andreasen, 1970; Jacobsen and Kerekes, 1977; Andreasen et al., 1987; Oikarinen et al., 1987; Crona-Larsson et al., 1991; Robertson et al., 1996; Hecova et

al., 2010; Lee et al., 2003; Rocha Lima et al., 2015; Lin et al., 2016; Yu and Abbott, 2016; Spinas et al., 2019].

In the literature, no single therapeutic approach is preferred for treating dental pulp responses such as PCO. Some authors still recommend preventive endodontic treatment in the presence of signs of pulp repair processes, or even when the onset of such processes is only suspected [de Toubes et al., 2017; Soares et al., 2015; Shuler et al., 1994; Schindler and Gullickson, 1988]. However, such treatments can often lead to serious iatrogenic errors (perforations, instrument fractures); furthermore, endodontic therapies are unsuitable for immature teeth which have structurally weak root canal walls that are easily prone to fracture [McCabe and Dummer, 2012].

This review of the current scientific literature was conducted to ascertain the frequency and time of onset of PCO and PN following extrusive/lateral luxation injuries in children and young people (6-20 years), comparing teeth with immature versus those with mature apices at the time of the trauma. A further aim of the study was to seek to provide clinicians with valid therapeutic recommendations, with a view to avoiding unnecessary treatments or ones liable to lead to serious complications.

Materials and methods

The authors performed this scoping review of the literature using the method described by Arksey and O'Malley [2007], and also recently discussed by Zachary Munn et al. [2018]. Essentially, it consists of 5 stages: identifying the research question; identifying relevant studies; study selection; charting the data; and collating, summarising and reporting the results.

In accordance with the 2015 PRISMA guidelines [Moher et al., 2015], a work protocol was drawn up, setting out the steps in the literature review process.

- 1 Research design and formulation of the questions.
- 2 Selection of the keywords for the database searches.
- 3 Definition of the inclusion and exclusion criteria.
- 4 Literature search and listing of bibliographic citations deemed pertinent.
- 5 Study selection process.
- 6 Charting the data.
- 7 Selected data collation and summarising, and finally.
- 8 Discussion of the results drawn from the included articles.

Purpose of the work

The purpose of our work was to explore, in the scientific literature, current knowledge on the frequency and time of onset of PCO and PN after TDI, specifically extrusive and lateral luxation. A further aim was to evaluate whether and to what extent the stage of dental root development at the time of the trauma influences these pulp responses. A clinically important question also addressed in the study was whether PN can arise in teeth already affected by PCO.

Research questions

Our research focused on the following aspects.

- 1 The age range of patients at the time of the TDI.
- 2 The type of luxation injury sustained (extrusive or lateral).
- 3 The stage of root development at the time of the TDI (considering teeth with open apices versus teeth with closed apices).
- 4 The emergency interventions performed immediately after the trauma (manual repositioning or flexible/rigid splinting,

or both).

- 5 The time of onset of PCO or PN after traumatic luxation injury.
- 6 The time to completion of the PCO.
- 7 The availability of appropriate diagnostic tests (intraoral radiographs, hot and/or cold sensitivity tests and/or EPT, inspection, palpation, percussion).
- 8 The duration of the follow-up.

Selection criteria

The search strategy was based on the PICO method [Cumpston et al., 2019], as follows.

Population. We considered studies in subjects aged between 6 and 20 years with permanent teeth affected by extrusive or lateral luxation injuries.

Intervention. We considered the following immediate post-trauma interventions: manual repositioning and flexible/rigid splinting, or both.

Comparison. We compared various aspects: Teeth affected by extrusive luxation injury versus laterally luxated teeth, the onset of PCO versus PN after extrusive luxation and after lateral luxation, and the involvement of teeth with immature roots (open apices) versus teeth with mature roots (closed apices).

Outcomes. We considered the number of cases of PCO and of PN in teeth affected by extrusive luxation; the number of cases of PCO and of PN in teeth affected by lateral luxation; the number of luxated teeth showing pulp responses (PCO or PN), and the number of luxated teeth without these responses; and the number of cases of secondary PN, i.e. PN in teeth already affected by PCO.

Articles in English were selected with no restriction on the date of publication. Included studies could be randomised clinical trials, observational studies (with cohort, case-control or cross-sectional designs), clinical case series or case reports. Reviews, *in vitro* or animal studies, editorials, conference abstracts, letters and comments were excluded.

Inclusion and exclusion criteria are summarised in Figure 1.

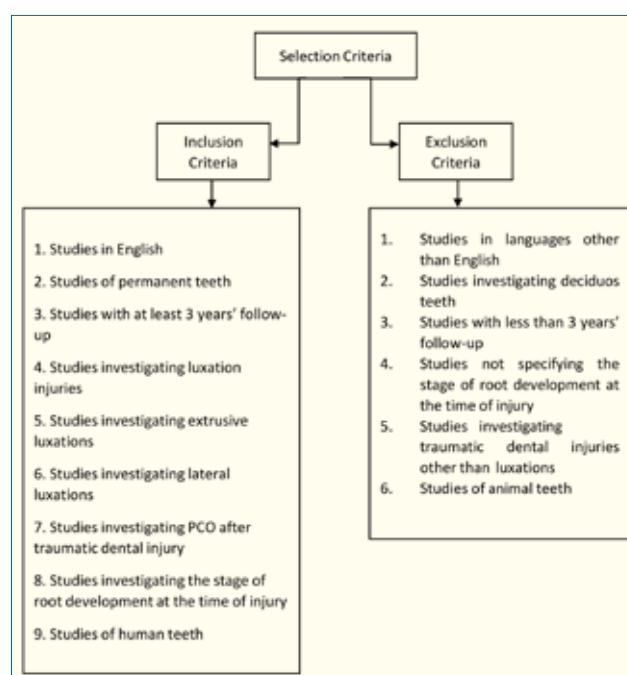


FIG. 1 Diagram showing the inclusion and exclusion criteria used for this review.

The search strategy

The search was carried out during the period October 2019 to January 2020, using the following databases: PubMed/MEDLINE, SCOPUS and Web of Science.

The following keywords were used: Pulp Canal Obliteration AND Permanent Tooth/Teeth, Pulp Canal Obliteration AND Extrusive Luxated Tooth/Teeth, Pulp Canal Obliteration AND Laterally Luxated Tooth/Teeth, Pulp Canal Obliteration AND Luxated Permanent Tooth/Teeth, Luxation Injuries IN Permanent Tooth/Teeth, Pulp Canal Obliteration AND Luxation Injuries.

Two reviewers (MD and ES) independently selected relevant studies by title/abstract or, if these elements were inadequate, by full text reading. The two reviewers met to finalise the selection. Any disagreements were resolved by a third reviewer (AM), who decided whether or not to include the article in question.

Study quality assessment

The three reviewers (MD, ES and AM) independently assessed the quality of the pre-selected studies. The kappa coefficient was used to evaluate the level of agreement between them, and it was found to be "moderate" [Landis and Koch, 1977]. Any disagreements were resolved through discussion and efforts to find a solution deemed valid by all three reviewers.

Data extraction

Two reviewers (MD and ES) extracted the following data from the articles: Publication date, authors, age range of the patients at the time of the TDI, type of luxation injury (extrusive or lateral), duration of follow-up, the stage of dental root development at the time of the trauma (open apices or closed apices), and the main dental pulp outcomes (i.e. the presence of PCO or PN). Where possible, the authors noted the time of PCO onset, the time of PCO completion, and the time of onset of PN after the initial trauma. Finally, cases of secondary PN, i.e. involving teeth

already affected by PCO, were also noted.

The data extracted from the included studies were entered into a Microsoft Excel 2016 spreadsheet for analysis (Table 1).

Results

Results of the literature search

Figure 2 shows the flowchart and search strategy used to select the included articles. The initial search, based on evaluation of titles/abstracts, yielded a total of 343 potentially relevant articles. After careful screening, 13 articles were eliminated because they were duplicates. Of the remaining 330 articles, a further 319 were eliminated based on the exclusion criteria. Only 11 studies were deemed suitable for full-text reading, after which only four papers completely met our inclusion criteria. Although all 11 dealt with the onset of PCO, in all cases following TDI (extrusive or lateral luxation), only the final four papers also specified the stage of dental root development at the time of the trauma. This was an aspect of interest to us, as we wished to explore whether it may determine differences in complications during the follow-up. Table 2 shows the main characteristics of the four included studies (first author, year of publication, study title and type), while Table 3 shows their main results (duration of follow-up, number of cases with each type of injury, main pulp responses).

Discussion and conclusions

Pulp canal obliteration, also known as calcific metamorphosis of the dental pulp, is a physiological process consisting of uncontrolled deposition of reparative dentin by odontoblasts in a tooth that has experienced trauma [Torabinejad et al., 2015].

This condition is more likely to be observed in young

Author and year	N° of samples	N° of Extr. Lux.	N° of Lat. Lux.	PCO	PCO in EL	PCO in LL	Time of onset of PCO after trauma	Type of treatment	Complete PCO	PN	PN in EL	PN in LL	Time of onset of PN after trauma	PN after PCO	Clinical examination (PN)	Follow-up (mean)
Andreassen 1987	165	48	117	yes	19 with open apices, 3 with closed apices	22 with open apices, 8 with closed apices	≤1 yr	Manual repositioning and splinting	5 yr	yes	2 with open apices, 11 with closed apices	3 with open apices, 68 with closed apices	3m	1 tooth	Clinical examination, X-ray and DPT	3.6 yr
Lee 2003	55	54	/	yes	16 with open apices, 3 with closed apices	/	≤1 yr	Manual repositioning and splinting	/	yes	11 with open apices, 12 with closed apices	/	≤1y	2 teeth	Clinical examination, X-ray and DPT	3 yr
Hecova 2010	296	89	207	yes	5 with open apices, 7 with closed apices	23 with open apices, 8 with closed apices	≤5 yr	Manual repositioning and splinting	≤5 yr	yes	2 with open apices, 24 with closed apices	9 with open apices, 89 with closed apices	≤5y	0	Clinical examination, X-ray and DPT	5 yr
Nikoui 2003	58	/	58	yes	/	6 with open apices, 17 with closed apices	≤1 yr	Manual repositioning and splinting	/	yes	/	3 with open apices, 20 with closed apices	≤1y	0	X-ray and DPT	4 yr

Legend: PCO = pulp canal obliteration; PN = pulp necrosis; EL = extrusive luxation; LL = lateral luxation; y = time expressed in year/s; m = time expressed in month/s; DPT = dental pulp test

TABLE 1 Data from the four articles included in the review.

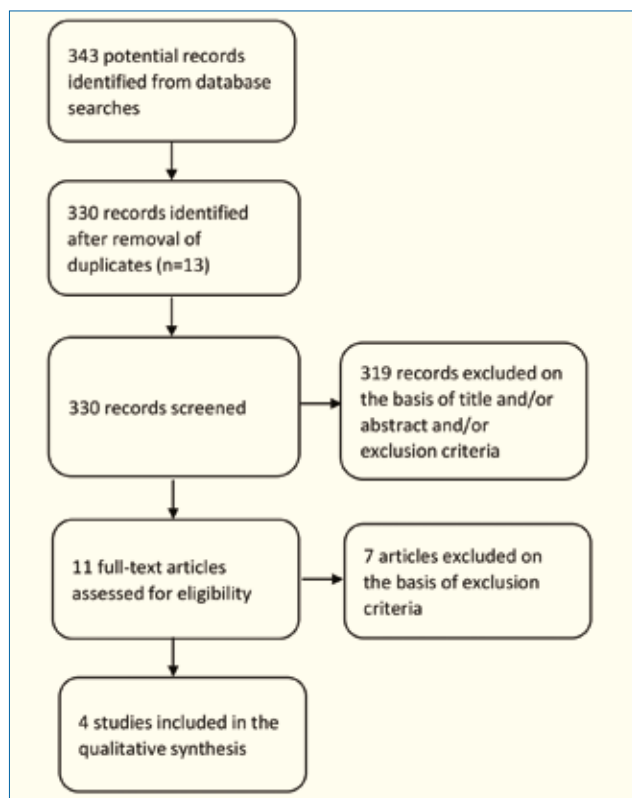


FIG. 2 Flowchart of the literature search and selection process.

Author, year	Title	Type of study
F.M. Andreasen, 1987	Occurrence of pulp canal obliteration after luxation injuries in the permanent dentition.	Prospective cohort study
M. Nikoui, 2003	Clinical outcomes for permanent incisor luxations in a pediatric population. III. Lateral Luxations.	Longitudinal study
R. Lee, 2003	Clinical outcomes for permanent incisor luxation on a pediatric population. II. Extrusions.	Longitudinal study
H. Hecova, 2010	A retrospective study of 889 injured permanent teeth.	Retrospective cohort study

TABLE 2 Summary of the main characteristics of the included studies.

permanent teeth, particularly those that, at the time of the trauma, had open apices or an immature root canal system [Caprioglio et al., 2014]. It also seems to occur more frequently following certain types of TDI, such as extrusive luxation and lateral luxation, and also in avulsed teeth that were immediately replanted [Oikarinen et al., 1987; Biagi, 2014].

Histological changes showing the onset of PCO are an important finding, although still not sufficiently well known in clinical settings, where the condition only comes to light at a later stage. Clinically, it is identified by yellowish discolouration of the crown, a total lack of response to thermal

Andreasen, 1987				
Follow-up (mean)= 3.6 years				
Type of injury	PCO		PN	
Extrusive luxation Total = 48	Open apices	19	Open apices	2
	Closed apices	3	Closed apices	11
Lateral luxation Total = 117	Open apices	22	Open apices	3
	Closed apices	8	Closed apices	68

Hecova, 2010				
Follow-up (mean)= 5 years				
Type of injury	PCO		PN	
Extrusive luxation Total = 89	Open apices	5	Open apices	2
	Closed apices	7	Closed apices	24
Lateral luxation Total = 207	Open apices	23	Open apices	9
	Closed apices	8	Closed apices	89

Nikoui, 2003				
Follow-up (mean)= 4 years				
Type of injury	PCO		PN	
Lateral luxation Total = 58	Open apices	6	Open apices	3
	Closed apices	17	Closed apices	20

Lee, 2003				
Follow-up (mean)= 3 years				
Type of injury	PCO		PN	
Extrusive luxation Total = 54	Open apices	16	Open apices	0
	Closed apices	3	Closed apices	2

TABLE 3 Main data extracted from the 4 articles included in the review.

	Total cases	No reaction after trauma	Teeth with reaction	PCO	PN	Open apex	Closed apex
Extrusive Luxation	191	76	115	53	62	40 (PCO) 15 (PN)	13 (PCO) 47 (PN)
Lateral Luxation	382	106	276	84	192	51 (PCO) 15 (PN)	33 (PCO) 177 (PN)

TABLE 4 Developed PCO e PN following trauma reaction.

stimuli, or the finding of complete or partial obliteration of the pulp system on conventional intraoral dental radiography [Andreasen et al., 1987; Kuyk and Walton, 1990].

In the present study, only four papers dealing with this topic were selected on the basis of their adherence to the inclusion criteria set out [Andreasen et al., 1987; Lee et al., 2003; Nikoui et al., 2003; Hecova et al., 2010], and therefore

included in our analysis.

The four articles reported a total of 573 luxated teeth (191 affected by extrusive and 382 by lateral luxation). In detail, Andreasen et al. [1987] reported 48 extruded and 117 laterally luxated teeth; Lee et al., [2003] 54 extruded teeth; Nikoui et al., [2003] 58 laterally luxated teeth; and Hecova et al. [2010] 89 extruded and 207 laterally luxated teeth.

The age of the patients described in these studies ranged from 6 to 20 years, and they were followed-up for 3 to 5 years, which is consistent with the 2012 recommendations issued by the International Association of Dental Traumatology (IADT) [Andreasen et al., 2012]. According to the IADT dental trauma guidelines, follow-up after extrusive or lateral luxation injury should consist of: clinical and radiographic examination + splint removal two weeks post-trauma in the case of extrusive luxation injuries; and clinical and radiographic examination two weeks post-trauma followed by splint removal four weeks post-trauma in the case of lateral luxations. In both cases, these appointments should be followed by clinical and radiographic examinations at six weeks, six months and 12 months, and then annual check-ups for the five years thereafter [Andreasen et al., 2012].

Of the 191 teeth that suffered extrusive luxation, only 115 showed signs of PCO or PN after the trauma, whereas the other 76 showed no pulp response. In detail, PCO was found in 53/115 (40 with open apices and 13 with closed apices), while PN was found in 62/115 teeth (15 with open apices and in 47 with closed apices) (Table 4).

Of the 382 laterally luxated teeth, 276 developed PCO or PN in response to the trauma, whereas the other 106 recovered without exhibiting pulp responses. In detail, PCO was diagnosed in 84/382 teeth (51 with open apices and 33 with closed apices), while PN was diagnosed in 192/382 teeth (just 15 with open apices and 177 with closed apices) (Table 4).

A descriptive analysis of the data, comparing the two types of response, reveals that in the larger sample of laterally luxated teeth (382 teeth, versus 191 with extrusive luxation), PN was clearly more frequent (found in 192/382) than PCO (84/382).

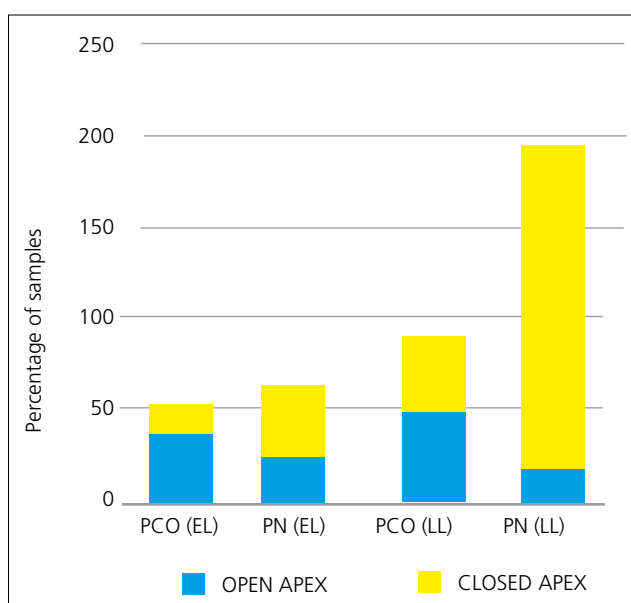


FIG. 3 Rates of pulp necrosis (PN) and pulp canal obliteration (PCO) in extrusive luxation (EL) and in lateral luxation (LL) expressed as number of cases.

In these laterally luxated teeth, PN was far more likely to occur in teeth with closed apices (177/192) as opposed to open apices (15/192) [Andreasen et al.; Nikoui et al., 2003; Hecova et al., 2010] (Fig. 3).

Pulp canal obliteration was also found to be more likely to develop in luxated teeth showing an immature root system. Indeed, of the 53 teeth showing extrusive luxation and PCO, 40 had open apices. Young teeth have a greater capacity for pulp repair and a greater vascular-cellular healing capacity compared with mature teeth, which are instead more likely to develop PN. This is borne out by the fact that 47 of the 62 extrusive luxated teeth exhibiting PN had closed apices [Jacobsen and Kerekes, 1977; Oikarinen et al., 1987; Robertson et al., 1996; Hecova et al., 2010; Lee et al., 2003; Rocha Lima et al., 2015; Lin et al., 2016; Yu and Abbott, 2016; Spinas et al. 2020].

As regards the initial question of the emergency interventions performed immediately after the trauma, the protocol suggested by Andreasen [1970], involving manual repositioning and splinting of the luxated tooth, was used in all four selected studies. However, Andreasen's paper [1987] was the only one to report detailed data showing that the degree of repositioning and the type of splint used can influence the appearance of PCO. This observation was not confirmed by the other studies considered in the review and it therefore needs to be supported by further clinical evidence [Spinas et al. 2021].

In conclusion, the findings of this review of the literature prompt six key clinical considerations, useful for clinicians faced with the need to treat these conditions.

- 1 PCO is a physiological pulp response that can be linked to a TDI (very often an extrusive or lateral luxation of a tooth with immature root system).
- 2 To diagnose PCO correctly it is necessary to combine the findings of clinical (inspection, palpation, percussion and pulp sensitivity tests) and radiographic investigations [Andreasen and Andreasen, 1985].
- 3 Signs of PCO start to appear at around one year after the traumatic event [Andreasen et al., 1987; Lee et al., 2003; Nikoui et al., 2003], and its development reaches completion by around five years post-trauma [Andreasen et al., 1987; Hecova et al., 2010].
- 4 PN manifests itself during the first year after the trauma [Andreasen et al., 1987; Lee et al., 2003; Nikoui et al., 2003].
- 5 Any endodontic treatment of PCO, undertaken solely with the aim of limiting the process of calcific metamorphosis, is pointless and can lead to serious iatrogenic errors and complications (perforations, breakage of endodontic instruments inside the root canal) [Cvek et al., 1982; McCabe and Dummer, 2012; Shuler et al., 1994]. Furthermore, in many cases the tooth will be left with weakened root canal walls unable to sustain the masticatory load to which, over time, it will be subjected [Cvek et al., 1982; Borssen et al., 2002]. This applies particularly in the case of immature teeth, which already have structurally weak root canal walls that are easily prone to fracture.
- 6 Root canal therapy should be considered and performed according to clear protocols only in confirmed cases of PN (which may be primary or, much less frequently, secondary to PCO). The presence of PN must be ascertained on the basis of persistent negative pulp sensitivity tests supported by radiographic and clinical findings [Andreasen and Andreasen, 1985; Feiglin, 1996; Andreasen et al., 2012; Yu and Abbott, 2016; Spinas et al., 2018].

This review revealed that there are few studies in the scientific literature that can be used to estimate the frequency with which

PN develops after a confirmed diagnosis of PCO. Clarifying this aspect would have important clinical repercussions, making it possible to avoid numerous complex endodontic treatments of immature teeth, which are not only unnecessary, but can also often result in serious iatrogenic damage [McCabe and Dummer, 2012; Shuler et al., 1994]. Of the 411 teeth with pulp responses (PCO and/or PN) reported in the four studies reviewed, only three developed PN after PCO: one reported by Andreasen [1987], and two by Lee [2003]. This aspect was not explored in the other two studies. However, neither group [Andreasen et al., 1987; Lee, 2003] reported important data about these cases, namely:

- 1 The patient age at the time of trauma;
- 2 The type of TDI;
- 3 The stage of dental root development at the time of trauma;
- 4 How PN was diagnosed.

The small size of the sample analysed in this study and the non-homogeneity of the data make it impossible to reach clear and clinically meaningful conclusions. However, we certainly have the impression that PN after PCO is a very rare occurrence, in many cases attributable to subsequent tooth-pulp insults that are independent of the initial traumatic event [Andreasen et al., 1987; Shuler et al., 1994; Robertson et al., 1996; Lee et al., 2003].

Our findings underline the need for further clinical studies based on systematic and standardised data collection [Andreasen and Andreasen, 1985; Andreasen and Kahler, 2015]. This will allow homogenisation of the data, which in turn will facilitate meta-analyses and allow therapeutic information to be drawn from the investigations concerned.

Paediatric dentists must always exercise the utmost caution and adhere strictly to international guidelines and recommendations [Re et al., 2014; Nikolic et al., 2018] to ensure proper protection of their young patients, especially those who have already experienced stressful and disabling dental traumas.

References

- Andreasen FM. Pulpal healing after luxation injuries and root fracture in the permanent dentition. *Endod Dent Traumatol* 1989; 5: 111-31.
- Andreasen FM, Andreasen JO. Diagnosis of luxation injuries: the importance of standardized clinical, radiographic and photographic techniques in clinical investigations. *Endod Dent Traumatol* 1985; 1: 160-9.
- Andreasen FM, Kahler B. Diagnosis of acute dental trauma: the importance of standardized documentation: a review. *Dent Traumatol* 2015; 31: 340-9.
- Andreasen FM, Zhijie Y, Thomsen BL, Andersen PK. Occurrence of pulp canal obliteration after luxation injuries in the permanent dentition. *Endod Dent Traumatol* 1987; 3: 103-15.
- Andreasen JO. Luxation of permanent teeth due to trauma. A clinical and radiographic follow-up study of 189 injured teeth. *Scan J Dent Res* 1970; 78.
- Andreasen JO, Lauridsen E, Gerds TA, Ahrensburg SS. Dental Trauma Guide: a source of evidence-based treatment guidelines for dental trauma. *Dent Traumatol* 2012; 28: 142-7.
- Arskey H, O'Malley L. Scoping studies: towards a methodological framework. *Int J Soc Res* 2007; 8: 13.
- Bastos JV, Cortes MIS. Pulp canal obliteration after traumatic injuries in permanent teeth - scientific fact or fiction? *Braz Oral Res* 2018; 32: e75.
- Biagi R. Pulp and periodontal healing after replantation of a maxillary immature incisor: a 13-year follow-up. *Eur J Paediatr Dent* 2014; 15: 195-8.
- Borssen E, Kallestal C, Holm A K Treatment time of traumatic dental injuries in a cohort of 16-year-olds in northern Sweden. *Acta Odontol Scand* 2002; 60: 265-70.
- Cantekin K, Herdem G, Puduk K. Revascularization in an immature necrotic permanent incisor after severe intrusive luxation injury: a case report. *Eur J Paediatr Dent* 2014; 15: 203-6.
- Caprioglio A, Conti V, Caprioglio C, Caprioglio D. A long-term retrospective clinical study on MTA pulpotomies in immature permanent incisors with complicated crown fractures. *Eur J Paediatr Dent* 2014; 15: 29-34.
- Crona-Larsson G, Bjarnason S, Noren JG. Effect of luxation injuries on permanent teeth. *Endod Dent Traumatol* 1991; 7: 199-206.
- Cumpston M, Li T, Page M J, Chandler J, Welch VA, Higgins JP, Thomas J. Updated guidance for trusted systematic reviews: a new edition of the Cochrane Handbook for Systematic Reviews of Interventions. *Cochrane Database Syst Rev* 2019; 10: ED000142.
- Cvek M, Granath L, Lundberg M. Failures and healing in endodontically treated non-vital anterior teeth with posttraumatically reduced pulpal lumen. *Acta Odontol Scand* 1982; 40: 223-8.
- de Toubes KMS, de Oliveira PAD, Machado SN, Pelosi V, Nunes E, Silveira FF. Clinical approach to pulp canal obliteration: A case series. *Iran Endod J* 2017; 12: 527-533.
- Feiglin B. Dental pulp response to traumatic injuries--a retrospective analysis with case reports. *Endod Dent Traumatol* 1996; 12: 1-8.
- Hecova H, Tzigkounakis V, Merglova V, Netolicky J. A retrospective study of 889 injured permanent teeth. *Dent Traumatol* 2010; 26: 466-75.
- Jacobsen I, Kerekes K. Long-term prognosis of traumatized permanent anterior teeth showing calcifying processes in the pulp cavity. *Scand J Dent Res* 1977; 85: 588-98.
- Kuyk JK, Walton RE. Comparison of the radiographic appearance of root canal size to its actual diameter. *J Endod* 1990; 16: 528-33.
- Landis JR, Koch GG. An application of hierarchical kappa-type statistics in the assessment of majority agreement among multiple observers. *Biometrics* 1977; 33: 363-74.
- Lee R, Barrett EJ, Kenny DJ. Clinical outcomes for permanent incisor luxations in a pediatric population. II. Extrusions. *Dent Traumatol* 2003; 19: 274-9.
- Lin S, Pilosof N, Karawani M, Wigler R, Kaufman A Y, Teich ST. Occurrence and timing of complications following traumatic dental injuries: A retrospective study in a dental trauma department. *J Clin Exp Dent* 2016; 8: e429-e436.
- McCabe PS, Dummer PM. Pulp canal obliteration: an endodontic diagnosis and treatment challenge. *Int Endod J* 2012; 45: 177-97.
- Moher D, Shamseer L, Clarke M, Ghersi D, Liberati A, Petticrew M, Shekelle P, Stewart LA, Group P-P. Preferred reporting items for systematic review and meta-analysis protocols (PRISMA-P) 2015 statement. *Syst Rev* 2015; 4: 1.
- Munn Z, Peters MDJ, Stern C, Tufanaru C, McArthur A, Aromataris E. Systematic review or scoping review? Guidance for authors when choosing between a systematic or scoping review approach. *BMC Med Res Methodol* 2018; 18.
- Nikolic H, Ivancic Jokic N, Bakarcic D, Hrvin S, Jakljevic N Knowledge about emergency procedure in case of dental trauma among paediatricians in Croatia. *Eur J Paediatr Dent* 2018; 19: 277-281.
- Nikouli M, Kenny D J, Barrett E J Clinical outcomes for permanent incisor luxations in a pediatric population. III. Lateral luxations. *Dent Traumatol* 2003; 19: 280-5.
- Oginni AO, Adekoya-Sofowora CA, Kolawole KA. Evaluation of radiographs, clinical signs and symptoms associated with pulp canal obliteration: an aid to treatment decision. *Dent Traumatol* 2009; 25: 620-5.
- Olkarinen K, Gundlach KK, Pfeifer G. Late complications of luxation injuries to teeth. *Endod Dent Traumatol* 1987; 3: 296-303.
- Re D, Augusti D, Paglia G, Augusti G, Cotti E. Treatment of traumatic dental injuries: evaluation of knowledge among Italian dentists. *Eur J Paediatr Dent* 2014; 15: 23-8.
- Robertson A, Andreasen FM, Bergenholtz G, Andreasen JO, Noren JG. Incidence of pulp necrosis subsequent to pulp canal obliteration from trauma of permanent incisors. *J Endod* 1996; 22: 557-60.
- Rocha Lima TF, Nagata JY, de Souza-Filho FJ, de Jesus Soares. A Post-traumatic complications of severe luxations and replanted teeth. *J Contemp Dent Pract* 2015; 16: 13-9.
- Schindler WG, Gullickson DC. Rationale for the management of calcific metamorphosis secondary to traumatic injuries. *J Endod* 1988; 14: 408-12.
- Shuler SE, Howell BT, Green DB. Unusual pattern of pulp canal obliteration following luxation injury. *J Endod* 1994; 20: 460-2.
- Soares AJ, Souza GA, Pereira AC, Vargas-Neto J, Zaia AA, Silva EJ. Frequency of root resorption following trauma to permanent teeth. *J Oral Sci* 2015; 57: 73-8.
- Spinas E, Generali L, Mameli A, Demontis C, Martinelli D, Giannetti L. Delayed tooth replantation and inflammatory root resorption in childhood and adolescence. *J Biol Regul Homeost Agents* 2019; 33: 623-627.
- Spinas E, Pippi L, Dettori C. Extrusive luxation injuries in young patients: A retrospective study with 5-year follow-up. *Dent J* 2020; 8: 136.
- Spinas E, Pippi L, Mezzana S, Giannetti L. Use of orthodontic methods in the treatment of dental luxations: A scoping review. *Dent J* 2021; 9: 18.
- Spinas E, Giannetti L, Mameli A, Re D. Dental injuries in young athletes, a five-year follow-up study. *Eur J Paediatr Dent* 2018; 19: 187-193.
- Torabinejad M, Walton RE, Fouad AF. Endodontics: principles and practice. Fifth edition. ed. St. Louis, Mo.: Elsevier; 2015.
- Yu CY, Abbott PV. Responses of the pulp, periradicular and soft tissues following trauma to the permanent teeth. *Aust Dent J* 2016; 61 Suppl 1: 39-58.