



**UNICA**

UNIVERSITÀ  
DEGLI STUDI  
DI CAGLIARI



**UNICA IRIS Institutional Research Information System**

**This is the Author's [*accepted*] manuscript version of the following contribution:**

Di Matteo A, et al. Power Doppler signal at the enthesis and bone erosions are the most discriminative OMERACT ultrasound lesions for SpA: results from the DEUS (Defining Enthesitis on Ultrasound in Spondyloarthritis) multicentre study. *Ann Rheum Dis.* 2024 Jun 12;83(7):847-857. doi: 10.1136/ard-2023-225443.

**The publisher's version is available at:**

[http://dx.doi.org/\[10.1136/ard-2023-225443.\]](http://dx.doi.org/[10.1136/ard-2023-225443.])

**When citing, please refer to the published version.**

This full text was downloaded from UNICA IRIS <https://iris.unica.it/>

## Title

Power Doppler signal at the enthesis and bone erosions are the most discriminative OMERACT ultrasound lesions for SpA: results from the DEUS (Defining Enthesitis on Ultrasound in Spondyloarthritis) multicentre study

## Authors

Andrea Di Matteo<sup>1,2</sup>, Gianluca Smerilli<sup>1</sup>, Stefano Di Donato<sup>2</sup>, Liu An Ran<sup>\*3</sup>, Andrea Becciolini<sup>\*4</sup>, Tomás Cazenave<sup>\*5</sup>, Federica Camarda<sup>\*6</sup>, Edoardo Cipolletta<sup>\*1</sup>, Davide Corradini<sup>\*7</sup>, Luca Di Geso<sup>\*8</sup>, Juan Jose de Agustin de Oro<sup>\*9</sup>, Eleonora Di Donato<sup>\*4</sup>, Giulia Maria Destro Castaniti<sup>\*6</sup>, Emine Duran<sup>\*10</sup>, Bayram Farisogullari<sup>\*10</sup>, Francesca Francioso<sup>\*1</sup>, Marco Fornaro<sup>\*11</sup>, Pamela Giorgis<sup>\*5</sup>, Amelia Granel<sup>\*12</sup>, Cristina Hernandez Diaz<sup>\*13</sup>, Rudolf Horvath<sup>\*14</sup>, Jana Hurnakova<sup>\*14</sup>, Diogo Jesus<sup>\*15,16</sup>, Omer Karadag<sup>\*10</sup>, Li Ling<sup>\*17</sup>, Josefina Marin<sup>\*18</sup>, María Victoria Martire<sup>\*12</sup>, Helena Marzo-Ortega<sup>\*2</sup>, Xabier Michelena Vega<sup>\*9</sup>, Erica Moscioni<sup>\*1</sup>, Laura Muntean<sup>\*19</sup>, Matteo Piga<sup>\*7</sup>, Lucio Ventura Rios<sup>\*20</sup>, Marcos Gabriel Rosemffet<sup>\*5</sup>, João Rovisco<sup>\*21</sup>, Didem Sahin-Eroglu<sup>\*2</sup>, Fausto Salaffi<sup>\*1</sup>, Liliana Saraiva<sup>\*21</sup>, Crescenzo Scioscia<sup>\*11</sup>, Maria-Magdalena Tamas<sup>\*19</sup>, Shun Tanimura<sup>\*22</sup>, Aliko I Venetsanopoulou<sup>\*23</sup>, Orlando Villota<sup>\*24,25</sup>, Catalina Villota-Eraso<sup>\*24</sup>, Paraksevi V Voulgari<sup>\*23</sup>, Gentiana Vukatana<sup>\*26</sup>, Johana Zacariáz Hereter<sup>\*18</sup>, Walter Grassi<sup>1</sup>, Emilio Filippucci<sup>1</sup>.

## Affiliations

<sup>1</sup>Rheumatology Unit, Department of Clinical and Molecular Sciences, "Carlo Urbani" Hospital, Polytechnic University of Marche, Ancona, Italy

<sup>2</sup>Leeds Institute of Rheumatic and Musculoskeletal Medicine, University of Leeds, Leeds, United Kingdom

<sup>3</sup>Guangdong Cardiovascular Institute, Guangdong Provincial People's Hospital, Guangdong Academy of Medical Sciences, Guangdong, China

<sup>4</sup>Department of Medicine, Internal Medicine and Rheumatology Unit, Azienda Ospedaliero, Universitaria di Parma, Parma, Italy

<sup>5</sup>Institute of Psychophysical Rehabilitation (IREP), Buenos Aires, Argentina

<sup>6</sup>Department of Health Promotion, Mother and Child Care, Internal Medicine and Medical Specialties, Rheumatology Section, University of Palermo, Palermo, Italy

<sup>7</sup>Rheumatology Unit, University Clinic AOU Cagliari, Monserrato, CA, Italy

<sup>8</sup>Department of Internal Medicine, Ospedale Madonna del Soccorso, San Benedetto del Tronto, Marche, Italy

<sup>9</sup>Rheumatology Unit, Vall d'Hebron Hospital Universitari, Vall d'Hebron Barcelona Hospital Campus, Barcelona, Spain

<sup>10</sup>Division of Rheumatology, Department of Internal Medicine, Faculty of Medicine, Hacettepe University, Ankara, Turkey

<sup>11</sup>Department of Precision and Regenerative Medicine and Ionian Area (DiMePRE-J) Rheumatology Unit, University of Bari

<sup>12</sup>Rheumatology, Hospital San Roque de Gonnet, La Plata, Argentina

<sup>13</sup>Rheumatology department Hospital Juárez de México, Mexico City, Mexico

<sup>14</sup>Department of Paediatric and Adult Rheumatology, University Hospital Motol, Prague, Czech Republic

<sup>15</sup>Rheumatology Department, Centro Hospitalar de Leiria, Leiria, Portugal

<sup>16</sup>Faculty of Health Sciences, University of Beira Interior, Covilhã, Portugal

<sup>17</sup>Department of Rheumatology and Immunology, Guangdong Provincial People's Hospital (Guangdong Academy of Medical Sciences), Southern Medical University, Guangdong, China

<sup>18</sup>Rheumatology Unit, Department of Internal Medicine, Hospital Italiano de Buenos Aires, Buenos Aires, Argentina

<sup>19</sup>Rheumatology Department, "Iuliu Hatieganu" University of Medicine and Pharmacy, Cluj Napoca, Romania

<sup>20</sup>Division of Rheumatology, National Institute of Rehabilitation Luis Guillermo Ibarra Ibarra, Mexico City, Mexico

<sup>21</sup>Centro Hospitalar e Universitário de Coimbra Medicine Faculty, University of Coimbra

<sup>22</sup>Department of Rheumatology, Hokkaido Medical Center for Rheumatic Diseases, Sapporo, Japan

<sup>23</sup>Department of Rheumatology, School of Health Sciences, Faculty of Medicine, University of Ioannina, Ioannina, Greece

<sup>24</sup>IPS Servicio Integral de Reumatología e Inmunología Doctor Orlando Villota, Pasto, Colombia.

<sup>25</sup>Division of Rheumatology, Fundación Hospital San Pedro, Pasto, Colombia

<sup>26</sup>Rheumatology Unit, IRCCS Policlinico S. Orsola-Malpighi, Bologna, Italy

\*these authors have been listed in alphabetical order

## **Objectives**

To assess the diagnostic performance and clinical relevance of the OMERACT ultrasound (US) elementary lesions of enthesitis, and of a recently proposed definition for active enthesitis (“active enthesitis”), in spondyloarthritis (SpA).

## **Methods**

In this multicentric study (20 rheumatology centres), the 2018 OMERACT US lesions of enthesitis were evaluated at the large entheses of the lower limbs in 413 SpA patients (axial SpA and psoriatic arthritis) and 282 disease controls (osteoarthritis and fibromyalgia). “Active enthesitis” was defined as power Doppler at the entheses (PD)  $\geq 1$  plus enthesal thickening and/or hypoechoic areas, or PD  $> 1$ .

## **Results**

In univariate analysis, all OMERACT lesions but enthesophytes/calcifications were significantly associated with SpA. Only PD [OR=8.77, 95%CI 4.40-19.2,  $p < 0.001$ ] and bone erosions (OR=4.75, 95%CI 2.43-10.1,  $p < 0.001$ ) retained this association in multivariate analysis. “Active enthesitis” was strongly associated with SpA in multivariate analysis (OR=9.20, 95%CI 4.21-23.20,  $p < 0.001$ ). Among the lower limb entheses, only the Achilles tendon showed a significant association with SpA in multivariate analysis (OR=1.93, 95%CI 1.30-2.88,  $p < 0.001$ ). Unlike the individual OMERACT US lesions of enthesitis, “active enthesitis” showed a consistent association with SpA patients’ clinical features of disease activity/severity in the multivariate analyses.

## **Conclusions**

The results of this large multi-centric study showed different diagnostic performances of the OMERACT US lesions of enthesitis in SpA patients. PD and bone erosions and the Achilles tendon entheses were respectively the most discriminative US lesions and enthesal site for the diagnosis of SpA. “Active enthesitis” could improve specificity and clinical relevance of US enthesitis in SpA.

#### **WHAT IS ALREADY KNOWN ABOUT THIS SUBJECT?**

- The Outcome Measures in Rheumatology (OMERACT) group has recently defined six ultrasound (US) elementary lesions of enthesitis in SpA.
- Subsequently, multiple studies have revealed a high prevalence of these US lesions in patients with non-inflammatory conditions and in healthy subjects, thus questioning the diagnostic accuracy and discriminant value of the OMERACT definitions.

#### **WHAT DOES THIS STUDY ADD?**

- In this large multicentric study, power Doppler at the enthesis and bone erosions were the most discriminative US lesions for the diagnosis of SpA, while the Achilles tendon enthesis was the most informative enthesial site.
- “Active enthesitis”, which was recently proposed by our research group, could improve specificity and clinical relevance of US enthesitis in SpA.

#### **HOW MIGHT THIS IMPACT ON CLINICAL PRACTICE?**

- The different discriminative value of the individual US lesions of enthesitis, and their topographic distribution, should be considered in the US assessment of enthesitis in SpA.
- Differentiating between SpA-related enthesitis and other types of enthesial pathology (i.e., enthesopathy) could improve the clinical usefulness of US enthesitis in SpA patients.

## Introduction

The enthesis is the site of attachment of tendons, ligaments, and joint capsules into the bone (1). Enthesitis (i.e., inflammation of the enthesis) plays a key role in the pathogenesis, diagnosis, and management of patients with spondyloarthritis (SpA), including axial SpA (axSpA) and psoriatic arthritis (PsA) (2-4). Enthesitis is part of the Assessment of SpondyloArthritis international Society (ASAS) classification criteria for axSpA and Classification criteria for Psoriatic ARthritis (CASPAR) (5-7).

The physical examination, which is routinely used in clinical practice for the assessment of enthesitis, is often inaccurate (8). Therefore, interest has grown toward the use of imaging, and in particular ultrasound (US), for the correct evaluation of enthesitis in SpA patients (9,10).

In the past two decades, the Outcome Measures in Rheumatology (OMERACT) US Task Force, as well as other international research groups, have put considerable effort to improve standardisation of US in the assessment of enthesitis in SpA patients (11,12). In 2014, six US elementary lesions of enthesitis were defined by OMERACT: enthesal thickening, hypoechoic areas, power Doppler (PD) signal at the enthesis, as indicative of “active inflammation”; calcifications, enthesophytes and bone erosions as indicative of “structural damage” (13). In 2018, OMERACT combined these elementary lesions to develop a definition of US enthesitis in SpA: “hypoechoic and/or thickened insertion of the tendon close to the bone (within 2mm from the bony cortex), which exhibits Doppler signal if active, and which may show erosions and enthesophytes/calcifications as a sign of structural damage” (14).

As recently acknowledged by OMERACT, the individual value of the US elementary lesions of enthesitis in the diagnostic work-up of SpA (i.e., differential diagnosis) remains to be defined (15). Several studies have shown that some of these US elementary lesions (i.e., enthesal thickening, hypoechoic areas, enthesophytes) can be detected in patients with non-inflammatory conditions [e.g., fibromyalgia (FBM), dysmetabolic enthesopathies], as well as in healthy subjects (15-20), thus questioning the specificity and diagnostic value of US enthesitis in SpA patients (21).

Our group previously showed a high prevalence of enthesal thickening and hypoechoic areas (i.e., two key US lesions of active inflammation according to OMERACT and entry criteria in the 2018 OMERACT US definition of enthesitis) in a population of asymptomatic healthy subjects (18). Based on these results, we proposed a new definition for “active enthesitis”, which could potentially improve the diagnostic performance of US in the assessment of enthesitis in SpA patients. PD at the enthesis was the entry criteria in this new definition, isolated or in combination with other inflammatory lesions of enthesitis (i.e., enthesal thickening and/or hypoechoic areas) (18,22).

Therefore, the first objective of this study was to evaluate the diagnostic performance of the US elementary lesions of enthesitis as defined by OMERACT and of our recently proposed definition of “active enthesitis”, in patients with SpA (axSpA and PsA), including patients with non-inflammatory rheumatic diseases [osteoarthritis (OA) and FBM] as controls. Secondly, we sought to investigate the correlation between the OMERACT defined US lesions of enthesitis and “active enthesitis”, and the clinical features of SpA patients (i.e., the clinical relevance of the US assessment of enthesitis in this population).

## **Materials and methods**

### *Patients*

This was an observational, cross-sectional, multicentric study. Patients with SpA (axSpA and PsA) were enrolled consecutively according to their respective classification criteria (4-6). Patients with axSpA were also sub-classified into “radiographic” and “non-radiographic” axSpA (23). Patients with non-inflammatory rheumatic diseases (OA and FBM) were enrolled as a control group according to their respective classification criteria (24-27). Age and sex matching were not performed between “cases” (SpA) and “controls” (OA and FBM) due to the different demographic characteristics of these rheumatic diseases (28).

The exclusion criteria of the study were:

- Age <18 years old.
- Previous major knee or ankle surgery or trauma.
- Intense physical activity in the 2 weeks prior to clinical evaluation.
- SpA patients with a concomitant diagnosis of FBM and controls with psoriasis (including family history) and/or inflammatory bowel disease (including family history) and/or recent infectious episodes were excluded.

The following lower limb entheses were assessed by both clinical examination and US:

- The patellar insertion of the quadriceps tendon.
- The patellar and tibial insertion of the patellar tendon.
- The calcaneal insertion of the Achilles tendon and the plantar fascia.

### *Clinical evaluation*

In all patients, the following routine information were collected: age, sex, weight, height, body mass index (BMI), physical activity (times/week), cardiovascular disease (i.e., metabolic syndrome, diabetes,

dyslipidaemia, hypertension), erythrocyte sedimentation rate (ESR), C-reactive protein (CRP), current DMARD therapy (if any), use of non-steroidal or steroidal anti-inflammatory drugs.

In all patients, a rheumatologist performed a physical examination to assess clinical enthesitis. The clinical diagnosis of enthesitis was made in the presence of tenderness of the enthesis on pressure, and/or mobilisation, and/or contraction against resistance and/or swelling at the level of the enthesis (29).

In SpA patients, disease duration, previous episodes of enthesitis (diagnosed by a physician), presence of psoriasis (current or previous), presence of inflammatory bowel disease (current or previous) and HLA-B27 (when clinically indicated) were collected.

The following disease activity indices were also collected:

- Leeds Enthesitis Index (LEI), in SpA patients (30).
- Tender (0/68) (TJC) and swollen (0/66) (SJC) joint count in SpA patients.
- Disease Activity in Psoriatic Arthritis (DAPSA) Score in PsA patients (31,32).
- Ankylosing Spondylitis Disease Activity Score (ASDAS), Bath Ankylosing Spondylitis Disease Activity Index (BASDAI), Bath Ankylosing Spondylitis Functional Index (BASFI) and Bath Ankylosing Spondylitis Metrology Index (BASMI), in axSpA patients (33-36)
- Health Assessment Questionnaire Disability-Index (HAQ) in SpA patients (37).

#### *Ultrasound evaluation*

All patients underwent an US examination of the lower limb entheses on the same day as the clinical evaluation. The US examination was carried out by a rheumatologist taking part in the study for each center, blinded to the patients' clinical data. The details of the US machines, which were used in the different participating centres have been reported in Supplementary Table 1.

Each enthesis was evaluated bilaterally, both in B-mode and PD modality, using longitudinal and transverse scans, according to the EULAR guidelines on the use of musculoskeletal US in rheumatology (38).

The following elementary lesions of enthesitis were evaluated, according to the OMERACT definitions (13): enthesial thickening, hypoechoic areas, PD signal at the enthesis (within 2 mm from the enthesis), enthesophytes, calcifications, and bone erosions. Entesophytes/calcifications were merged into a single lesion according to OMERACT (14). PD outside the enthesis (>2 mm from the enthesis) was also investigated.



PD signal at the enthesis was both assessed as present/absent and according to a semi-quantitative scale from 0 to 3, where [0=absent (i.e., no PD signal); 1 = mild (i.e., separate dot signals or short linear signals); 2=moderate (i.e., PD signal occupying less than half of the enthesis); 3=severe (i.e., PD signal occupying more than half of the enthesis)] (39-41). The OMERACT semi-quantitative Doppler scoring system was published after the current study had been designed and therefore was not used (42). PD signal outside the enthesis was scored as present/absent only.

As previously described by our group, “active enthesitis” was defined as either PD at the enthesis  $\geq 1$  + enthesal thickening and/or hypoechoic areas or PD at the enthesis  $>1$  ( $\pm$  enthesal thickening or hypoechoic areas) (18,22) (Supplementary Figure 1).

Prior to the current study, a web-based inter and intra-reliability exercise was performed by the current authors to evaluate the agreement on the OMERACT US elementary lesions of enthesitis (43).

### **Statistical analysis**

Categorical data were reported as counts and percentages. Comparisons of categorical data were performed using Fisher’s exact test or Pearson’s Chi-squared test, as appropriate. Continuous data were reported as mean (SD) or median (IQR). Normality was assessed with Shapiro-Wilk’s significance test, with graphical check of density plots, and QQ plots. Homogeneity of variance for continuous variables was assessed using F-test. Comparisons of continuous data were performed with Student’s t-test or Wilcoxon’s test, as appropriate. Univariate logistic regression was used to analyse the relationship between the OMERACT US lesions of enthesitis and the diagnosis of SpA. A first multivariate logistic regression model was built including all the US lesions of enthesitis that showed statistical significance at univariate analysis. A second multivariate model was built using the same significant OMERACT elementary lesions plus “active enthesitis”. To avoid collinearity, this latter model excluded the single elementary lesions that were defined by OMERACT as indicative of “active inflammation” (i.e., enthesal thickening, hypoechoic areas, and PD at the enthesis). Further exploratory analyses were performed using univariate and multivariate regression to investigate the relationships between the US findings and SpA patients’ clinical characteristics (i.e., disease activity indices, inflammatory markers, patients’ reported outcomes). For this analysis we used logistic regression models for dichotomous variables, such as the presence of US bone erosions at the enthesis (yes/no). Conversely, linear regression models were used for continuous variables, such as CRP, LEI, TJC, SJC, DAPSA, ASDAS, BASDAI and HAQ. The density distribution of the sum of the OMERACT lesions between SpA patients and controls (at subject level and divided by single enthesis) was compared using Kolmogorov-Smirnov test and corrected using Bonferroni method.

For the calculation of the sample size, we expected a prevalence of PD at the entheses of 20% in patients with SpA and 5% in controls, according to previous studies (8,44). Based on a real-life rheumatology setting, we considered an allocation ratio of 1.5 cases to controls. Setting the power to  $\beta=.85$ , with a significance level to  $\alpha=.5$ , and accounting for continuity correction, the sample for a two-sample test with a two-sided hypothesis was estimated to be of 64 cases and 43 controls. These numbers were multiplied to assess the difference for each of the six OMERACT elementary lesions across cases and controls. Therefore, we estimated a minimum of 384 cases and 258 controls and decided to close recruitment once a minimum of 690 patients was reached, also accounting for potential missing data. Data analysis was conducted using R core team software (<https://www.R-project.org>) and RStudio (PBC, Boston, MA). This study was approved by the ethic committee of the participating centres [leading centre Polytechnic University of Marche, Comitato Etico Regionale delle Marche (CERM n: 50/2021)]. All patients provide informed written consent.

## **Results**

### *Patients*

Twenty rheumatology centres from 11 countries participated in this study. A total of 695 patients [413 with SpA (224 axSpA and 189 PsA,) and 282 controls (144 OA and 138 FMB)] were included. The clinical and demographic characteristics of SpA patients and controls have been reported in Table 1 and Supplementary Table 2. SpA patients presented with a younger age and were more frequently males than controls. On the other hand, no differences between were found regarding BMI, physical activity and comorbidities between these groups. The clinical disease activity indices and therapy of SpA patients and controls have been reported in Supplementary Table 3 and Supplementary Table 4, respectively.

### *Association between US findings and diagnosis of SpA*

Among the OMERACT US elementary lesions of enthesitis, enthesal thickening, hypoechoic areas, PD at the entheses and bone erosions were significantly associated with SpA in the univariate analysis (Table 2). Enthesophytes/calcifications and PD outside the entheses were more frequent in SpA patients than controls, but this difference did not reach statistical significance. Therefore, these two US variables were not included in the multivariate analysis. In addition, “active enthesitis” resulted to be significantly associated with SpA in the univariate analysis.

In the multivariate logistic regression analysis, which included all US elementary lesions that were significantly associated with SpA on the univariable analysis, only PD signal at the entheses [Odds Ratio (OR) 8.77, 95% Confidence Interval (CI) 4.40-19.20,  $p<0.001$ ] and bone erosions (OR 4.75, 95% CI 2.43-

10.10,  $p < 0.001$ ) remained significantly associated with SpA, after adjustment for age and sex (Table 3).

When “active enthesitis” was considered as independent variable in the multivariate analysis (instead of enthesal thickening, hypoechoic areas, and PD at the enthesis, which were collapsed and removed due to collinearity), this finding (OR 9.20, 95% CI 4.21-23.20,  $p < 0.001$ ) and bone erosions (OR 5.22, 95% CI 2.70-11.0,  $p < 0.001$ ) remained significantly associated with SpA.

When considering the presence of  $\geq 1$  US elementary lesion of enthesitis (any), all entheses resulted significantly associated with SpA in the univariate analysis, except for the plantar fascia (Table 4). However, in the multivariate analysis, only the Achilles tendon remained significantly associated with SpA, after adjustment for age and sex.

Regarding the density distribution of the US findings (i.e., the sum of the OMERACT US elementary lesions of enthesitis and “active enthesitis” at subject level and divided by single enthesis), a significant difference between SpA patients and controls was found for all OMERACT US elementary lesions (Supplementary Figure 2) and for the Achilles tendon enthesis (Supplementary Figure 3).

#### *Clinical relevance of the US findings*

The associations between the US findings and SpA patients’ clinical characteristics have been reported in Table 5.

Enthesal thickening, hypoechoic area, PD at the enthesis and “active enthesitis” showed a significant association with BASDAI (axSpA) in the univariate analysis (adjusted  $p$ -value  $< 0.001$  for enthesal thickening and hypoechoic area, adjusted  $p = 0.007$  for PD at the enthesis and adjusted  $p = 0.012$  for “active enthesitis”). However, only hypoechoic area and “active enthesitis” remained significantly associated with BASDAI in the multivariate analysis ( $p = 0.009$  and  $p = 0.002$ , respectively). A positive association was observed between the US features and ASDAS (axSpA), both in the univariate and multivariate analysis.

Enthesal thickening (adjusted  $p < 0.001$ ), hypoechoic areas (adjusted  $p < 0.001$ ), PD at the enthesis (adjusted  $p = 0.004$ ) and “active enthesitis” ( $p = 0.002$ ) showed a significant association with LEI in the univariate analysis. However, in the multivariate analysis, only hypoechoic area and “active enthesitis” remained significantly associated with LEI ( $p = 0.002$  and  $p < 0.001$ , respectively). Interestingly, no significant association was found between any of the US findings and DAPSA (PsA), TJC (SpA) and SJC (SpA) in the univariate analysis (data not shown for TJC and SJC).

The associations between the US findings and the presence of US bone erosions at the enthesis, CRP, and HAQ scores in SpA patients have been illustrated in Table 6. In the univariate analysis, enthesal thickening, hypoechoic areas, PD at the enthesis, enthesophytes/calcifications, and “active enthesitis” were significantly associated with US bone erosions at the enthesis (all  $p < 0.001$ ). In the multivariate analysis, enthesal thickening, PD at the enthesis and “active enthesitis” remained significantly associated with US bone erosions at the enthesis ( $p = 0.032$ ,  $p = 0.015$  and  $p < 0.001$ , respectively).

“Active enthesitis” was the only US finding that was significantly associated with CRP in the univariate analysis (adjusted  $p = 0.045$ ). Finally, a significant association was found between hypoechoic areas (adjusted  $p = 0.021$ ), PD at the enthesis (adjusted  $p = 0.022$ ) “active enthesitis” (adjusted  $p = 0.034$ ) and LEI, which was retained in the multivariate analysis ( $p = 0.037$ ,  $p = 0.039$  and  $p = 0.005$ , respectively).

## **Discussion**

The main aim of this study was to evaluate the diagnostic performances of the OMERACT US elementary lesions of enthesitis (13,14) and our newly proposed definition of “active enthesitis” (18,22) in SpA patients. The current study showed that PD signal at the enthesis and bone erosions were the OMERACT US elementary lesions showing the highest discriminative value between SpA patients and patients with non-inflammatory diseases, such as OA and FBM. Yet, “active enthesitis” determined a nine-fold increase of a diagnosis of SpA in the multivariate analysis, after adjustment for age and sex.

After the publication of the OMERACT US elementary lesions of enthesitis in SpA (13,14), multiple studies have reported a relatively high prevalence of these lesions in patients with non-inflammatory conditions (e.g., metabolic syndrome, FBM and healthy subjects) albeit variable and depending on the type of US finding (16-20). Thus, given the increasing use of US in routine clinical practice for the assessment of enthesitis, it is relevant to investigate on the individual weight of the different US lesions for the identification of SpA-related enthesitis vs enthesal involvement that can occur in non-inflammatory conditions (i.e., enthesopathy).

Previous studies have shown a wide variability in the prevalence and distribution of the US elementary lesions in SpA (45-47). In the current study, PD signal at the enthesis and bone erosions showed the lowest prevalence (but highest specificity) in SpA patients among the OMERACT lesions, while enthesal thickening, hypoechoic areas and enthesophyte/calcifications had the highest sensitivity (but lowest specificity).

Overall, our results showed that all the OMERACT US lesions of enthesitis (including PD outside the enthesis) were more prevalent in SpA patients than in controls, even though results varied at the level

of the single entheses. Therefore, any large enthesis of the lower limbs is potentially involved in SpA with a wide spectrum of pathological US abnormalities. Arguably, the presence of factors which are related to the anatomical and histological characteristics of the different entheses, as well as the different type of biomechanical stress to which these are subjected, could potentially influence which US lesion is observed at a given anatomic site. Another potential explanation for this variability is linked to the intrinsic characteristics of US. Indeed, it is well known that the depth of the examined structure on US might affect the sensitivity of PD, and this for example could explain the virtual absence of PD at the calcaneal insertion of the plantar fascia (2.9% in SpA patients, 0% in controls), which emerged in the current study.

Our results also highlighted the importance of the topographic distribution of the US lesions. All the entheses included in the current study resulted to be associated with SpA in the univariate analysis, with the exception of the plantar fascia. However, the enthesis of the Achilles tendon was the only which remained associated with SpA in the multivariable analysis. Similar results were observed when the distribution of the sum of the OMERACT US lesions of enthesitis was taken into account (Supplementary Figure 3). In the diagnostic work-up of SpA patients, performing a multi-step US approach according to a hierarchical order of the enthesis, in terms of diagnostic clinical relevance, might increase the feasibility of this imaging tool in routine clinical practice. Our study suggests that the enthesis of the Achilles tendon should represent the first anatomical site to be evaluated, with the possibility of extending the sonographic study to other anatomical targets in doubtful cases (48).

Our current results also demonstrated a very good diagnostic performance of our recently proposed definition of “active enthesitis”. The OMERACT definition for US enthesitis in SpA (14) considers as necessary the presence of enthesal thickening and/or hypoechoic areas to detect enthesitis, and therefore to assess its activity with PD. Conversely, in our proposed definition of “active enthesitis”, PD at the enthesis is the criteria sine qua non, isolated (when PD moderate or higher grades are present) or in combination with other lesions of active inflammation (i.e., enthesal thickening and/or hypoechoic areas). As shown in Table 2, PD alone determined a 10% increase in the number of SpA patients fulfilling “active enthesitis” compared to the OMERACT definition. Indeed, 80 SpA patients fulfilled the definition of “active enthesitis” having PD  $\geq 1$  + enthesal thickening and/or hypoechoic areas (and these would have “active inflammation” according to the OMERACT definition). However, 89 SpA patients had PD  $>1$  without enthesal thickening or hypoechoic areas, which would not be defined as having “active enthesitis” if the OMERACT definition was used. Compared to PD signal at the enthesis (the only inflammatory lesion associated with SpA diagnosis in the multivariate analysis), our newly proposed definition of “active enthesitis” had a slightly superior specificity (96.5% vs 97.5%, respectively), but lower sensitivity (27.1% vs 21.6, respectively). However, the overall diagnostic

accuracy was not higher for “active enthesitis” compared to PD at the enthesis, thus confirming the diagnostic power of this latter US finding for the identification of SpA-enthesitis.

In the current study, we investigated the correlations between the US findings and SpA patients’ clinical features, including imaging, disease activity, and patient reported outcome. In the univariate analysis, there was a significant association between the OMERACT US inflammatory lesions (i.e., enthesal thickening, hypoechoic areas and PD at the enthesis) and several SpA clinical features, which suggests a good correlation between US-detected and clinically measured inflammation. While these inflammatory lesions were inconsistently associated with the different clinical SpA features in the multivariate analysis, “active enthesitis” showed a statistically significant association with the majority of them, including BASDAI, ASDAS, LEI, US bone erosions and HAQ. Therefore, “active enthesitis” could potentially identify a more active or severe disease profile. However, the cross-sectional design of the current study does not allow drawing any conclusion of the potential prognostic value of these US features (i.e., worse disease outcome, implications on therapeutic decisions), which will have to be investigated by future studies.

In SpA, the univariate analysis showed a significant association between all OMERACT US elementary lesions and US bone erosions at the enthesis, except for PD outside the enthesis, thus confirming the relevance of the location of the US findings (i.e., proximity to the bone), as previously highlighted by OMERACT (13,14). Interestingly, in the multivariate analysis, only “active enthesitis” retained a significant association with US bone erosions at the enthesis. Finally, the lack of association between the OMERACT US elementary lesions and DAPSA, TJC or SJC was only partially unexpected. Indeed, several studies have demonstrated that the enthesis and joint are different domains in the SpA disease, with a different treatment response (49-52).

The results of this study support the idea that the identification of a limited and reproducible number of US elementary lesions in the main entheses of the lower limbs (especially the Achilles tendon enthesis) allows a much broader characterisation of this key domain of SpA compared to the clinical examination. Interestingly, a higher prevalence of clinical enthesitis was detected in patients with FMB compared SpA patients, which confirms the poor specificity of the physical examination in the assessment of enthesitis.

A strength of our study is the large numbers of centres and rheumatologists (experts in US) participating from multiple countries worldwide. All investigators were involved in a web-based reliability exercise on the OMERACT US elementary lesions of enthesitis for SpA aimed to calibrate the different operators, and the standardisation of US assessments before study recruitment (43). The results of this previous study showed a good inter and intra-reliability for PD at the enthesis and bone

erosions (which were the most discriminative lesions for the diagnosis of SpA in the current study), while lower reliability results were obtained for hypoechoic areas and enthesal thickening.

A limitation of the current study is that SpA patients and controls (OA and FBM) were not matched for age and gender. Given the different epidemiological and demographic characteristics of these diseases, matching for these parameters could have significantly delayed enrolment. For this reason, we have adjusted all relevant analyses for these two demographic variables. In addition, this was a 'real world' study across different countries and the relatively wide inclusion criteria (with very few exclusion criteria) wanted to reflect the characteristics of this type of study. As expected, populations included were quite heterogeneous from a clinical point of view, especially the SpA patients, which had different disease duration, disease activity status (albeit evenly distributed), and treatments. Finally, the correlation between the US features and the presence of radiographic joint damage (at joint or enthesal level) was not evaluated. Previous studies have revealed a potential link between the US features of enthesitis and the presence of joint/enthesal structural damage on x-rays. If confirmed, this association could have further supported the clinical relevance of US enthesitis (53,54).

### **Conclusions**

The current study showed different diagnostic performances of the OMERACT US elementary lesions of enthesitis, thus providing new insights into the clinical usefulness of US in the assessment of enthesitis in SpA patients. PD signal at the enthesis (inflammatory) and bone erosions (structural damage) were the OMERACT US elementary lesions with the strongest association with the diagnosis of SpA. The Achilles tendon was the enthesis with the highest discriminative value between SpA and controls. The different weight and diagnostic value of the individual US lesions of enthesitis, as well as their topographic distribution, should be considered in the US assessment of enthesitis in SpA. Our newly proposed definition for “active enthesitis” could improve specificity and clinical relevance of US assessment of enthesitis.

### **Contributions**

ADM, GS, WG, and EF designed the study. ADM wrote the manuscript. SDD carried out the statistical analysis. EC contributed to the statistical analysis. LDG, DSE, FS, and HMO contributed to the analysis of the data and interpretation of results. All other authors were included in the patients' enrolment. All co-authors contributed to revising the manuscript critically and approved the final version to be published.

### **Conflict of interest**

**Please report if any**

<b>Table 1.</b> Demographic and clinical characteristics of the included populations					
	<b>SpA</b>			<b>Controls<sup>##</sup></b>	<b>p-value*</b>
	<b>All</b> n= 413	<b>axSpA</b> n= 224	<b>PsA</b> n= 189	<b>All</b> n=282	
<b>Age, (years [SD])</b>	47.9 (14.0)	44.1 (13.4)	52.4 (13.3)	54.2 (13.9)	<0.001
<b>Female gender (%)</b>	147 (35.6)	72 (32.1)	75 (39.7)	192 (68.1)	<0.001
<b>BMI (IQR)</b>	26.5 (23.6-29.7)	26.3 (23.2-29.8)	26.6 (24.1-29.6)	25.7 (23.5-29.0)	0.11
<b>Physical activity (times/week, median [IQR])</b>	1 (0-3)	2 (0-3)	1 (0-2)	1 (0-3)	0.085
<b>Disease duration (months [IQR])</b>	76 (28-168)	84 (36-197)	72 (24-150)	-	N/A
<b>CRP (mg/dl, [SD])</b>	1.8 (5.1)	1.8 (4.3)	1.8 (4.3)	0.5 (0.5)	<0.001
<b>ESR (mm/h, [SD])</b>	21 (20)	21 (19)	21 (19)	15 (13)	<0.001
<b>Metabolic syndrome (%)</b>	81 (19.6)	38 (17.0)	43 (22.7)	48 (17.0)	0.4
<b>Diabetes (%)</b>	34 (8.2)	10 (4.5)	24 (12.7)	30 (10.6)	0.3
<b>Dyslipidaemia (%)</b>	105 (25.4)	56 (25.0)	49 (25.9)	87 (30.8)	0.092
<b>Hypertension (%)</b>	112 (27.1)	49 (21.9)	63 (22.3)	83 (29.4)	0.5
<b>Psoriasis (previous/current)</b>	174 (42.1)	17 (7.6)	157 (55.7)	-	N/A
<b>IBD (%)</b>	7 (1.7)	5 (2.2)	2 (0.7)	-	N/A
<b>Previous enthesitis (%)</b>	139 (33.6)	79 (35.3)	60 (21.3)	-	N/A
<b>HLA-B27<sup>†</sup>, (%)</b>	167 (70.4)	152 (82.2)	15 (28.8)	-	N/A
<b>Clinical enthesitis (%)</b>	127 (30.7)	68 (30.6)	59 (31.2)	96 (34.0)	0.5

\*between SpA and control groups, false discovery rate correction.

† available for 237 SpA patients (185 axSpA/52 PsA).

## further information about demographic and clinical features of fibromyalgia and osteoarthritis patients have been reported in Supplementary Table 2.

**Acronyms.** **axSpA:** Axial Spondyloarthritis. **BMI:** Body Mass Index. **CRP:** C-Reactive Protein. **ESR:** Erythrocyte Sedimentation Rate. **IBD:** Inflammatory Bowel Disease. **IQR:** Interquartile Range. **PsA:** Psoriatic Arthritis. **SD:** Standard Deviation.



**Table 2.** Prevalence and distribution of the US elementary lesions of enthesitis in patients with SpA (axSpA and PsA) and controls (FBM and OA)

US findings	Quadriceps			Patellar proximal			Patellar distal			Achilles tendon			Plantar fascia			Overall		
	SpA n=413	C n=282	p-value <sup>1</sup>	SpA n=413	C n=282	p-value <sup>1</sup>	SpA n=413	C n=282	p-value <sup>1</sup>	SpA n=413	C n=282	p-value <sup>1</sup>	SpA n=413	C n=282	p-value <sup>1</sup>	SpA n=413	C n=282	p-value <sup>1</sup>
Thickening	75 (18.2%)	42 (15.9%)	>0.9	85 (20.6%)	40 (14.2%)	0.2	92 (22.3%)	47 (16.7%)	0.5	121 (29.3%)	39 (13.8%)	<0.001	123 (29.8%)	69 (24.5%)	0.7	236 (57.1%)	127 (45.0%)	0.012
Hypoechoic area	113 (27.3%)	56 (19.9%)	0.2	80 (19.4%)	31 (11.0%)	0.022	94 (22.7%)	41 (14.5%)	0.050	140 (33.9%)	56 (19.9%)	<0.001	102 (24.7%)	44 (15.6%)	0.023	234 (56.7%)	122 (43%)	0.004
PD at the enthesis	34 (8.2%)	9 (3.2%)	0.047	26 (6.3%)	0 (0%)	<0.001	36 (8.7%)	4 (1.4%)	<0.001	56 (13.6%)	2 (0.7%)	<0.001	12 (2.9%)	0 (0%)	0.013	112 (27.1%)	10 (3.5%)	<0.001
PD outside the enthesis	4 (1.4%)	23 (5.6%)	0.038	15 (3.6%)	3 (1.1%)	0.3	14 (3.4%)	2 (0.7%)	0.14	64 (15.5%)	2 (0.7%)	<0.001	23 (5.6%)	3 (1.1%)	0.013	26 (6.3%)	11 (3.9%)	>0.9
Enth/calc	235 (56.9%)	133 (47.1%)	0.081	123 (29.7%)	50 (17.7%)	0.002	118 (28.5%)	61 (21.6%)	0.3	273 (66.1%)	160 (56.7%)	0.087	137 (33.1%)	63 (22.3%)	0.012	341 (82.6%)	211 (74.8%)	0.092
Erosions	23 (5.6%)	4 (1.4%)	0.038	15 (3.6%)	3 (1.1%)	0.3	14 (3.4%)	2 (0.7%)	0.14	64 (15.5%)	2 (0.7%)	<0.001	23 (5.6%)	3 (1.1%)	0.013	103 (24.9%)	11 (3.9%)	<0.001
“Active enthesitis”*	27 (6.5%)	4 (1.4%)	0.009	22 (5.3%)	0 (0%)	<0.001	26 (6.3%)	3 (1.1%)	0.005	48 (11.6%)	1 (0.4%)	<0.001	10 (2.4%)	0 (0%)	0.042	89 (21.6%)	7 (2.5%)	<0.001

<sup>1</sup> Pearson's Chi-squared test; Fisher's exact test with Bonferroni correction for multiple testing. **Acronyms.** axSpA: Axial Spondyloarthritis. C: Controls. FBM: Fibromyalgia. OA: osteoarthritis. PD: Power Doppler. PsA: Psoriatic Arthritis. SpA: Spondyloarthritis.

\*Of the 89 SpA patient with ‘active enthesitis’, 80 (89.9%) had at least one enthesis with the combination of PD≥1 and enthesal thickening and/or hypoechoic areas, and 14 had PD signal >1 without enthesal thickening or hypoechoic areas (15.7%). Of these 14 patients, 5 satisfied both definition of ‘active’ enthesitis in different entheses, whereas the remaining 9 patients were diagnosed with ‘active enthesitis’ for the isolated presence of PD >1 with no enthesal thickening nor hypoechoic areas (10.1% of the total number of SpA with ‘active enthesitis’).

**Table 3.** Multivariate analysis evaluating the association between the US findings and the diagnosis of SpA

US findings	Multivariate analysis (MA)			MA with “active enthesitis”		
	OR	95% CI	p-value	OR	95% CI	p-value
Thickening	1.28	0.81-2.01	0.3			
Hypoechoic area	1.26	0.81-1.97	0.3			
PD at the enthesitis	8.77	4.40-19.20	<0.001			
Erosions	4.75	2.43-10.1	<0.001	5.22	2.70-11.0	<0.001
“Active enthesitis”				9.20	4.21-23.2	<0.001
<b>Demographics</b>						
Age	0.96	0.95-0.97	<0.001	0.96	0.95-0.98	<0.001
Male sex	3.95	2.75-5.71	<0.001	3.74	2.64-5.33	<0.001

Only the US elementary lesions which were associated with the diagnosis of SpA in the univariate analysis were included in this analysis. **Acronyms.** **CI:** Confidence Interval. **OR:** Odds Ratio. **PD:** Power Doppler. **SpA:** Spondyloarthritis. **US:** Ultrasound.

<b>Table 4.</b> Prevalence of the US elementary lesions of enthesitis and association with the diagnosis of SpA						
<b>Univariate analysis</b>				<b>Multivariate analysis</b>		
	<b>SpA N=413</b>	<b>Controls N=282</b>	<b>p-value<sup>1</sup></b>	<b>OR</b>	<b>95% CI</b>	<b>p-value</b>
<b>Enthesis</b>						
Quadriceps tendon	264 (63.9%)	149 (52.8%)	0.017	1.26	0.86-1.95	0.32
Proximal patellar tendon	168 (40.7%)	85 (30.1%)	0.023	1.23	0.84-1.80	0.30
Distal patellar tendon	186 (45.0%)	94 (33.3%)	0.010	1.34	0.91-1.97	0.14
Achilles tendon	307 (74.3%)	177 (62.8%)	0.006	1.93	1.30-2.88	0.001
Plantar fascia	201 (48.7%)	112 (39.7%)	0.10	-	-	-
<b>Demographics</b>						
Age				0.95	0.94-0.96	<0.001
Male sex				3.83	2.72-5.42	<0.001

<sup>1</sup> Pearson's Chi-squared test adjusted with Bonferroni correction for multiple testing. Percentage refers to the number of patients with  $\geq 1$  US elementary lesion of enthesitis as defined by OMERACT (i.e., enthesal thickening, hypoechoic areas, PD at the enthesis, enthesophytes/calcifications and bone erosions) for each enthesia. **Acronyms.** **CI:** Confidence Interval. **OR:** Odds Ratio. **SpA:** Spondyloarthritis. **US:** Ultrasound.

**Table 5.** Association between ultrasound findings and clinical disease activity indices in SpA patients

<b>BASDAI (axSpA patients)</b>	<b>Univariate analysis</b>			<b>Multivariate analysis (MA)</b>			<b>MA with 'active' enthesitis</b>		
	<i>Beta</i>	<i>95% CI</i>	<i>p-value</i> <sup>1</sup>	<i>Beta</i>	<i>95% CI</i>	<i>p-value</i>	<i>Beta</i>	<i>95% CI</i>	<i>p-value</i>
Thickening	1.60	0.92-2.30	<0.001	0.58	-0.30-1.50	0.2			
Hypochoic area	1.80	1.10-2.50	<0.001	1.20	0.30-2.20	0.009			
PD at the enthesis	1.40	0.60-2.30	0.007	0.57	-0.30-1.50	0.2			
PD outside the enthesis	-0.35	-2.30-1.60	>0.9						
Erosions	0.42	-0.40-1.20	>0.9						
Enthes/Calfic	0.29	-0.50- 1.10	>0.9						
"Active enthesitis"	1.50	0.60-2.40	0.012						
<b>ASDAS (axSpA patients)</b>	<b>Univariate analysis</b>			<b>Multivariate analysis (MA)</b>			<b>MA with 'active' enthesitis</b>		
	<i>Beta</i>	<i>95% CI</i>	<i>p-value</i> <sup>1</sup>	<i>Beta</i>	<i>95% CI</i>	<i>p-value</i>	<i>Beta</i>	<i>95% CI</i>	<i>p-value</i>
Thickening	0.77	0.50-1.10	<0.001	0.33	-0.10-0.80	0.2			
Hypochoic area	0.84	0.50-1.20	<0.001	0.55	0.08-1.0	0.023			
PD at the enthesis	0.63	0.20-1.10	0.030	0.21	-0.20-0.70	0.4			
PD outside the enthesis	0.01	-0.90-0.10	>0.9						
Erosions	0.27	-0.10-0.70	>0.9						
Enthes/Calfic	0.05	-0.40-0.50	>0.9						
"Active enthesitis"	0.62	0.20-1.10	0.042						
<b>DAPSA (PsA patients)</b>	<b>Univariate analysis</b>			<b>Multivariate analysis (MA)</b>			<b>MA with 'active' enthesitis</b>		
	<i>Beta</i>	<i>95% CI</i>	<i>p-value</i> <sup>1</sup>						
Thickening	-2.10	-5.30-1.20	0.2						
Hypochoic area	1.40	-2.00-4.80	0.4						
PD at the enthesis	-2.0	-5.30-1.40	0.3						
PD outside the enthesis	-0.52	-7.50-6.40	0.9						
Erosions	-1.90	-5.70-1.90	0.3						
Enthes/Calfic	3.10	-2.20-8.40	0.3						
"Active enthesitis"	-1.80	-5.40-1.80	0.3						
<b>LEI (SpA patients)</b>	<b>Univariate analysis</b>			<b>Multivariate analysis (MA)</b>			<b>MA with 'active' enthesitis</b>		
	<i>Beta</i>	<i>95% CI</i>	<i>p-value</i> <sup>1</sup>	<i>Beta</i>	<i>95% CI</i>	<i>p-value</i>	<i>Beta</i>	<i>95% CI</i>	<i>p-value</i>
Thickening	0.66	0.40-0.90	<0.001	0.28	-0.0-0.60	0.081			
Hypochoic area	0.73	0.50-1.0	<0.001	0.50	0.20-0.80	0.002			
PD at the enthesis	0.49	0.20-0.80	0.004	0.17	-0.10-0.50	0.3			
PD outside the enthesis	-0.38	-0.90-0.20	>0.9						
Erosions	0.38	0.10-0.60	0.066						
Enthes/Calfic	0.42	0.10-0.70	0.083						
"Active enthesitis"	0.55	0.20-0.90	0.002						

<sup>1</sup>Bonferroni correction for multiple testing. **Acronyms.** ASDAS: Ankylosing Spondylitis Disease Activity Score.

**axSpA:** Axial Spondyloarthritis. **BASDAI:** Bath Ankylosing Spondylitis Disease Activity Index. **CI:** Confidence Interval. **DAPSA:** Disease Activity in Psoriatic Arthritis. **LEI:** Leeds Enthesitis Index. **MA:** Multivariable Analysis.

**PsA:** Psoriatic Arthritis. **SpA:** Spondyloarthritis.

<b>Table 6.</b> Association between US features and presence of US bone erosions, CRP and HAQ in SpA patients									
<b>US bone erosions (SpA patients)</b>	<b>Univariate analysis</b>			<b>Multivariate analysis (MA)</b>			<b>MA with 'active' enthesitis</b>		
	<i>OR</i>	<i>95% CI</i>	<i>p-value</i> <sup>1</sup>	<i>OR</i>	<i>95% CI</i>	<i>p-value</i>	<i>OR</i>	<i>95% CI</i>	<i>p-value</i>
Thickening	4.0	2.40-6.80	<0.001	2.10	1.10-4.20	0.032			
Hypoechoic area	3.59	2.10-6.0	<0.001	1.60	0.80-3.10	0.2			
PD at the enthesitis	3.0	1.90-4.80	<0.001	1.90	1.10-3.20	0.015			
PD outside the enthesitis	0.90	0.30-2.20	>0.9						
Enthes/Calfic	3.10	1.50-7.20	<0.001	1.90	0.80-4.60	0.14	2.70	1.30-6.50	0.063
"Active enthesitis"	4.40	2.70-7.30	<0.001				4.20	2.50-6.90	<0.001
<b>CRP (SpA patients)</b>	<b>Univariate analysis</b>								
	<i>Beta</i>	<i>95% CI</i>	<i>p-value</i> <sup>1</sup>						
Thickening	0.90	-0.10-1.90	0.6						
Hypoechoic area	1.20	0.20-2.20	0.13						
PD at the enthesitis	1.30	0.20-2.50	0.14						
PD outside the enthesitis	-0.70	-3.10-1.80	>0.9						
Erosions	0.30	-0.80-1.50	>0.9						
Enthes/Calfic	-1.20	-2.50-0.10	0.5						
"Active enthesitis"	1.60	0.40-2.80	0.045						
<b>HAQ (SpA patients)</b>	<b>Univariate analysis</b>								
	<i>Beta</i>	<i>95% CI</i>	<i>p-value</i> <sup>1</sup>	<i>Beta</i>	<i>95% CI</i>	<i>p-value</i>	<i>Beta</i>	<i>95% CI</i>	<i>p-value</i>
Thickening	0.10	-0.0-0.20	0.5						
Hypoechoic area	0.20	0.10-0.30	0.021	0.10	0.0-0.20	0.037			
PD at the enthesitis	0.20	0.10-0.30	0.022	0.10	0.0-0.30	0.039			
PD outside the enthesitis	-0.0	-0.30-0.20	>0.9						
Erosions	0.10	-0.10-0.20	>0.9						
Enthes/Calfic	0.10	-0.10-0.20	>0.9						
"Active enthesitis"	0.20	0.10-0.30	0.034				0.20	0.10-0.30	0.005

<sup>1</sup>Bonferroni correction for multiple testing. **Acronyms.** **CI:** Confidence Interval. **CRP:** C-Reactive Protein. **HAQ:** Health Assessment Questionnaire Disability-Index. **MA:** Multivariable Analysis. **OR:** Odds Ratio. **PD:** Power Doppler. **SpA:** Spondyloarthritis. **US:** Ultrasound.

<b>Supplementary Table 1.</b> Ultrasound machines and settings used in the current study.		
<b>US machine</b>	<b>Grey scale frequency</b>	<b>Power Doppler frequency</b>
Siemens Acuson Antares	5-13 MHz	7.1 MHz
General Electric, LOGIQ-S8 R3	15 MHz	7.5 MHz
Esaote MY Lab 70	6-18 MHz	7 MHz
Samsung HS50	3-14 MHz	10 MHz
Esaote My Lab X Pro80	4-15 MHz	7.5 MHz
General Electric, Logiq P9	15-18 MHz	9.1 MHz
Esaote MyLab Twice	3-13 and 6-18 MHz	7.5 and 9.1 MHz
US machine Siemens S200	15 MHz	9 MHz
Siemens AcusonS2000	9-12 MHz	7.5 MHz
Xario 200 canon	18 MHz	6.1 MHz
Esaote MyLab Class C	4-13 and 6-18 MHz	7.1 MHz and 10-12 MHz
General Electric, Logic e	8–18 MHz	7 MHz
Esaote MyLabX5	6-18 MHz	6.3-12.5 MHz

**Acronyms.** MHz: megahertz; US: ultrasound.

<b>Supplementary Table 2. Demographic and clinical characteristics of included controls</b>			
	<b>All n=282</b>	<b>Fibromyalgia n=138</b>	<b>Osteoarthritis n=144</b>
<b>Age, (years [SD])</b>	54.2 (13.9)	47.8 (13.7)	60.4 (10.9)
<b>Female gender (%)</b>	192 (68.1)	115 (83)	77 (53.5)
<b>BMI (IQR)</b>	25.7 (23.5-29.0)	25.2 (23.3-28.1)	26.4 (23.9-29.2)
<b>Physical activity (times/week)</b>	1 (0-3)	1 (0-2)	1 (0-3)
<b>CRP (mg/dl, [SD])</b>	0.5 (0.6)	0.5 (0.5)	0.5 (0.7)
<b>ESR (mm/h, [SD])</b>	15 (13)	13 (13)	17 (13)
<b>Metabolic syndrome (%)</b>	48 (17.0)	12 (8.7)	36 (25.0)
<b>Diabetes (%)</b>	30 (10.6)	9 (6.5)	21 (14.6)
<b>Dyslipidaemia (%)</b>	87 (30.8)	32 (23.2)	55 (38.2)
<b>Hypertension (%)</b>	83 (29.4)	20 (14.5)	63 (43.7)

**Acronyms.** **BMI:** Body Mass Index. **CRP:** C-Reactive Protein. **ESR:** Erythrocyte Sedimentation Rate. **IQR:** interquartile range. **SD:** Standard Deviation.

<b>Supplementary Table 3.</b> Disease Activity Indices in patients with SpA and controls				
	<b>SpA (n=413)</b>			<b>Controls (n=282)</b>
	<b>All (n= 413)</b>	<b>PsA (n= 189)</b>	<b>axSpA (n= 224)</b>	
<b>TJC, median (IQR)</b>	0 (0-2)	1 (0-3)	0 (0-1)	0 (0-1)
<b>TJC, mean (SD)</b>	1.5 (3.3)	2.5 (4.1)	0.8 (2.2)	1.1 (2.1)
<b>SJC, median (IQR)</b>	0 (0-1)	0 (0-2)	0 (0-0)	0 (0-0)
<b>SJC, mean (SD)</b>	0.9 (2.0)	1.5 (2.6)	0.4 (1.1)	0.1 (0.4)
<b>Radiographic axSpA (%)</b>	72 (17.4)	-	72 (32.1)	-
<b>LEI positive (%)</b>	137 (33.2)	61 (33.3)	76 (33.9)	-
<b>DAPSA, median (IQR)</b>	-	12 (6-19)	-	-
<b>ASDAS, median (IQR)</b>	-	-	2.0 (1.2-3.1)	-
<b>BASMI, median (IQR)</b>	-	-	2.0 (1.0-3.4)	-
<b>BASFI, median (IQR)</b>	-	-	2 (0-6)	-
<b>BASDAI, median (IQR)</b>	-	-	2.0 (0.70- 4.8)	-
<b>HAQ, median (IQR)</b>	0.25 (0-0.7)	0.38 (0-0.9)	0.1 (0-0.6)	-
	<b>axSpA, N = 224</b>		<b>PsA, N = 189</b>	
<b>ASDAS</b>				
Remission (%)	76 (33.9)		-	
Moderate (%)	52 (23.2)		-	
High (%)	53 (23.7)		-	
Very high (%)	43 (19.2)		-	
<b>BASDAI</b>				
Remission (%)	128 (57.1)		-	
Moderate (%)	81 (36.1)		-	
High (%)	15 (6.6)		-	
<b>DAPSA</b>				
Remission (%)	-		40 (21.2)	
Low (%)	-		69 (36.5)	
Moderate (%)	-		54 (28.6)	
High (%)	-		26 (13.7)	

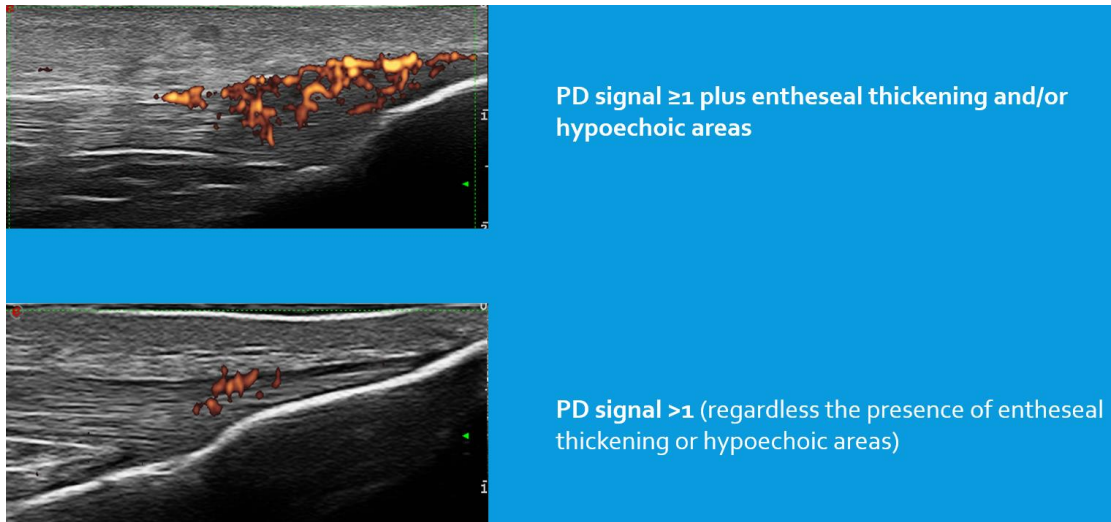


**Acronyms.** **ASDAS:** Ankylosing Spondylitis Disease Activity Score. **axSpA:** Axial Spondyloarthritis. **BASDAI:** Bath Ankylosing Spondylitis Disease Activity Index. **BASFI:** Bath Ankylosing Spondylitis Functional Index. **BASMI:** Bath Ankylosing Spondylitis Metrology Index. **DAPSA:** Disease Activity in Psoriatic Arthritis. **HAQ:** Health Assessment Questionnaire Disability-Index. **LEI:** Leeds Enthesitis Index. **PsA:** Psoriatic Arthritis. **SpA:** Spondyloarthritis. **SJC:** Swollen Joint Count. **TJC:** Tender Joint Count.

<b>Supplementary Table 4. Treatment of SpA patients and controls</b>				
	<b>SpA n= 413</b>		<b>Controls n= 282</b>	
	<b>axSpA n= 224</b>	<b>PsA n= 189</b>	<b>FBM n= 138</b>	<b>OA n= 144</b>
<b>NSAIDs (%)</b>	85 (37.9)	49 (25.9)	27 (19.6)	52 (36.1)
<b>GCs (≥5 mg Prednisolone) (%)</b>	15 (6.7)	40 (21.2)	5 (4.6)	6 (5.5)
<b>cs-DMARDs (%)</b>	61 (27.2)	120 (63.5)	-	-
<b>b-DMARDs (%)</b>	129 (57.6)	91 (48.1)	-	-
TNFi (%)	112 (50.0)	58 (30.7)	-	-
Anti-IL12/23 (%)	1 (0.4)	5 (2.6)	-	-
Anti-IL17 (%)	15 (6.7%)	23 (12.2)	-	-
JAKi (%)	1 (0.4)	1 (0.5)	-	-
Others (apremilast) (%)	0 (0.0)	3 (1.6)	-	-

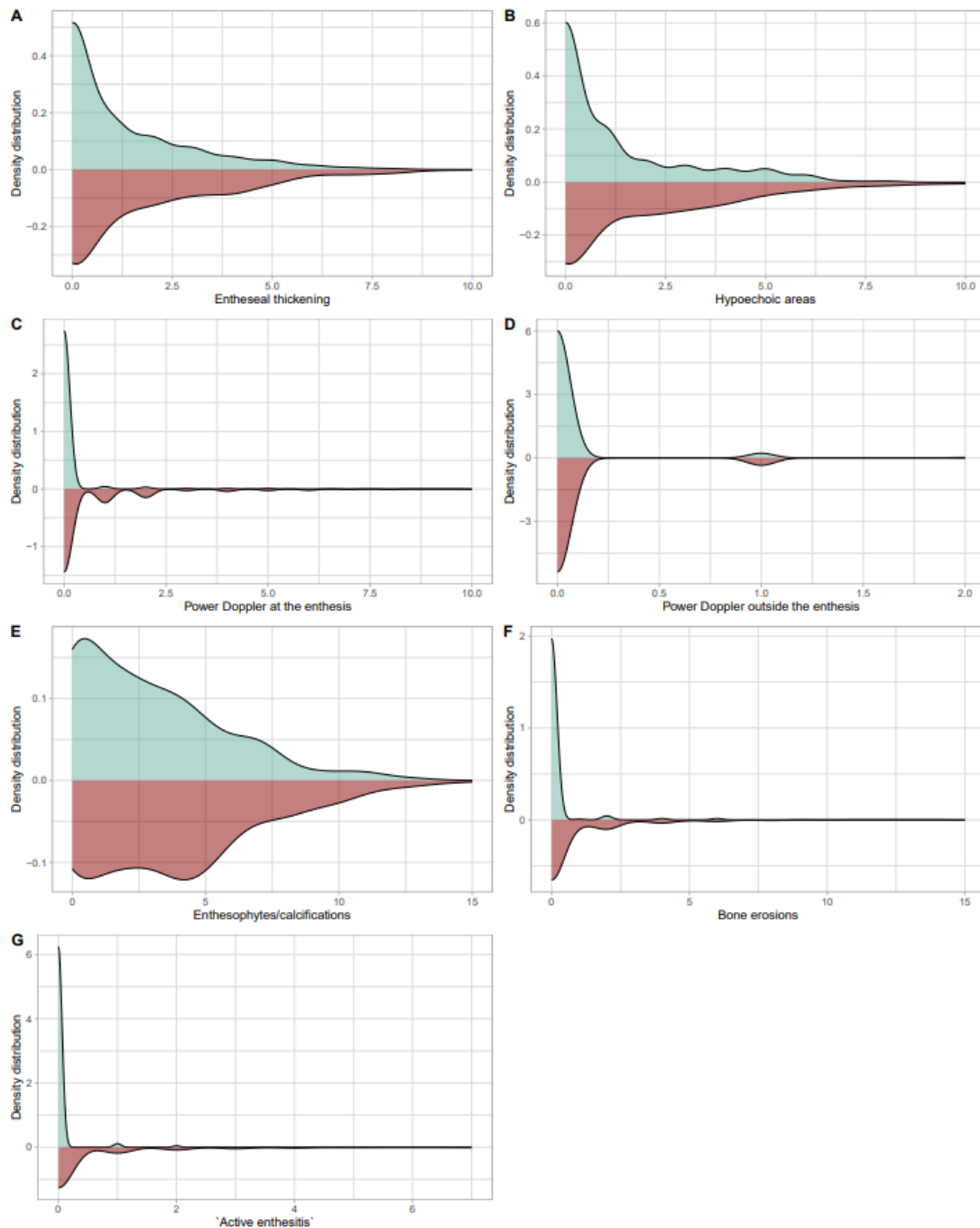
**Acronyms.** **axSpA:** Axial Spondyloarthritis. **bDMARDs:** Biologic disease-modifying antirheumatic drugs. **cs-DMARDs:** Conventional synthetic disease-modifying antirheumatic drugs. **FBM:** Fibromyalgia. **GCs:** Glucocorticoids. **IL:** Interleukin. **JAKi:** Janus Kinase Inhibitor. **NSAIDs:** Nonsteroidal anti-inflammatory drugs. **OA:** Osteoarthritis. **PsA:** Psoriatic Arthritis. **SpA:** Spondyloarthritis. **TNFi:** Tumour Necrosis Factor-α Inhibitor.

**Supplementary Figure 1.** Representative example of 'active enthesitis'.



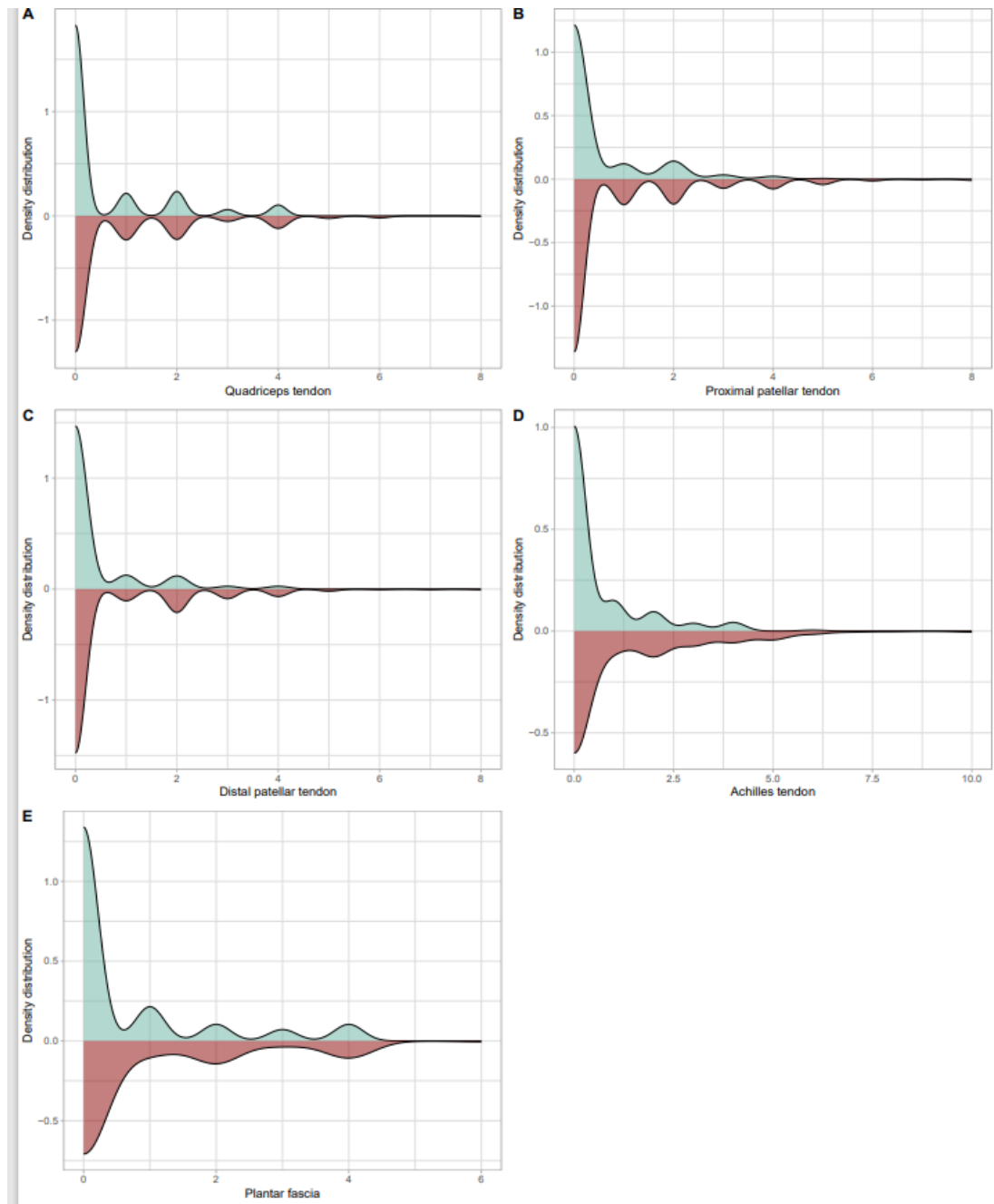
**Acronyms.** PD: power Doppler.

**Supplementary Figure 2.** Density distribution of the sum of the US findings (OMERACT US elementary lesions of enthesitis in SpA and “active enthesitis”) at subject level in SpA patients and controls.



Supplementary Figure 2 shows a statistically significant difference between the distributions of the OMERACT US lesions of enthesitis according to the two-sample Kolmogorov-Smirnov test between SpA patients (red areas) and controls (light green areas). Enteseal thickening ( $D=0.13278$ , adjusted  $p=0.038$ ); Hypochoic areas ( $D=0.19859$ , adjusted  $p<0.0001$ ); Power doppler at the enthesis ( $D=0.23573$ , adjusted  $p<0.0001$ ); Entesophytes/Calcifications ( $D=0.16243$ , adjusted  $p=0.002$ ); Bone erosions ( $D=0.21039$ , adjusted  $p<0.0001$ ). Similar positive results were observed for “active enthesitis” ( $D=0.19067$ , adjusted  $p<0.0001$ ). No statistically significant difference was found between the two distributions for Power doppler outside the enthesis ( $D=0.023947$ , adjusted  $p=1$ ). Multiple comparisons adjustment was performed through Bonferroni correction.

**Supplementary Figure 3.** Density distribution of the sum of the OMERACT US elementary lesions of enthesitis (subject level) divided by single enthesis in SpA patients and controls.



Supplementary Figure 3 shows a statistically significant difference at the Achilles tendon enthesis ( $D=0.17518$ , adjusted  $p=0.0003$ ) regarding the distribution of the OMERACT US lesions of enthesitis between SpA patients (red areas) and controls (light green areas) according to the two-sample Kolmogorov-Smirnov test. No significant difference between cases and controls were observed regarding the distribution of the OMERACT US lesions of enthesitis in the other entheses included in the study (i.e., quadriceps tendon, proximal patellar tendon, distal patellar tendon, plantar fascia). All the analysis were adjusted through Bonferroni correction (data not shown).

## References

1. Benjamin M, Toumi H, Ralphs JR, et al. Where tendons and ligaments meet bone: attachment sites ('entheses') in relation to exercise and/or mechanical load. *J Anat.* 2006;208:471-90.
2. Polachek A, Li S, Chandran V, Gladman DD. Clinical enthesitis in a prospective longitudinal psoriatic arthritis cohort: incidence, prevalence, characteristics, and outcome. *Arthritis Care Res.* 2017;69:1685–91.
3. Kaeley GS, Eder L, Aydin SZ, Gutierrez M, et al. Enthesitis: A hallmark of psoriatic arthritis. *Semin Arthritis Rheum.* 2018;48:35-43.
4. Taylor W, Gladman D, Helliwell P, et al. Classification criteria for psoriatic arthritis: development of new criteria from a large international study. *Arthritis Rheum.* 2006;54:2665–73.
5. Gossec L, Baraliakos X, Kerschbaumer A, et al. EULAR recommendations for the management of psoriatic arthritis with pharmacological therapies: 2019 update. *Ann Rheum Dis.* 2020;79:700–12.
6. Rudwaleit M, Landewé R, van der Heijde D, et al. The development of Assessment of SpondyloArthritis international Society classification criteria for axial spondyloarthritis (part I): classification of paper patients by expert opinion including uncertainty appraisal. *Ann Rheum Dis.* 2009;
7. Rudwaleit M, van der Heijde D, Landewé R, et al. The development of Assessment of SpondyloArthritis international Society classification criteria for axial spondyloarthritis (part II): validation and final selection. *Ann Rheum Dis.* 2009;
8. Macchioni P, Salvarani C, Possemato N, et al. Ultrasonographic and Clinical Assessment of Peripheral Enthesitis in Patients with Psoriatic Arthritis, Psoriasis, and Fibromyalgia Syndrome: The ULISSE Study. *J Rheumatol.* 2019;46:904-911.
9. D'Agostino MA, Terslev L. Imaging Evaluation of the Enteses: Ultrasonography, MRI, and Scoring of Evaluation. *Rheum Dis Clin North Am.* 2016;42:679-693.
10. Kaeley GS. Visualization of enthesitis by ultrasound: a key diagnostic tool in spondyloarthropathy diagnosis and management. *Curr Rheumatol Rep.* 2020;21;22:48;
11. Naredo E, Wakefield RJ, Iagnocco A, et al. The OMERACT ultrasound task force--status and perspectives. *J Rheumatol.* 2011;38:2063-7.
12. Tom S, Zhong Y, Cook R, et al. Development of a Preliminary Ultrasonographic Enthesitis Score in Psoriatic Arthritis - GRAPPA Ultrasound Working Group. *J Rheumatol.* 2019;46:384-390.

13. Terslev L, Naredo E, Iagnocco A, et al. Defining enthesitis in spondyloarthritis by ultrasound: Results of a delphi process and of a reliability reading exercise. *Arthritis Care Res.* 2014;66:741-8.
14. Balint PV, Terslev L, Aegerter P, et al. Reliability of a consensus-based ultrasound definition and scoring for enthesitis in spondyloarthritis and psoriatic arthritis: An OMERACT US initiative. *Ann Rheum Dis.* 2018;77:1730-1735.
15. Gouze H, Backhaus M, Balint P, et al. Ultrasound in the Management of Patients With Psoriatic Arthritis: Systematic Literature Review and Novel Algorithms for Pragmatic Use. *J Rheumatol.* 2023;15:jrheum.2023-0091.
16. Guldberg-Møller J, Terslev L, Nielsen SM, et al. Ultrasound pathology of the entheses in an age and gender stratified sample of healthy adult subjects: a prospective cross-sectional frequency study. *Clin Exp Rheumatol* 2019;37:408–13.
17. Bakirci S, Solmaz D, Stephenson W, et al. Enteseal changes in response to age, body mass index, and physical activity: an ultrasound study in healthy people. *J Rheumatol* 2020;47:968–72.
18. Di Matteo A, Filippucci E, Cipolletta E, et al. How normal is the enthesis by ultrasound in healthy subjects? *Clin Exp Rheumatol* 2020;38:472–8.
19. Falsetti P, Conticini E, Baldi C, et al. High prevalence of ultrasound-defined enthesitis in patients with metabolic syndrome. Comment on: how normal is the enthesis by ultrasound in healthy subjects? di Matteo et al. *Clin Exp Rheumatol* 2021;39:435–6.
20. Fiorenza A, Bonitta G, Gerratana E, et al. Assessment of enthesis in patients with psoriatic arthritis and fibromyalgia using clinical examination and ultrasound. *Clin Exp Rheumatol.* 2020 Jan-Feb;38 Suppl(1):31-39.
21. Filippucci E, Smerilli G, Di Matteo A, et al. Ultrasound definition of enthesitis in spondyloarthritis and psoriatic arthritis: arrival or starting point? *Ann Rheum Dis.* 2021;80:1373-1375.
22. Di Matteo A, Filippucci E, Cipolletta E, et al. Reply to: High prevalence of ultrasound-defined enthesitis in patients with metabolic syndrome. *Clin Exp Rheumatol.* 2021;39:437.
23. Michelena X, López-Medina C, Marzo-Ortega H. Non-radiographic versus radiographic axSpA: what's in a name? *Rheumatology (Oxford).* 2020;1;59(Suppl4):iv18-iv24.
24. Altman R, Alarcon G, Appelrouth D, et al. The American College of Rheumatology criteria for the classification and reporting of osteoarthritis of the hand. *Arthritis Rheum* 1990;33:160110.

25. Altman R, Asch E, Bloch D, et al. Development of criteria for the classification and reporting of osteoarthritis. Classification of osteoarthritis of the knee. Diagnostic and Therapeutic Criteria Committee of the American Rheumatism Association. *Arthritis Rheum*. 1986;29:1039-49.
26. Wolfe F, Clauw DK, Fitzcharles MA, et al. Fibromyalgia criteria and severity scales for clinical and epidemiological studies: a modification of the ACR preliminary diagnostic criteria for fibromyalgia. *J Rheumatol* 2011; 38: 1113-22.
27. Wolfe F, Clauw DJ, Fitzcharles MA, et al. 2016 Revisions to the 2010/2011 fibromyalgia diagnostic criteria. *Semin Arthritis Rheum* 2016; 46: 319-29.
28. Cooksey R, Choy E. Exploring gender differences, medical history, and treatments used in patients with fibromyalgia in the UK using primary-care data: a retrospective, population-based, cohort study. *The Lancet Rheumatology*. Volume 4, Supplement 1. 2022, S20.
29. Di Matteo A, Filippucci E, Cipolletta E, et al. Enteseal involvement in patients with systemic lupus erythematosus: an ultrasound study. *Rheumatology (Oxford)*. 2018;1;57(10):1822-1829.
30. Healy PJ, Helliwell PS. Measuring clinical enthesitis in psoriatic arthritis: Assessment of existing measures and development of an instrument specific to psoriatic arthritis. *Arthritis Rheum*. 2008;59(5):686–91.
31. Lukas C, Landewé R, Sieper J, et al. Development of an ASAS-endorsed disease activity score (ASDAS) in patients with ankylosing spondylitis. *Ann Rheum Dis* 2009;68:18-24.
32. Machado P, Landewé R, Lie E, et al. Ankylosing Spondylitis Disease Activity Score (ASDAS): defining cut-off values for disease activity states and improvement scores. *Ann Rheum Dis* 2011;70:47-53.
33. Gossec L, Portier A, Landewé R, et al. Preliminary definitions of “flare” in axial spondyloarthritis, based on pain, BASDAI and ASDAS-CRP: an ASAS initiative. *Ann Rheum Dis*. 2016;75:991–6.
34. Zochling J. Measures of symptoms and disease status in ankylosing spondylitis: Ankylosing Spondylitis Disease Activity Score (ASDAS), Ankylosing Spondylitis Quality of Life Scale (ASQoL), Bath Ankylosing Spondylitis Disease Activity Index (BASDAI), Bath Ankylosing Sp. *Arthritis Care Res*. 2011;63:S47-58.
35. Calin A, Garrett S, Whitelock H, Kennedy LG, O’Hea J, Mallorie P, et al. A new approach to defining functional ability in ankylosing spondylitis: the development of the Bath Ankylosing Spondylitis Functional Index. *J Rheumatol*. 1994;21:2281–5.



36. Calin A, Garrett S, Whitelock H, et al. A new approach to defining functional ability in ankylosing spondylitis: the development of the Bath Ankylosing Spondylitis Functional Index. *J Rheumatol*. 1994;21:2281–2285.
37. Fries JF, Spitz P, Kraines G, et al. Measurement of Patient Outcome in Arthritis. *Arthritis and Rheumatism*. 1980;23:137-145.
38. Möller I, Janta I, Backhaus M, et al. The 2017 EULAR standardised procedures for ultrasound imaging in rheumatology. *Ann Rheum Dis*. 2017;76:1974-1979.
39. de Miguel E, Cobo T, Munoz-Fernandez S et al. Validity of enthesis ultrasound assessment in spondyloarthritis. *Ann Rheum Dis* 2009;68:169–74.
40. Kiris A, Kaya A, Ozgocmen S et al. Assessment of enthesitis in ankylosing spondylitis by power Doppler ultrasonography. *Skeletal Radiol* 2006;35:522–8.
41. Freeston JE, Coates LC, Helliwell PS et al. Is there subclinical enthesitis in early psoriatic arthritis? A clinical comparison with power Doppler ultrasound. *Arthritis Care Res (Hoboken)* 2012;64:1617–21.
42. Bruyn GA, Iagnocco A, Naredo E et al.; OMERACT Ultrasound Working Group. OMERACT definitions for ultrasonographic pathologies and elementary lesions of rheumatic disorders 15 years on. *J Rheumatol* 2019;46: 1388–93
43. Di Matteo A, Cipolletta E, Destro Castaniti GM, et al. Reliability assessment of the definition of ultrasound enthesitis in SpA: results of a large, multicentre, international, web-based study. *Rheumatology (Oxford)*. 2022;28;61:4863-4874.
44. Abate M, Salini V, Antinolfi P, et al. Ultrasound morphology of the Achilles in asymptomatic patients with and without diabetes. *Foot Ankle Int*. 2014;35:44-9.
45. Zabotti A, Bandinelli F, Batticciotto A et al.; Musculoskeletal Ultrasound Study Group of the Italian Society of Rheumatology. Musculoskeletal ultrasonography for psoriatic arthritis and psoriasis patients: a systematic literature review. *Rheumatology (Oxford)* 2017;56:1518–32.
46. Molina Collada J, Macía-Villa C, Plasencia C, et al. Doppler enthesitis: a potential useful outcome in the assessment of axial spondyloarthritis and psoriatic arthritis. *Clin Rheumatol*. 2021;40:2013-2020.
47. D'Agostino MA, Carron P, Gaillez C, et al. Effects of secukinumab on synovitis and enthesitis in patients with psoriatic arthritis: 52-week clinical and ultrasound results from the randomised, double-blind ULTIMATE trial with open label extension. *Semin Arthritis Rheum*. 2023; 19;63:152259.
48. Zabotti A, Piga M, Canzoni M et al.; UPSTREAM study group. Ultrasonography in psoriatic arthritis: which sites should we scan? *Ann Rheum Dis* 2018;77:1537–8.

49. Naredo E, Batlle-Gualda E, García-Vivar ML, et al; Ultrasound Group of the Spanish Society of Rheumatology. Power Doppler ultrasonography assessment of entheses in spondyloarthropathies: response to therapy of enthesal abnormalities. *J Rheumatol.* 2010;37:2110-7.
50. Molina Collada J, Macía-Villa C, Plasencia-Rodríguez C, et al. Ultrasound Doppler enthesitis shows sensitivity to change after biological therapy in spondyloarthritis and psoriatic arthritis patients. *Scand J Rheumatol.* 2022;51:196-204. .
51. Pukšić S, Bolton-King P, Sexton J, et al. DAPSA and ultrasound show different perspectives of psoriatic arthritis disease activity: results from a 12-month longitudinal observational study in patients starting treatment with biological disease-modifying antirheumatic drugs. *RMD Open.* 2018;5;4:e000765.
52. Smerilli G, Cipolletta E, Di Matteo A, et al. 'Double target' ultrasound monitoring of biologic therapy in psoriatic arthritis. *Clin Exp Rheumatol* 2023 (article accepted).
53. Polachek A, Cook R, Chandran V, et al. The association between sonographic enthesitis and radiographic damage in psoriatic arthritis. *Arthritis Res Ther.* 2017;19:189.
54. Smerilli G, Cipolletta E, Destro Castaniti GM, et al. Doppler Signal and Bone Erosions at the Enthesis Are Independently Associated With Ultrasound Joint Erosive Damage in Psoriatic Arthritis. *J Rheumatol.* 2023;50:70-75.