

Special Article

How to Manage Endometriosis in Adolescence: The Endometriosis Treatment Italian Club Approach

Lucia Lazzeri, MD, Karin Louise Andersson, MD, Stefano Angioni, MD, Alessandro Arena, MD, Saverio Arena, Ludovica Bartiromo, MD, Nicola Berlanda, MD, Cecilia Bonin, MD, Massimo Candiani, MD, Gabriele Centini, MD, Simona Del Forno, MD, Agnese Donati, MD, Caterina Exacoustos, MD, Eliana Fuggetta, MD, Luca Labanca, MD, Antonio Maiorana, MD, Francesco Maneschi, MD, Francesco Giuseppe Martire, MD, Ludovico Muzii, MD, Jessica Ottolina, MD, Alessio Perandini, MD, Federica Perelli, MD, Ida Pino, MD, Maria Grazia Porpora, MD, Valentino Remorgida, MD, Sara Scaramuzzino, MD, Matteo Schimberni, MD, Renato Seracchioli, MD, Eugenio Solima, MD, Michele Vignali, MD, Errico Zupi, MD, and Alberto Mattei, MD

From the Department of Territory Health (Dr. Andersson, Exacoustos), Azienda Sanitaria Toscana Centro, Florence, Italy, Department of Surgical Sciences (Dr. Angioni), Università di Cagliari, Cittadella Universitaria, Cagliari, Italy, Department of Medical and Surgical Sciences (Drs. A. Arena, Del Forno, and Seracchioli), DIMEC, Sant'Orsola Hospital, Università di Bologna, Bologna, Italy, Department of Obstetrics and Gynecology (Arena), Santa Maria della Misericordia hospital, Perugia, Italy, Department of Obstetrics and Gynecology (Drs. Bartiromo, Candiani, Ottolina, and Schimberni), IRCCS San Raffaele Scientific Institute, Milan, Italy, Department of Obstetrics and Gynecology (Drs. Berlanda and Donati), Fondazione IRCCS Ca' Granda Ospedale Maggiore Policlinico, Università degli Studi di Milano, Milan, Italy, Azienda Ospedaliera Universitaria Integrata (Drs. Bonin and Perandini), Università di Verona, Piazzale A. Stefani 1, Verona, Italy, Department of Molecular and Developmental Medicine (Drs. Lazzeri, Centini, Martire, and Zupi), Università di Siena, Siena, Italy, Department of Surgical Sciences, Gynecologic Unit (Drs. Exacoustos, and Martire), University of Rome "Tor Vergata" Rome, Italy, Department of Obstetrics and Gynecology (Drs. Fuggetta and Maneschi), San Giovanni Addolorata Hospital (Drs. Labanca and Martire), Roma, Italy, Department of Surgical Sciences (Drs. Labanca), Valdarno Hospital, Azienda Toscana Sud Est, Italy, Department of Obstetrics and Gynecology (Dr. Maiorana), ARNAS Ospedale Civico Piazza Nicola, Palermo, Italy, Division of Gynecology and Obstetrics (Drs. Mattei and Perelli), Santa Maria Annunziata Hospital, USL Toscana Centro, Florence, Italy, Department of Maternal and Child Health and Urology (Drs. Muzii, Porpora, and Scaramuzzino), Università di Roma La Sapienza, Policlinico Umberto I, Rome, Italy, Preventive Gynecology Unit (Dr. Pino), European Institute of Oncology IRCCS, Milan, Italy, Unit of Obstetrics and Gynecology (Dr. Remorgida), University of Eastern Piedmont, Novara, Italy, Division of Gynecology and Human Reproduction Physiopatology (Dr. Seracchioli), IRCCS, Azienda Ospedaliera Universitaria di Bologna, Bologna, Italy, and Department of Obstetrics and Gynecology (Drs. Solima and Vignali), Macedonio Melloni Hospital, Milan, Italy

ABSTRACT The evaluation of endometriosis in an adolescent girl is a challenging topic. The initial stage of the disease and the limited diagnostic instrument appropriate for the youth age and for its typical features can reduce the ability of the gynecologist. At the same time, missing a prompt diagnosis can delay the beginning of specific and punctual management of endometriosis, which could avoid a postponed diagnosis from 6 to 12 years, typical of adolescent girls complaining of dysmenorrhea. This article aimed to answer all the potential questions around the diagnosis and management of endometriosis in adolescents starting from a clinical case looking at the possible solution that is easily reproducible in the clinical practice. *Journal of Minimally Invasive Gynecology* (2023) 00, 1–11. © 2023 Published by Elsevier Inc. on behalf of AAGL.

Keywords: Adolescence; Diagnosis; Management; Painful symptoms

The authors declare that they have no conflict of interest.
The authors declare no previous presentation or publication.
Corresponding author: Errico Zupi, MD, Department of Molecular and Developmental Medicine, Obstetrics and Gynecologic Clinic, University of Siena, viale Bracci, 53100 Siena, Italy.
E-mail: ezupi@libero.it

Submitted February 7, 2023, Revised March 23, 2023, Accepted for publication March 24, 2023.

Available at www.sciencedirect.com and www.jmig.org

1553-4650/\$ — see front matter © 2023 Published by Elsevier Inc. on behalf of AAGL.

<https://doi.org/10.1016/j.jmig.2023.03.017>

Endometriosis affects approximately 10% of adult women worldwide. It is the leading cause of chronic pelvic pain (CPP) and is often associated with infertility. Unfortunately, the real prevalence of endometriosis in adolescent girls is currently unknown owing to diagnostic problems. Painful symptoms are often underestimated in the adolescents. Despite its impact on quality of life, the delay in endometriosis diagnosis is well known. It is commonly diagnosed later in life, often

after several years. The diagnosis of endometriosis in young adolescent girls is particularly problematic and can be misunderstood even by the most meticulous gynecologist specialist. Starting with the following clinical case, we discussed the possible management, easily reproducible, in an adolescent girl with a clinical suspicion of endometriosis.

A 14-year-old girl was referred to a gynecologic consultation for dysmenorrhea. She is virgin and she had her first period at the age of 12 years. She experiences dysmenorrhea at grade 8 of 10 on the 10-point visual analog scale (VAS), ovulatory pain (VAS 7), and localized and deep abdominal tenderness (VAS 7). Regarding her menses, she has a normal menstrual bleeding, while she reports period of constipation and diarrhea. Clinical evaluation revealed no systemic disease and no previous surgery; her mother is taking a progesterone therapy for referred endometrioma and deeply infiltrative endometriosis in the rectovaginal space evaluated with noninvasive imaging. At physical examination, the gynecologist found acne on her back and the abdominal examination revealed mild tenderness in the low pelvic area. Her body mass index is 24.9 kg/m² (height, 159 cm; weight, 63 kg). During her menstrual period, she often takes nonsteroidal anti-inflammatory drugs (ketoprofen) and she often misses days of school for dysmenorrhea. Trying to find a possible explanation for her symptoms, her general practitioner ordered a transabdominal ultrasound where the radiologist highlighted a 38-mm cyst on the left ovary with ultrasound features suggestive of an endometrioma.

This article aimed to answer all the potential questions around the diagnosis and management of endometriosis in the adolescence age and also debated the recommendations of European Society of Human Reproduction and Embryology (ESHRE) guidelines 2022 [1] and used the Grading of Recommendations Assessment, Development, and Evaluation (GRADE) scoring system.

Clinical Approach to the Adolescent Patient

Diagnostic delay especially affects adolescent patients and initial evaluation is crucial.

The first assessment for all patients reporting of dysmenorrhea or pelvic pain includes medical, gynecologic, menstrual, family, and psychosocial history.

It is important to determine whether the patient has primary dysmenorrhea or additional symptoms suggestive of secondary dysmenorrhea, given that endometriosis represents the main cause of secondary dysmenorrhea in adolescents. According to ESHRE guidelines, suggestive manifestations for endometriosis include early menarche, severe dysmenorrhea, dyspareunia, abnormal uterine bleeding (heavy or irregular bleeding), midcycle or acyclic pain, resistance to empiric medical treatment (painkillers and hormonal therapy), and gastrointestinal and genitourinary symptoms (GRADE 1, strong recommendation).

Furthermore, clinicians have to investigate patient's absenteeism from school or from extracurricular activities

owing to pain symptoms with VAS [2], family history of endometriosis, presence of obstructive müllerian anomalies, and childhood sexual or physical abuse [3,4] (GRADE 2, weak recommendation).

Physical Examination

Physical examination includes bimanual vaginal examination and inspection of vagina and cervix (rectal examination in presexually active patients). Palpation of adnexal masses and thickening or retraction of uterosacral ligaments (USLs) and nodules in the rectovaginal septum may reveal endometriosis. According to ESHRE guideline, this procedure should be discussed with the adolescents and her caregiver (Good Practice Point [GPP]) because it is also useful to rule out other causes of secondary dysmenorrhea and pelvic pain [5].

Reasons for diagnostic delay in adolescents with endometriosis may be caused by normalization of menstrual pain, fear of stigmatization regarding a gynecologic complaint, and minimization of symptoms reported by patients by medical professionals [6]. A recent study showed that a social context that stigmatizes and dismisses menstrual health, inequitable gender norms, and a lack of endometriosis knowledge really affect adolescents' perception of symptoms and ability of asking for help [7].

Educating not only clinicians but also patients regarding the nature of adolescent pathologic pelvic pain is mandatory to promote correct approach to this group of patients [8]. Parental modeling influences perception of pain and anxiety in young patients, and this process also influences how they report their symptoms [9]. Zannoni et al [10] suggest practical rules to early diagnose endometriosis in adolescents: never underestimate the pain, consider endometriosis as possible diagnosis, obtain an accurate history before performing clinical evaluations, treat the pain, and plan frequent follow-up visits to re-evaluate the patient.

Psychologic Impact of Pain in Adolescence

"I think I was about 14 years old when I had the symptoms. Yeah, lots and lots of pain and I couldn't move. There was always constant pain. I didn't have a day without pain. I used to have days off because of it. I just sat there and could not move, and I cried."

These are the words of a patient who was interviewed in the study conducted by Moradi et al [11] in 2014, which aimed to explore feelings linked to the presence of endometriosis in 3 groups of patients of different ages (16–24 years, 25–34 years, 35 years and older).

With respect to ESHRE guidelines, we underline that endometriosis has an important physical and psychologic impact in patients of all ages; however, adolescents represent a more delicate category, in which the pain typical of the disease and the suffering linked to it intertwine in the storm of emotions that characterizes adolescence. In their study, Moradi et al [11] showed that affected teenagers experience a worsening of the quality of life, especially in

the psychologic, physical, relationship, and sexual/couple life fields. Young patients with endometriosis often must lessen physical activity and they are forced to spend a lot of time in bed, resting, with feelings of helplessness. Furthermore, considering the social role attributed to sports, it is not uncommon for them to feel out of the group and alone [11]. Although it is less important in adolescence than in adulthood, another important concern is relationship life. It is precisely during adolescence, in fact, that first approaches in the sexual field take place. The fear of feeling pain during intercourses represents a cause for frustration to these girls and sometimes it can be the cause of broken relationship [11,12]. Education is an important issue that should not be underestimated in affected teenagers. Zannoni et al [13] conducted a survey among adolescents, showing a significant association between severe dysmenorrhea and absenteeism from school, with the possibility of poor academic performance. These factors are responsible for the development of feelings of depression, low self-esteem, hopeless, frustration, disappointment, fear, anger, and exhaustion [7,11]. Moreover, addressing these issues represents a challenge because they often remain silent for feelings of shame, as if it is normal for a teenager to experience during menses [7], or, on the contrary, owing to poor support from family members and doctors, even gynecologists, who do not have adequate knowledge of this disease. It is important to take proper care of these patients, reassuring them, always giving elements of hope, and offering them, if possible, psychologic support. At the same time, it is necessary to quickly obtain a correct diagnosis to administer adequate therapy to control the symptoms.

Pathogenesis of Endometriosis in Adolescence

Over the years, many researchers tried to find a possible explanation for the pathogenesis of endometriosis; coelomic metaplasia, embryonic müllerian rests, iatrogenic implantation, vascular and lymphatic metastasis, the genetic theory, and endometrial stem/progenitor cells represent different hypotheses besides Sampson theory, the classic retrograde menstruation, which is the most widely accepted theory to explain the ectopic implantation of endometrium [14]. In this context, adolescent and premenarcheal endometriosis seem to be able to originate from different mechanisms with respect to the adult form, which is mostly linked with menstrual regurgitation. Documenting cases of endometriosis in premenarcheal girls and not being able to link it to retrograde menstruation theory, some authors tried to explain its pathogenesis with coelomic metaplasia or with embryonic müllerian rests stimulated by ovarian steroids at menarche, an event marked by thelarche [15,16]. The existence of neonatal uterine bleeding (NUB) in women have stimulated studies of Brosens et al [17] regarding the pathogenesis of early-onset endometriosis. Vaginal bleeding in neonate can present in 3% to 5% of cases on days 3 to 5 of life, as found in the neonatal autopsy study of

Ober and Bernstein (1955), where only 5% of cases were characterized by secretory and decidual changes in endometrium, linked to placental endocrine stimulus. NUB could be described as a consequence of withdrawal of placental progesterone, an event similar to the menstrual cycle [18]. The characteristic length of uterine cervix in neonates, between 2 and 2.5 times that of the corpus, and its thick mucus seem to cause functional obstruction and retrograde outflow of endometrial cells, explaining the possible discrepancy between NUB and the amount of real endometrial sheddings in the peritoneal cavity, and the presence of much earlier onset and more severe stages of endometriosis in girls with obstructive müllerian anomalies [19]. Adolescent endometriosis could arise from the shedding of endometrial stem/progenitor cells into the peritoneal cavity during the early neonatal period; these types of cells seem to survive for many years in the absence of hormonal stimulus; then under the action of estrogen, whose secretion precedes menarche, they develop through vascular endothelial growth factor stimulation of angiogenesis, causing the formation of premature florid hemorrhagic lesions and endometrioma [20]. However, despite the presence of epidemiologic and histologic studies that supports this pathogenetic relationships, conclusive evidence on the specific pathogenesis of adolescent endometriosis, which could differentiate it from the adult form, is still missing.

Painful Symptoms and Differential Diagnosis

On the basis of pathophysiology, dysmenorrhea is classified as primary dysmenorrhea (menstrual pain without organic disease) or secondary dysmenorrhea (menstrual pain associated with underlying pelvic pathology) [21]. Adolescent patients who report dysmenorrhea should be evaluated for gynecologic and not gynecologic reasons of CPP (GRADE 1, strong recommendation). Nongynecologic origin of CPP is represented by gastrointestinal disease, urinary tract disease, musculoskeletal syndromes, visceral hyperalgesia, neurologic problems, and psychiatric comorbidity whereas CPP owing to gynecologic origin include endometriosis, adenomyosis, fibroids, postoperative adherence syndrome, pelvic inflammatory disease, ovarian mass, hematocolpos owing to obstructive müllerian anomalies, vulvodynia, and hydrosalpinx. It is also important to exclude an eventual pregnancy as cause of the symptoms [22].

A multidisciplinary diagnostic approach should be considered for a complete evaluation of these patients as a coexistence of more than one of the conditions mentioned earlier [23]. Adolescent patients affected by dysmenorrhea should be submitted to an accurate anamnesis paying attention to every aspect of the menstruation period such as age at menarche, period characteristic in terms of duration of bleeding, intervals between menses, and assessment of menstrual flow (GRADE 1, strong recommendation). It is important to register information about associated

symptoms, such as pain, nausea, diarrhea, and fatigue, that includes timing of onset, severity of pain, and effects on daily activities [5]. Questionnaires may be helpful to identify adolescents at risk of developing endometriosis [10]. A wide laboratory evaluation can be done, including complete blood count with differential, C reactive protein, metabolic panel, urinalysis with urine culture, urine or blood test for human chorionic gonadotropin, and testing for sexually transmitted infections [24]. Physical examination should include abdominal and pelvic examination, even if a bimanual pelvic evaluation is not always tolerated for adolescents who are not sexually active [3].

Imaging

Ultrasonographic evaluation: transabdominal rather than transvaginal ultrasound (TVS) should be ordered in nonsexually active adolescents. A transrectal approach may be considered in adolescents with an intact hymen, given that it is essentially atraumatic if performed carefully (GRADE 1, strong recommendation).

Three-dimensional ultrasound can be considered as the gold standard to detect obstructive and nonobstructive müllerian anomalies (GRADE 1, strong recommendation).

Magnetic resonance can be useful to detect obstructive reproductive tract anomalies and to identify and characterize endometriotic lesions that are difficult to locate by ultrasound (GRADE 1, strong recommendation).

Computed tomography should be reserved for urgent evaluation given concerns about radiation exposure (GRADE 2, weak recommendation).

Differential Diagnosis with Gastrointestinal Pathologies

The incidence and prevalence of deep infiltrating endometriosis (DIE) in adolescence is not known but it is probably not common [25]. Bowel complaints in adolescents with endometriosis range from 2% to 46% [26], less frequent than in adults [27]. We know that in adult women with endometriosis, irritable bowel syndrome (IBS), a chronic condition of the large intestine caused by visceral hypersensitivity, is 5 times more frequent than the general population [28]. Standard endometriosis therapy and specific IBS dietary measures, such as the low fermentable oligosaccharides, disaccharides, monosaccharides and polyols diet [29], are known to improve bowel complaints. Unfortunately, we do not have data for the adolescents: it is likely that mild symptoms may be correlated to IBS as well, whereas very severe bowel symptoms might point to severe bowel endometriosis.

When an adolescent complains of bowel symptoms, the physician must also take into consideration several organic gastrointestinal pathologies. Nearly 20% of inflammatory bowel diseases are diagnosed in children and adolescents [30], often with more severe presentations including puberty and growth delay, weight loss, bloody diarrhea (the most common presentation of ulcerative colitis), and, in one-

quarter of patients, extraintestinal symptoms (i.e., arthralgia, aphthous ulcers, erythema nodosum). Fecal calprotectin is a useful screening tool [31], but all children with suspicion of inflammatory bowel diseases should undergo a complete endoscopic evaluation, including ileocolonoscopy and upper gastrointestinal endoscopy with multiple biopsies for diagnosis. Imaging is also required for possible involvement of small or proximal large intestine in Crohn disease [32]. Celiac disease prevalence in childhood and adolescence is 1% to 3% of the general European and US population [33], >40% presenting with features other than the classic gastroenterologic ones (chronic diarrhea and undigested food in the stool), for example, hypothyroidism, diabetes, chronic anemia, and delayed menarche [34]. Diagnosis requires the presence of duodenal villous atrophy. Most patients have circulating antibodies against tissue transglutaminase; human leukocyte antigen typing is useful as a rule-out test [35]. In children, European guidelines allow a diagnosis without a duodenal biopsy provided that strict symptomatic and serologic criteria are met [36]. Less frequent causes of intestinal symptoms in adolescents are Meckel diverticulum [37] or subacute/chronic appendicitis [38].

Differential Diagnosis: Müllerian Anomalies

Congenital uterine anomalies may lead to symptoms that often overlap with the clinical manifestations of endometriosis, such as CPP, dysmenorrhea, and prolonged or abnormal bleeding at the time of menarche.

The true incidence of reproductive tract anomalies is estimated to affect approximately 5.5% of women [39].

Such anatomic problems result in outflow tract obstruction with pain or nonobstructive outflow tract without pain. They present across a spectrum, ranging from abnormality of the hymen to an abnormality of the uterus [40,41]. Congenital uterine anomalies that obstruct or partially obstruct the flow of menses include noncommunicating functioning uterine horn, uterine duplication with an obstructed hemivagina, uterine septum with an obstructed hemivagina, and imperforate hymen [5,41]. Nonobstructive anomalies include Mayer-Rokitansky-Küster-Hauser syndrome (uterovaginal agenesis) and müllerian-renal-cervical syndrome (uterovaginal agenesis, renal agenesis or ectopy, vertebral anomalies) [40].

Nonobstructive morphologic variations in anatomy of the uterus and vagina are commonly asymptomatic. They are not associated with abnormalities of the external genitalia and therefore are typically not diagnosed during routine physical examination. When these anomalies do cause symptoms, they may be minor causing difficulty with menstrual hygiene or more significant such as primary amenorrhea and dyspareunia [40].

Obstructive defects can present with primary amenorrhea and with progressively worsening episodes of pelvic pain. On initial imaging, a mass caused by the obstruction is often noted. Obstructive defects are generally diagnosed several years after menarche; owing to the fact that there is

a menstrual flow and because dysmenorrhea is fairly common in teenagers, this combination of symptoms often leads to a diagnostic delay.

Given that CPP, dysmenorrhea, dyspareunia, and reproductive disorders are common symptoms of endometriosis, a differential diagnosis is strongly needed. Moreover, an association between obstructed müllerian anomalies and the development of endometriosis has been reported in 40% of cases. According to Sampson's theory [42], pelvic distortion and obstructive müllerian anomalies may favor large amount of retrograde menstruations that may increase the severity of endometriosis.

Pelvic examination is the first step in the evaluation of a symptomatic adolescent, but it may be challenging in a young girl. First, it is important to rule out obstructive outflow tract anomalies by inspection of external genitalia. In nonobstructive anomalies, pelvic examination shows normal external genitalia and a normal hymen. If a genital exam is tolerated, no vaginal opening is discovered. Pelvic ultrasound is usually the first line in diagnostic testing when evaluating for an obstructive or a nonobstructive müllerian anomaly (GRADE 1, strong recommendation). The use of magnetic resonance imaging (MRI) has become the gold standard as a tool in accurately outlining uterine presence, size, and anatomy and other associated anomalies (kidneys, spinal cord) [5,43] (GRADE 1, strong recommendation).

Differential Diagnosis: Recurrent Infections

A dysbiotic gut or genital microbiota is associated with multiple gynecologic conditions, with mounting data supporting an association between the microbiome and endometriosis and infertility. These microbiomes likely play a role in the gut-brain axis, which further supports a putative association with the spectrum of symptoms associated with endometriosis, including infertility and CPP [44].

Endometriosis seems to be associated with elevated levels of Proteobacteria, Enterobacteriaceae, Streptococcus, and *Escherichia coli* across various microbiome site [45].

Laboratory and clinical studies demonstrate that there are indeed differences in the microbiome composition of hosts with and without endometriosis.

Therefore, a laboratory evaluation can be done, including complete blood count with differential, C reactive protein, metabolic panel, urinalysis with urine culture, and testing for sexually transmitted infections.

Differential Diagnosis: Adenomyosis

Adenomyosis is known to be a common disorder of the uterus, and it is linked with a spectrum of symptoms and clinical signs, such as heavy menstrual bleeding, dyspareunia, dysmenorrhea, pelvic pain, and infertility [46].

Adenomyosis is characterized by the presence of ectopic endometrial epithelial cells and stromal fibroblasts in the myometrium, in which they lead to hyperplasia and hypertrophy of smooth muscle cells surrounding them. Several

hypotheses on the pathogenesis of adenomyosis were made in earlier days, including invasion of the endometrium into the myometrium, stem cell metaplasia in the myometrium, retrograde menstruation in which endometrial cells penetrate into the myometrium through the serosa, and others [47].

The prevalence of adenomyosis among women represents an issue frequently discussed among gynecologists: the prevalence based on hysterectomy samples reports ranges between 14% and 57% [46].

Other studies suggest that adenomyosis affects clinically 20% of women, but is more common among perimenopausal and multiparous women, whereas fewer cases of adenomyosis in adolescents and prepubescent girls have been observed [48]. According to a recent study [49], adenomyosis is not only a pathology of adult life but involves young patients mostly in a mild to moderate form with potential clinical implications. The diagnosis is feasible through a noninvasive way with ultrasound and a proper management can be set. Adenomyosis may reveal itself in diffuse or focal forms, such as myometrial cysts or adenomyomas. In evaluating a symptomatic adolescent girl, although it may be a rare condition, it is mandatory to exclude or to confirm the diagnosis of adenomyosis [48].

Considering the possible coexistence of pelvic endometriosis and adenomyosis [50], the clinical steps to the diagnosis may be the same: an abdominal and pelvic examination, in which we can find an enlarged uterus and tenderness, and transvaginal (in sexually active patients) or transrectal ultrasound evaluation with a 3-dimensional probe and volume contrast imaging, which are preferable compared with the transabdominal approach, especially in differential diagnosis with uterine fibroids (GRADE 1, strong recommendation), whereas MRI and computed tomography could be intended for those cases where the ultrasonography cannot be performed or in doubtful cases, always after ultrasounds [51].

There are numerous ultrasonographic features that have been linked to adenomyosis: an irregular or interrupted junctional zone, myometrial "cysts," subendometrial lines or "buds" presence of fan shaped shadowing, uterine wall asymmetry, an increased myometrial vascularity, and an enlarged uterus [51]—all these characteristics are suggestive but not conclusive for the diagnosis of adenomyosis.

Concerning therapy, we must consider that, in adolescents, the main goal is preserving fertility. The right therapeutic approach, whether pharmacologic or surgical, must evaluate the severity of the symptoms, the feasibility of a hormonal therapy, and the possible coexistence of pelvic endometriosis.

Role of Imaging to Suspect Endometriosis in Adolescence

Transabdominal Ultrasound

The first step in the diagnostic process investigating a pubertal patient who is suspected of having endometriosis is the ultrasonographic approach. However, most of these

teenagers are presexually active, and this point is an important limitation to transvaginal method. In these cases, the transabdominal or transrectal examinations were suggested.

Ultrasound examination is commonly performed in the lower abdominal wall using a well-filled but not overdistended urinary bladder as a sonographic window. To optimally distend the bladder, fluids might be administered intravenously. Alternatively, the bladder might be catheterized and filled retrogradely via gravity with sterile saline. These 2 methods could speed up the evaluation times, particularly helpful in an emergency such as an access in the emergency department for an acute pelvic pain. Care should be taken not to overdistend the bladder because overdistention can displace the ovaries from the field of view and distort the uterine contour [52]. The study is usually obtained with a 3.5-MHz probe.

The value of the transabdominal imaging is limited. Many studies have shown that the efficacy of this method on detecting different localization of endometriosis is limited, except for the endometriotic cysts [53]: the abdominal ultrasound is able to diagnose ovarian endometriotic cysts or endometriomas but is not useful for nonovarian endometriotic lesions [54]. In particular, the diagnosis of superficial endometriosis, which is one of the most common localizations in the adolescent patient, is a very difficult goal to reach with this diagnostic method [4]. Hence, it is important to stress the concept that a normal pelvic ultrasound does not exclude a diagnosis of endometriosis [5]. When the clinical aspect leads the clinician to suspect a posterior involvement, transvaginal (if the patient has achieved a sexual activity) or transrectal ultrasound may be more helpful in identifying deep endometriotic nodules or adherent ovaries, especially if performed by an experienced operator [10].

TVS and Transrectal Approach

Considering the features of adolescent population and the need of noninvasive instrument in the diagnosis and in the management of endometriosis, we can understand the importance of an appropriate method for the evaluation of the disease in adolescent girls. In literature, TVS is considered the first-line imaging technique in the assessment of different types of endometriotic lesions, such as superficial and deep peritoneal endometriosis and ovarian endometriosis [55] (GRADE 1, strong recommendation). The use of TVS can often be impossible in adolescent girls for their virginity or vaginal pathology as hypoplasia or agenesis, but transrectal sonography can be considered an optimal alternative. The use of MRI if the patients or their parents are opposed or unconvinced to this approach (GPP) was recommended. With the patient in left lateral decubitus or supine position, we can insert the transvaginal probe into the rectum and advance until the midline image of the uterine cervix is visualized on the longitudinal plane. Moving the transducer along its longitudinal axis and rotating it in different planes, we can

evaluate the uterus, parametria, vagina, bladder, and rectum [56]. Transrectal sonography (TVR) technique allowed to obtain clearer and more defined images of the pelvic anatomy with respect to transabdominal sonography and to MRI, as evaluated by confrontation with anatomic situation observed during surgeries [56]. TVR has been studied for the evaluation of rectovaginal endometriosis and more in general of the posterolateral parametria. For the first time, Ohba et al [57] used transrectal ultrasonography for the assessment of endometriosis in USLs, and they found a correlation between thickened, irregular nodules in USL, tenderness in the paracervical region on rectal examination, and presence of endometriotic lesions on USL confirmed during laparoscopy. Comparing transrectal detection of rectovaginal endometriosis and histologic findings of women subjected to surgery for suspected endometriosis, they found a 97% of sensitivity and 96% of specificity of TVR in the diagnosis of rectovaginal endometriosis, but also a perfect precision in the evaluation of deep endometriotic infiltration of USL [56]. With the aim of studying the endometriosis gastrointestinal involvement, Koga et al [58] compared characteristic images of rectosigmoid endometriosis obtained by TVR with histologic findings, and they underlined the benefit of this technique in the diagnosis and management of rectosigmoid DIE.

Considering literature and clinical experience, transrectal ultrasound can be considered a safe, useful, specific, and sensible tool for the evaluation and management of adolescent girls with endometriosis [59,60].

Role of MRI in Adolescence Endometriosis

Nowadays, the diagnosis of endometriosis has a diagnostic delay of 6 to 7 years [61]. This delay is prolonged in adolescent patients with endometriosis, because dysmenorrhea is very common in teenagers and, at the same time, the gynecologic examination and ultrasound evaluation may be difficult. In consideration of these limitations, MRI is a non-invasive tool that can be very useful to detect the disease and its manifestations, given that it is a nonoperator-dependent technique.

However, MRI is a second-level examination, and it cannot be indicated as first choice to evaluate the disease (GRADE 1, strong recommendation). There is still no consensus about the indications to perform an MRI.

Even if ultrasound is the best technique that can be used to study endometriomas, MRI allows to distinguish between superficial implants and endometriotic cysts and can provide additional information in the case of atypical lesions to exclude elements of malignancy [62]. It may be useful in the study of DIE [63]. In fact, MRI shows high accuracy in detecting anterior and posterior endometriosis and anterior locations can be evaluated with the use of urographic sequences [64]. The European Society of Urogenital Radiology developed a standard protocol for the use of MRI to study endometriosis [63], which defines the possible use of both 1.5T (Tesla) and 3T magnet and remarks the necessity

of the administration of antiperistaltic agent before the patient examination.

Normally, at MRI, imaging features of endometriomas are high signal intensity at T1-weighted and T2-weighted sequences, which persists in fat-suppressed T1-weighted images [65]. Moreover, the study of the ovaries cannot be separated from the evaluation of the fallopian tubes, especially in young patients with a desire of pregnancy in the future. Endometriomas can be associated with the presence of hematosalpinx, a dilated tube with hemorrhagic content, that appears in MRI as an hyperintensive image on T1-weighted sequences [66,67].

T2 nonfat-saturated sequences are required to evaluate the anatomic characteristics of endometriosis and to detect fibrotic component of endometriotic implants, whereas T1 fat-saturated sequences are necessary to identify the bloody foci that characterize active lesions. The characteristics of imaging features of endometriotic lesions in MRI include a low signal intensity in the T1- and T2-weighted sequences for fibromuscular component, hyperintensity on T2-weighted sequences for the glandular component, and alterations in T1-weighted sequences for the chronic bleeding.

Fat suppression is necessary for differential diagnosis with teratomas, which are very common in young patients [68]. Furthermore, the chronic bleeding that characterizes endometriomas may create an image of “shading” (a variation in T2-weighted sequences), which is very helpful to rule out hemorrhagic cysts where shading is not present [69,70]. When all these features are present, the sensitivity and specificity of the diagnosis using MRI are 90% and 98%, respectively [68]. Finally, in the case of atypical lesions, the use of intravenous contrast is mandatory to exclude malignant cysts.

In the presence of intestinal and urinary symptoms in adolescence, MRI represents an opportunity to study the anterior and posterior compartment. The most severe forms of deep endometriosis are located in the intestinal and urinary tracts [71,72]. Normally, these lesions show a marked hypointense signal in T2-weighted images, owing to the presence of the fibrotic tissue.

Finally, it would not be correct to exclude the presence of adenomyosis in adolescents with CPP and dysmenorrhea. In fact, although adenomyosis is normally described in older women, some authors reported its presence even in teenagers [73].

The diagnostic criteria for adenomyosis include uniformity of the junctional zone, thickness of the junctional zone >12 mm, and focal areas in the myometrium that are not well demarcated on T2-weighted images [74].

Medical Treatment in an Adolescent Patient

The goals of medical therapy in the adolescent patient include symptomatic relief, suppression of disease progression, and protection of future fertility [5]. The patient and her family should be involved and adequately counseled in

the choice of the therapy according to the need of contraception, contraindications to hormones, and potential adverse effects of different medications. Dysmenorrhea in adolescents is commonly treated empirically with nonsteroidal anti-inflammatory drugs and/or combined oral contraceptive pill, and both primary and secondary dysmenorrhea could respond to this therapy (GPP). No evidence is shown between different nonsteroidal anti-inflammatory drugs and combined oral contraceptive pills [75]. Continuous rather than cyclical oral, vaginal, or estrogenic patch therapy is preferred to achieve an adequate atrophy and decidualization of the endometriotic lesions. If there is no symptom relief after 4 months of continuative empiric therapy, a surgical approach could be suggested [75].

ESRHE guidelines advise clinicians treating women with endometriosis to prescribe hormonal contraceptives or progestins to reduce endometriosis-associated pain (GRADE 1, strong recommendation). However, among the plethora of hormonal contraceptives available today, there is a lack of clear data on which specific preparation should be used according to the type of endometriosis and age of the woman being treated, to achieve targeted therapy.

Progestins suppress the pituitary-ovarian axis, causing anovulation, pseudodecidualization, and atrophy of the eutopic and ectopic endometria. They also modulate the immune response by reducing inflammation. Progestin-only therapy includes different formulations [76]:

- Oral: dienogest 2 mg/day [68] and norethindrone acetate 15 mg/die [77], both effective and well tolerated in adolescents; in particular, dienogest is effective for the treatment of endometriosis, reducing the dimension of endometriotic foci and their vascularization and decreasing endometriosis-related CPP combining several beneficial effects of the 19-norprogesterone and progesterone derivative classes, including high specificity for the progesterone receptor and negligible binding affinities for estrogen, androgen, glucocorticoid, and mineralocorticoid receptors. In addition, it has progestogenic and antiestrogenic effects on both eutopic and ectopic endometria [78].
- Subcutaneous implant of etonogestrel, used successfully but with limited experience in adolescents [79].
- Intrauterine device: levonorgestrel-releasing intrauterine system could be a valid option in older and sexually active adolescents, especially if it is inserted during a laparoscopy for endometriosis as long-term maintenance [80].

Oral administration is to be preferred to long-term one, to stop therapy if side effects arise: weight gain, bloating, depression, and irregular bleeding. However, the real limit of progestins use in adolescents seems related to a possible reduction of bone mineral density, partially reversible after

their suspension, which may interfere with the peak of bone mineralization [76].

The use of gonadotropin hormone-releasing hormone agonists is acceptable in adolescents only if the patient with known endometriosis is refractory to other medical therapies or surgical treatments (GRADE 2, weak recommendation). Their effectiveness is caused by the suppression of the hypothalamic-pituitary axis, which results in a hypoeutrogenic environment. The side effects include hot flashes, headaches, sleeping difficulties, mood swings, depression, and vaginal dryness. Therefore, an add-back therapy, typically norethisterone acetate (5 mg/d) or tibolone (2.5 mg/d), vitamin D, and calcium, along with appropriate monitoring of bone mineral density is mandatory [81]. The use of gonadotropin hormone-releasing hormone agonists for girls younger than 16 years is generally discouraged owing to their permanent effects on bone density. Because of its androgenic and potentially irreversible side effects, danazol has very limited utility for endometriosis treatment, especially in young patients [76].

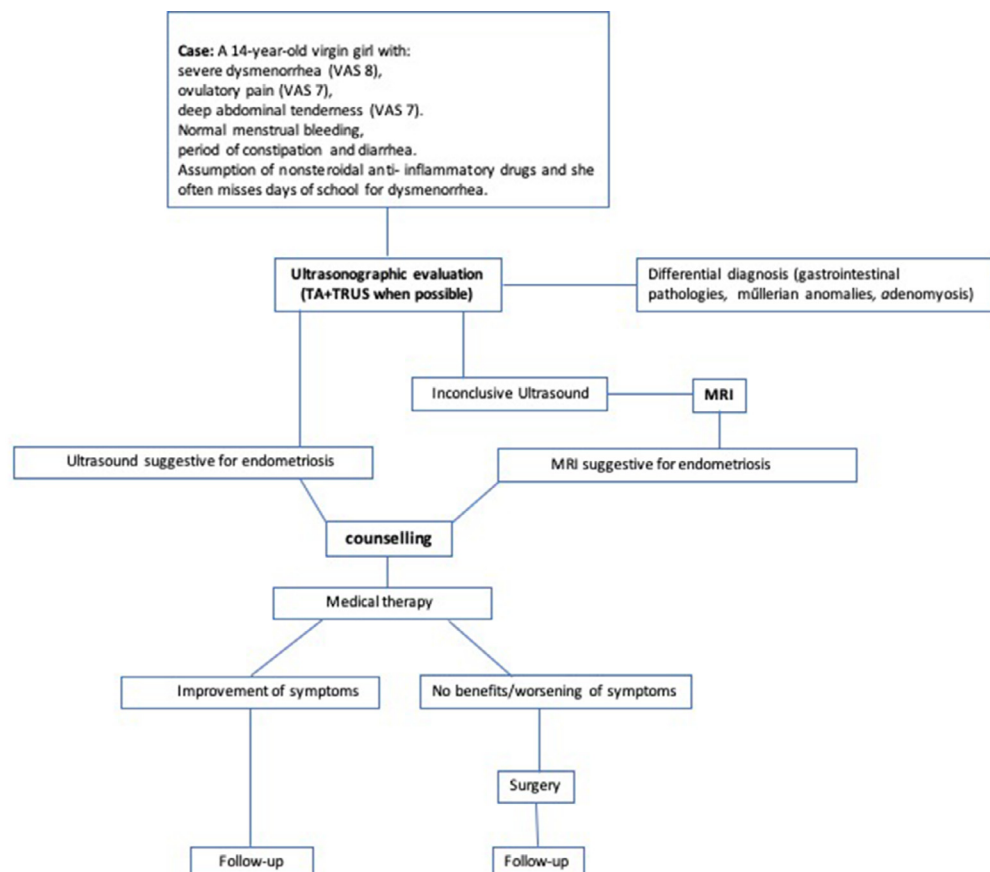
There is not a single best treatment for endometriosis in adolescents: therapy must be tailored to the patient to achieve a good quality of life.

Is There a Place for Surgical Treatment?

The surgical removal of an endometrioma in an adolescent girl should be considered in the case of progressive enlargement of the ovarian cyst or persistence of pain symptoms despite hormonal treatment or in case an ovarian malignancy cannot be ruled out at ultrasonographic evaluation or MRI (GRADE 2, weak recommendation). The goal of surgery should be to remove all the visible disease to restore normal anatomy [5]. In the treatment of the ovarian cyst, it is of paramount importance to adopt all surgical strategies for the preservation of ovarian reserve. In case the stripping technique is used, the correct cleavage plane between the cyst and the ovary must be correctly identified to minimize bleeding and to preserve as much ovarian tissue as possible. When necessary, hemostasis must be achieved by very selective pinpoint cauterization of bleeding vessels or by means of re-approximation of ovarian edges by atraumatic sutures not involving the ovarian hilus. Alternatively, the vaporization of the cystic capsule by means of a carbon dioxide laser has been recently proposed to minimize ovarian damage [82]. It is important to be aware that endometriotic implants in adolescent girls may

Fig. 1

Proposed decisional algorithm to be used in adolescent patients with suspected endometriosis. MRI = magnetic resonance imaging; VAS = visual analog scale.



frequently present as shiny peritoneal vesicles, the so-called clear lesions. The lack of surgical identification of these lesions in young women can result in delayed diagnosis and treatment, with worsening of life quality [83,84]. However, the use of radical excisional surgery for superficial endometriosis may increase extensive adhesive formation, and it should not be used in the adolescent population [85] (GPP).

Surgery for endometriosis in adolescents may be as effective for treating pelvic pain as in the adult population [86]. On the contrary, an increased rate of recurrent disease 5 years after surgery has been reported in young women compared with the adult population. The authors hypothesized that the higher rate of recurrence for early-onset endometriosis may be caused by higher levels of plasmatic estrogens or a more aggressive nature of the disease. However, no predictive factors for endometriosis recurrence could be identified [87]. Accordingly, it has been observed that postoperative recurrence of ovarian cysts and pain symptoms is as high as 40% to 50% at 5-year follow-up in young women without hormonal therapy [88]. Because repeated ovarian surgeries can be harmful on ovarian reserve and hormonal therapy can prevent endometrioma recurrence, all adolescents should undergo medical treatment after surgery until they have completed child bearing [5].

In women with severe symptoms, particularly those with ultrasound sign of DIE, nerve-sparing and vascular sparing surgical approach could be useful to restore the anatomy and to improve the quality of life [89], whereas in adolescent patients offering surgery owing to CPP to provide a histologic disease diagnosis is no longer considered appropriate. According to recent studies [90,91], in young women the endometriotic lesions are often small; in particular, isolated disease findings, mostly small USL thickening, mild adenomyosis, and small endometriomas, are common features of endometriosis associated with severe dysmenorrhea in young patients. Therefore, surgery should only be performed in clinically necessary cases, such as in young patients who are not responding to medical therapy.

Conclusion

Endometriosis in adolescent patients is a challenging problem presenting clinical and pathologic differences compared with premenopausal women. The delay in diagnosis should cause a worsening of the disease inducing chronicity of the painful symptoms. This article aimed to propose the possible clinical approach for endometriotic adolescent patients (Fig. 1).

Awareness among adolescents, parents, and their health-care providers about endometriosis represents a crucial point to facilitate a proper treatment and appropriate clinical follow-up. Medical therapy is the first choice for symptomatic endometriosis in adolescent population, considering the surgical approach only for selected cases or for patients unresponsive to medical treatment. Probably, the early diagnosis and the use of adequate medical therapies should result in less extensive surgery in the adult life.

References

1. Becker CM, Bokor A, Heikinheimo O, et al. ESHRE guideline: endometriosis. *Human Reprod Open*. 2022;2022:hoac009.
2. Jensen MP, Karoly P, Braver S. The measurement of clinical pain intensity: a comparison of six methods. *Pain*. 1986;27:117–126.
3. Laufer MR, Sanfilippo J, Rose G. Adolescent endometriosis: diagnosis and treatment approaches. *J Pediatr Adolesc Gynecol*. 2003;16(3):S3–S11. Suppl.
4. Dun EC, Kho KA, Morozov VV, Kearney S, Zurawin JL, Nezhat CH. Endometriosis in adolescents. *JSLs*. 2015;19. e2015.00019.
5. ACOG Committee Opinion No. 760: dysmenorrhea and endometriosis in the adolescent. *Obstet Gynecol*. 2018;132:e249–e258.
6. Culley L, Law C, Hudson N, et al. The social and psychological impact of endometriosis on women's lives: a critical narrative review. *Hum Reprod Update*. 2013;19:625–639.
7. Gupta J, Cardoso LF, Harris CS, et al. How do adolescent girls and boys perceive symptoms suggestive of endometriosis among their peers? Findings from focus group discussions in New York City. *BMJ Open*. 2018;8:e020657.
8. Seear K. The etiquette of endometriosis: stigmatisation, menstrual concealment and the diagnostic delay. *Soc Sci Med*. 2009;69:1220–1227.
9. Boerner KE, Chambers CT, McGrath PJ, LoLordo V, Uher R. The effect of parental modeling on child pain responses: the role of parent and child sex. *J Pain*. 2017;18:702–715.
10. Zannoni L, Del Forno SD, Paradisi R, Seracchioli R. Endometriosis in adolescence: practical rules for an earlier diagnosis. *Pediatr Ann*. 2016;45:e332–e335.
11. Moradi M, Parker M, Sneddon A, Lopez V, Ellwood D. Impact of endometriosis on women's lives: a qualitative study. *BMC Womens Health*. 2014;14:123.
12. Gallagher JS, DiVasta AD, Vitonis AF, Sarda V, Laufer MR, Missmer SA. The impact of endometriosis on quality of life in adolescents. *J Adolesc Health*. 2018;63:766–772.
13. Zannoni L, Giorgi M, Spagnolo E, Montanari G, Villa G, Seracchioli R. Dysmenorrhea, absenteeism from school, and symptoms suspicious for endometriosis in adolescents. *J Pediatr Adolesc Gynecol*. 2014;27:258–265.
14. Brosens I, Puttemans P, Benagiano G. Endometriosis: a life cycle approach? *Am J Obstet Gynecol*. 2013;209:307–316.
15. Marsh EE, Laufer MR. Endometriosis in premenarcheal girls who do not have an associated obstructive anomaly. *Fertil Steril*. 2005;83:758–760.
16. Batt RE, Mitwally MFM. Endometriosis from thelarche to midteens: pathogenesis and prognosis, prevention and pedagogy. *J Pediatr Adolesc Gynecol*. 2003;16:337–347.
17. Ober WB, Bernstein J. Observations on the endometrium and ovary in the newborn. *Pediatrics*. 1955;16:445–460.
18. Brosens I, Brosens J, Benagiano G. Neonatal uterine bleeding as antecedent of pelvic endometriosis. *Hum Reprod*. 2013;28:2893–2897.
19. Brosens I, Benagiano G. Is neonatal uterine bleeding involved in the pathogenesis of endometriosis as a source of stem cells? *Fertil Steril*. 2013;100:622–623.
20. Gargett CE, Schwab KE, Brosens JJ, Puttemans P, Benagiano G, Brosens I. Potential role of endometrial stem/progenitor cells in the pathogenesis of early-onset endometriosis. *Mol Hum Reprod*. 2014;20:591–598.
21. Proctor M, Farquhar C. Diagnosis and management of dysmenorrhoea. *BMJ*. 2006;332:1134–1138.
22. Powell J. The approach to chronic pelvic pain in the adolescent. *Obstet Gynecol Clin North Am*. 2014;41:343–355.
23. Jarrell JF, Vilos GA, Allaire C, et al. No. 164-consensus guidelines for the management of chronic pelvic pain. *J Obstet Gynaecol Can*. 2018;40:e747–e787.
24. Smorgick N, As-Sanie S. Pelvic pain in adolescents. *Semin Reprod Med*. 2018;36:116–122.

25. Smorgick N, As-Sanie S, Marsh CA, Smith YR, Quint EH. Advanced stage endometriosis in adolescents and young women. *J Pediatr Adolesc Gynecol.* 2014;27:320–323.
26. de Sanctis V, Matalliotakis M, Soliman AT, Elsefy H, Di Maio S, Fiscina B. A focus on the distinctions and current evidence of endometriosis in adolescents. *Best Pract Res Clin Obstet Gynaecol.* 2018;51:138–150.
27. Divasta AD, Vitonis AF, Laufer MR, Missmer SA. Spectrum of symptoms in women diagnosed with endometriosis during adolescence vs adulthood. *Am J Obstet Gynecol.* 2018;218. 324.e1–324.e11.
28. Schomacker ML, Hansen KE, Ramlau-Hansen CH, Forman A. Is endometriosis associated with irritable bowel syndrome? A cross-sectional study. *Eur J Obstet Gynecol Reprod Biol.* 2018;231:65–69.
29. Moore JS, Gibson PR, Perry RE, Burgell RE. Endometriosis in patients with irritable bowel syndrome: specific symptomatic and demographic profile, and response to the low FODMAP diet. *Aust N Z J Obstet Gynaecol.* 2017;57:201–205.
30. El-Matary W, Deora V, Grover K. Barriers to clinical research in children with inflammatory bowel disease: the patients' perspective. *PLOS ONE.* 2018;13:e0206965.
31. van Rheenen PF, Van de Vijver E, Fidler V. Faecal calprotectin for screening of patients with suspected inflammatory bowel disease: diagnostic meta-analysis. *BMJ.* 2010;341:c3369.
32. Keller J, Bassotti G, Clarke J, et al. Expert consensus document: advances in the diagnosis and classification of gastric and intestinal motility disorders. *Nat Rev Gastroenterol Hepatol.* 2018;15:291–308. <https://doi.org/10.1038/nrgastro.2018.7>.
33. Liu E, Dong F, Baròn AE, et al. High incidence of celiac disease in a long-term study of adolescents with susceptibility genotypes. *Gastroenterology.* 2017;152:1329–1336. e1.
34. Sharma M, Singh P, Agnihotri A, et al. Celiac disease: a disease with varied manifestations in adults and adolescents. *J Dig Dis.* 2013;14:518–525.
35. Hujoel IA, Reilly NR, Rubio-Tapia A. Celiac disease: clinical features and diagnosis. *Gastroenterol Clin North Am.* 2019;48:19–37.
36. Lebowhl B, Sanders DS, Green PHR. Coeliac disease. *Lancet.* 2018;391:70–81.
37. Hansen CC, Søreide K. Systematic review of epidemiology, presentation, and management of Meckel's diverticulum in the 21st century. *Med (Baltim).* 2018;97:e12154.
38. Kim K, Choi JS, Choi E, et al. Effects of community-based health worker interventions to improve chronic disease management and care among vulnerable populations: a systematic review. *Am J Public Health.* 2016;106:e3–e28.
39. Skinner B, Quint EH. Nonobstructive reproductive tract anomalies: a review of surgical management. *J Minim Invasive Gynecol.* 2017;24:909–914.
40. Dietrich JE, Millar DM, Quint EH. Non-obstructive Müllerian anomalies. *J Pediatr Adolesc Gynecol.* 2014;27:386–395.
41. Dietrich JE, Millar DM, Quint EH. Obstructive reproductive tract anomalies. *J Pediatr Adolesc Gynecol.* 2014;27:396–402.
42. Sampson JA. Peritoneal endometriosis due to the menstrual dissemination of endometrial tissue into the peritoneal cavity. *Am J Obstet Gynecol.* 1927;14:422–469.
43. Breech LL, Laufer MR. Müllerian anomalies. *Obstet Gynecol Clin North Am.* 2009;36:47–68.
44. Salliss ME, Farland LV, Mahner ND, Herbst-Kralovetz MM. The role of gut and genital microbiota and the estrobolome in endometriosis, infertility and chronic pelvic pain. *Hum Reprod Update.* 2021;28:92–131.
45. Leonardi M, Hicks C, El-Assaad F, El-Omar E, Condous G. Endometriosis and the microbiome: a systematic review. *BJOG.* 2020;127:239–249.
46. Vercellini P, Viganò P, Somigliana E, Daguati R, Abbiati A, Fedele L. Adenomyosis: epidemiological factors. *Best Pract Res Clin Obstet Gynaecol.* 2006;20:465–477.
47. Zhai J, Vannuccini S, Petraglia F, Giudice LC. Adenomyosis: mechanisms and pathogenesis", LC. *Semin Reprod Med.* 2020;38:129–143.
48. Dietrich JE. An update on adenomyosis in the adolescent. *Curr Opin Obstet Gynecol.* 2010;22:388–392.
49. Exacoustos C, Lazzeri L, Martire FG, et al. Ultrasound findings of adenomyosis in adolescents: type and grade of the disease. *J Minim Invasive Gynecol.* 2022;29:291–299. e1.
50. Alborzi S, Askary E, Khorami F, et al. A Detailed Study in Adenomyosis and Endometriosis: Evaluation of the Rate of Coexistence between uterine Adenomyosis and DIE According to Imaging and Histopathology Findings"., HR. *Reprod Sci.* 2021;28:2387–2397.
51. Van den Bosch T, Van Schoubroeck D. Ultrasound diagnosis of endometriosis and adenomyosis: state of the art. *Best Pract Res Clin Obstet Gynaecol.* 2018;51:16–24.
52. Garel L, Dubois J, Grignon A, Filiatrault D, Van Vliet G. US of the pediatric female pelvis: a clinical perspective. *Radiographics.* 2001;21:1393–1407.
53. Back SJ, Maya CL, Zewdneh D, Epelman M. Emergent ultrasound evaluation of the pediatric female pelvis. *Pediatr Radiol.* 2017;47:1134–1143.
54. Eskenazi B, Warner M, Bonsignore L, Olive D, Samuels S, Vercellini P. Validation study of nonsurgical diagnosis of endometriosis. *Fertil Steril.* 2001;76:929–935.
55. Piketty M, Chopin N, Dousset B, et al. Preoperative work-up for patients with deeply infiltrating endometriosis: transvaginal ultrasonography must definitely be the first-line imaging examination. *Hum Reprod.* 2009;24:602–607.
56. Fedele L, Portuese A, Bianchi S, Zanonato G, Raffaelli R. Transrectal ultrasonography in the assessment of congenital vaginal canalization defects. *Hum Reprod.* 1999;14:359–362.
57. Ohba T, Mizutani H, Maeda T, Matsuura K, Okamura H. Evaluation of endometriosis in uterosacral ligaments by transrectal ultrasonography. *Hum Reprod.* 1996;11:2014–2017.
58. Koga K, Osuga Y, Yano T, et al. Characteristic images of deeply infiltrating rectosigmoid endometriosis on transvaginal and transrectal ultrasonography. *Hum Reprod.* 2003;18:1328–1333.
59. Alborzi S, Rasekhi A, Shomali Z, et al. Diagnostic accuracy of magnetic resonance imaging, transvaginal, and transrectal ultrasonography in deep infiltrating endometriosis. *Med (Baltim).* 2018;97:e9536.
60. Martire FG, Lazzeri L, Conway F, et al. Adolescence and endometriosis: symptoms, ultrasound signs and early diagnosis. *Fertil Steril.* 2020;114:1049–1057.
61. Ragab A, Shams M, Badawy A, Alsammani MA. Prevalence of endometriosis among adolescent school girls with severe dysmenorrhea: a cross sectional prospective study. *Int J Health Sci (Qassim).* 2015;9:273–281.
62. Kinkel K, Lu Y, Mehdizade A, Pelte MF, Hricak H. Indeterminate ovarian mass at US: incremental value of second imaging test for characterization—meta-analysis and Bayesian analysis. *Radiology.* 2005;236:85–94.
63. Bazot M, Bharwani N, Huchon C, et al. European society of urogenital radiology (ESUR) guidelines: MR imaging of pelvic endometriosis. *Eur Radiol.* 2017;27:2765–2775.
64. Kinkel K, Frei KA, Balleyguier C, Chapron C. Diagnosis of endometriosis with imaging: a review. *Eur Radiol.* 2006;16:285–298.
65. Sugimura K, Okizuka H, Imaoka I, et al. Pelvic endometriosis: detection and diagnosis with chemical shift MR imaging. *Radiology.* 1993;188:435–438.
66. Kim MY, Rha SE, Oh SN, et al. MR Imaging findings of hydrosalpinx: a comprehensive review. *RadioGraphics.* 2009;29:495–507.
67. Kaproth-Joslin K, Dogra V. Imaging of female infertility: a pictorial guide to the hysterosalpingography, ultrasonography, and magnetic resonance imaging findings of the congenital and acquired causes of female infertility. *Radiol Clin North Am.* 2013;51:967–981.
68. Yamashita Y, Torashima M, Hatanaka Y, et al. Value of phase-shift gradient-echo MR imaging in the differentiation of pelvic lesions with high signal intensity at T1-weighted imaging. *Radiology.* 1994;191:759–764.

69. Togashi K, Nishimura K, Kimura I, et al. Endometrial cysts: diagnosis with MR imaging. *Radiology*. 1991;180:73–78.
70. Woodward PJ, Sohaey R, Mezzetti TPJ. Endometriosis: radiologic-pathologic correlation. *Radiographics*. 2001;21:193–216.
71. Krüger K, Gilly L, Niedobitek-Kreuter G, Mpinou L, Ebert AD. Bladder endometriosis: characterization by magnetic resonance imaging and the value of documenting ureteral involvement. *Eur J Obstet Gynecol Reprod Biol*. 2014;176:39–43.
72. Medeiros LR, Rosa MI, Silva BR, et al. Accuracy of magnetic resonance in deeply infiltrating endometriosis: a systematic review and meta-analysis. *Arch Gynecol Obstet*. 2015;291:611–621.
73. Itam SP, Ayensu-Coker L, Sanchez J, Zurawin RK, Dietrich JE. Adenomyosis in the adolescent population: a case report and review of the literature. *J Pediatr Adolesc Gynecol*. 2009;22:e146–e147.
74. Exacoustos C, Manganaro L, Zupi E. Imaging for the evaluation of endometriosis and adenomyosis. *Best Pract Res Clin Obstet Gynaecol*. 2014;28:655–681.
75. Saridoğan E. Adolescent endometriosis. *Eur J Obstet Gynecol Reprod Biol*. 2017;209:46–49.
76. Dessolet M, Melis GB, Angioni S. Endometriosis in adolescence. *Obstet Gynecol Int*. 2012;2012:869191.
77. Sauvan M, Chabbert-Buffet N, Geoffron S, Legendre G, Wattier JM, Fernandez H. Management of painful endometriosis in adolescents: CNGOF-HAS Endometriosis Guidelines. *Gynecol Obstet Fertil Senol*. 2018;46:264–266.
78. Laganà AS, Vitale SG, Granese R, et al. Clinical dynamics of dienogest for the treatment of endometriosis: from bench to bedside. *Expert Opin Drug Metab Toxicol*. 2017;13:593–596.
79. Walch K, Unfried G, Huber J, et al. Implanon versus medroxyprogesterone acetate: effects on pain scores in patients with symptomatic endometriosis—a pilot study. *Contraception*. 2009;79:29–34.
80. Slocum BN, Sanfilippo J. Current methods for the management of endometriosis in adolescent patients. *Expert Rev Endocrinol Metab*. 2017;12:1–4.
81. Divasta AD, Laufer MR, Gordon CM. Bone density in adolescents treated with a GnRH agonist and add-back therapy for endometriosis. *J Pediatr Adolesc Gynecol*. 2007;20:293–297.
82. Candiani M, Ottolina J, Posazdka E, et al. Assessment of ovarian reserve after cystectomy versus ‘one-step’ laser vaporization in the treatment of ovarian endometrioma: a small randomized clinical trial. *Hum Reprod*. 2018;33:2205–2211.
83. Laufer MR. Identification of clear vesicular lesions of atypical endometriosis: a new technique. *Fertil Steril*. 1997;68:739–740.
84. Brosens I, Gordts S, Benagiano G. Endometriosis in adolescents is a hidden, progressive and severe disease that deserves attention, not just compassion. *Hum Reprod*. 2013;28:2026–2031.
85. Laufer MR, Einarsson JJ. Surgical management of superficial peritoneal adolescent endometriosis. *J Pediatr Adolesc Gynecol*. 2019;32:339–341.
86. Abbott J, Hawe J, Hunter D, Holmes M, Finn P, Garry R. Laparoscopic excision of endometriosis: a randomized, placebo-controlled trial. *Fertil Steril*. 2004;82:878–884.
87. Tandoi I, Somigliana E, Riparini J, Ronzoni S, Vigano’ P, Candiani M. High rate of endometriosis recurrence in young women. *J Pediatr Adolesc Gynecol*. 2011;24:376–379.
88. Youngster M, Laufer MR, Divasta AD. Endometriosis for the primary care physician. *Curr Opin Pediatr*. 2013;25:454–462.
89. Raffaelli R, Garzon S, Baggio S, et al. Mesenteric vascular and nerve sparing surgery in laparoscopic segmental intestinal resection for deep infiltrating endometriosis. *Eur J Obstet Gynecol Reprod Biol*. 2018;231:214–219.
90. Martire FG, Russo C, Selntigia A, et al. Early noninvasive diagnosis of endometriosis: dysmenorrhea and specific ultrasound findings are important indicators in young women. *Fertil Steril*. 2023;119:455–464.
91. Millischer AE, Santulli P, da Costa S, et al. Adolescent endometriosis: prevalence increases with age at MRI scan. *Fertil Steril*. 2022 Dec 31. [Epub ahead of print].