

# Vaginal wall thickness as potential biomarker of vaginal health. A proposal for standardized ultrasound measurement using three-dimensional transvaginal ultrasound

Juan Luis Alcazar MD, PhD<sup>1</sup>  | Elisa Para MD<sup>2</sup> | Aida Tomaizhe MD<sup>3</sup> | Maria Victoria Laza MD<sup>4</sup> | Stefano Guerriero MD, PhD<sup>5</sup>

<sup>1</sup>Department of Obstetrics and Gynecology, Clínica Universidad de Navarra, Pamplona, Spain

<sup>2</sup>Department of Obstetrics and Gynecology, Hospital Universitario Sureste, Arganda del Rey, Spain

<sup>3</sup>Department of Obstetrics and Gynecology, Hospital Universitario Virgen de Valme, Sevilla, Spain

<sup>4</sup>Department of Obstetrics and Gynecology, Hospital Universitario Materno-Infantil, Badajoz, Spain

<sup>5</sup>Centro Integrato di Procreazione Medicalmente Assistita (PMA) e Diagnostica Ostetrico-Ginecologica, Azienda Ospedaliero Universitaria-Policlinico Duilio Casula Monserrato, University of Cagliari, Cagliari, Italy

## Correspondence

Juan Luis Alcazar, Department of Obstetrics and Gynecology, Clínica Universidad de Navarra, Avenida Pio XII 36, 3110 Pamplona, Spain.  
Email: [jalcazar@unav.es](mailto:jalcazar@unav.es)

## Abstract

Vaginal wall thickness could be used as a biomarker of vaginal health. We propose a standardized method using three-dimensional (3D) ultrasound for measuring vaginal wall thickness. Fill the vagina with gel. Insert the endovaginal transducer into the vagina up to the middle third. In the sagittal plane, visualizing the cervix and vaginal fornices, capture a 3D volume of the upper third of the vagina. Using tomographic ultrasound imaging function in the sagittal plane and the posterior vaginal fornix as the reference obtain at least three axial planes of the vagina, separated by 1 cm. Measure the vaginal wall thickness at a distance of 2 cm from the posterior vaginal fornix at 12, 3, 6, and 9 o'clock. The reproducibility of measurements was high. Measurements of vaginal wall thickness can be reliably performed.

## KEYWORDS

thickness, ultrasound, vagina, wall

## 1 | INTRODUCTION

Genitourinary syndrome of menopause (GSM) is defined as “a collection of signs and symptoms associated with estrogen deficiency that can involve changes to the labia, introitus, vagina, clitoris, bladder, and urethra.”<sup>1</sup>

The pathophysiology of GSM is due to a decrease in both estrogen and androgens.<sup>2</sup> This chronic and progressive entity affects up to 40%–54% of postmenopausal women and 15%–19% perimenopausal women.<sup>3,4</sup> The diagnosis of GSM is based on the history and physical examination findings,<sup>2,3</sup> and it is characterized by the presence of

vaginal dryness, irritation, burning, itching, and discomfort, as well as, urinary symptoms such as increased voiding frequency, urinary urgency and dysuria, and sexual symptoms.<sup>2</sup> In GSM, the vaginal epithelium becomes thin and more susceptible to trauma, and the tissue may appear dry, friable, and pale. Furthermore, this thinning will cause the underlying connective tissue to be exposed and increase the likelihood of inflammation.<sup>2–4</sup>

There are some biomarkers that are used for assessing vaginal health, such as the measurement of the vaginal pH and the vaginal maturation index.<sup>4</sup> In addition, some scores have been proposed for assessing vaginal atrophy such as the Vaginal Health Index<sup>4</sup>

This is an open access article under the terms of the [Creative Commons Attribution-NonCommercial-NoDerivs](https://creativecommons.org/licenses/by-nc-nd/4.0/) License, which permits use and distribution in any medium, provided the original work is properly cited, the use is non-commercial and no modifications or adaptations are made.

© 2023 The Authors. *Journal of Clinical Ultrasound* published by Wiley Periodicals LLC.

or the Most Bothersome Symptom Approach or the Day Impact of Vaginal Aging questionnaire.<sup>2</sup>

As vaginal wall thinning is a real phenomenon in the GSM, ultrasound measurement of vaginal wall thickness has been proposed as a potential biomarker of vaginal health. In fact, some authors have advocated this measurement using ultrasound.<sup>5–11</sup> However, we observed that there is no standardized approach for measuring vaginal wall thickness. For this reason, in the present manuscript, we aimed to propose a standardized method using three-dimensional (3D) ultrasound for measuring vaginal wall thickness by ultrasound as well as assessing the reproducibility of this measurement.

## 2 | HOW TO MEASURE VAGINAL WALL THICKNESS

For this study, we used a Voluson E10 equipped with a 3D volumetric 5–9 MHz endovaginal probe (RC5-9) for this study (GE Healthcare).

For measuring the vaginal wall thickness, we propose the following standardized approach in six steps:

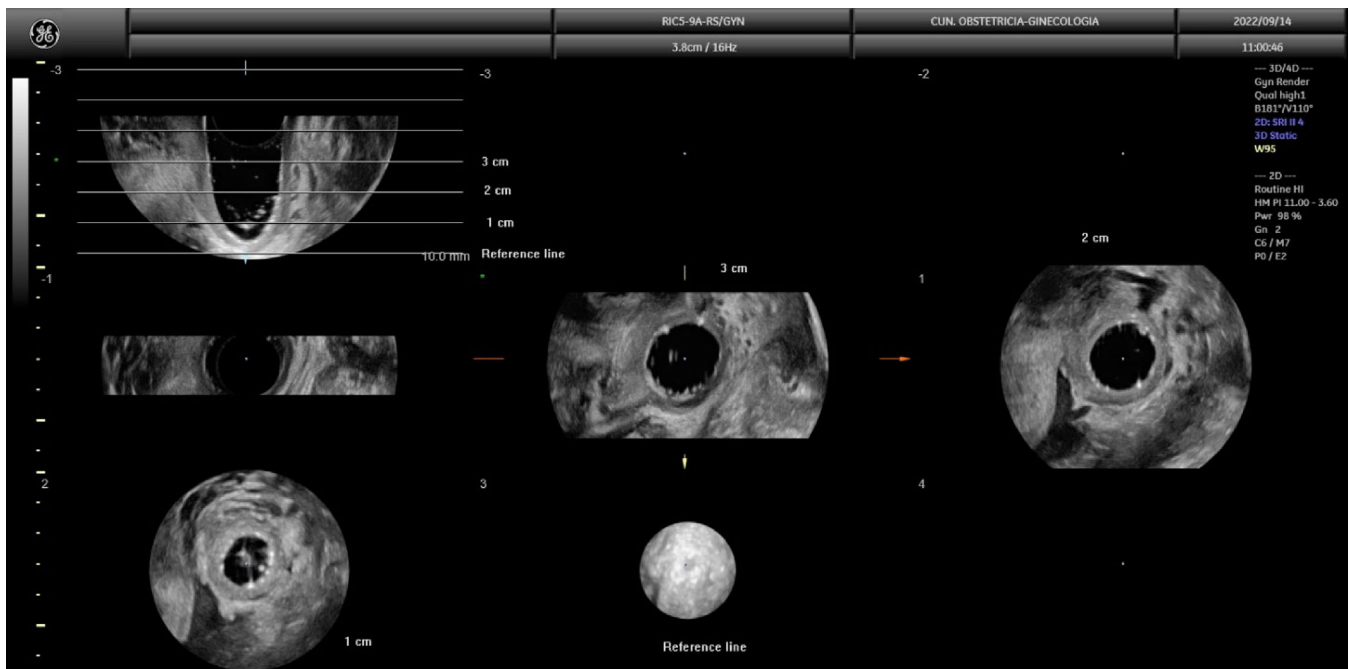
1. Fill the vagina with gel or use a glove's finger filled with gel to create an acoustic window.
2. Insert the endovaginal transducer into the vagina up to the middle third, not reaching vaginal fornices.
3. In the sagittal plane, visualizing the cervix and vaginal fornices, open the 3D box (90°) and capture a 3D volume of the proximal third of the vagina, including the cervical lips.

4. On the 3D volume, activate the volume contrast imaging function and use the tomographic ultrasound imaging (TUI) function in the sagittal plane. In the TUI image, using the posterior vaginal fornix as the reference line, obtain at least three axial planes of the vagina, separating each one by 1 cm (Figure 1).
5. Magnify the image by 1.5 (Figure 2)
6. Then, measure the vaginal wall thickness in the second axial plane (at a distance of 2 cm from the posterior vaginal fornix) at 12 (lateral right), 3 (posterior), 6 (lateral left), and 9 (anterior) o'clock (Figure 2)

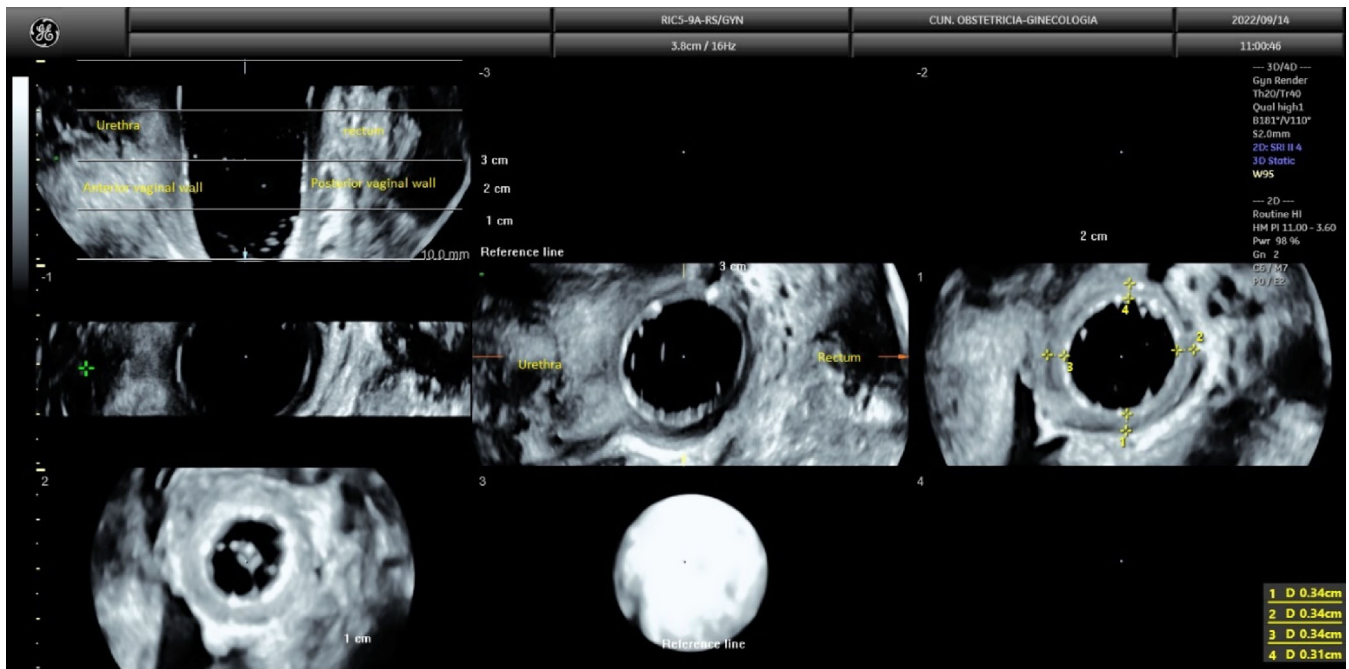
For assessing the reproducibility of this approach, two different examiners performed these measurements on 10 volunteer premenopausal women (mean age: 32 years old) who underwent a gynecological ultrasound within the context of routine gynecological check-ups. One examiner was an expert, with more than 30 years performing gynecological ultrasound, and the other examiner was a non-expert one, with less than 200 gynecological scans performed.

All patients gave oral informed consent. Institutional Review Board approval was waived since gynecological ultrasound is a routine procedure in our institution. The intra-class correlation coefficient (ICC) was used to calculate inter-observer reproducibility.

Vaginal wall thickness could be measured in all cases using this approach. Mean vaginal wall at 12, 3, 6, and 9 o'clock were 3.5 mm (SD: 1.0), 3.0 mm (SD: 0.9), 3.7 mm (SD: 1.3), and 3.2 mm (SD: 1.1) for Examiner A and 3.6 mm (SD: 1.1), 3.1 mm (SD: 1.0), 3.8 mm (SD: 1.1), and 3.3 mm (SD: 1.1) for Examiner B. The ICC for measurements at 12, 3, 6, and 9 o'clock were 0.896, 0.827, 0.926, and 0.963, respectively.



**FIGURE 1** Tomographic ultrasound imaging showing the reference line (posterior vaginal fornix) in the sagittal plane and the three axial planes at 1, 2, and 3 cm.



**FIGURE 2** Magnified tomographic ultrasound image, with volume contrast imaging function activated, showing the measurements in the axial plane at 2 cm from the reference line. Measurements are performed at 12 h o'clock (right lateral wall), 3 h o'clock (posterior wall), 6 h o'clock (left lateral wall), and 9 h o'clock (anterior wall). To orientate the planes, note that the sagittal plane is seen in the upper left corner of the image, being the anterior vaginal wall on the left and the posterior vaginal wall on the right.

### 3 | DISCUSSION

In the present manuscript, we propose a standardized method for measuring vaginal wall thickness using 3D ultrasound. Albeit the number of patients assessed is small, we observed that the proposed approach is feasible, can be performed in all patients and measurements are reproducible.

Some authors have advocated measuring the total vaginal wall thickness using transabdominal ultrasound in the sagittal plane using a full bladder approach.<sup>5-7</sup> The potential limitation of this approach is that full bladder distension could affect vaginal wall thickness by provoking an artificial thinning and due to lower resolution compared to the transvaginal route, it could be difficult to differentiate the bladder wall from the vaginal wall. Furthermore, no studies assessing the repeatability of this measurement have been reported.

Panayi et al. were the first to propose the vaginal wall thickness ultrasound measurement using the transvaginal route.<sup>8</sup> These authors proposed measuring the vaginal wall thickness in the sagittal plane, at the level of three anatomical landmarks on the anterior vaginal wall (bladder neck, apex of the bladder, and anterior fornix) and at the level of three sites on the posterior vaginal wall (the anorectal junction, the rectum, and the posterior fornix). These authors stated “the probe was applied to the vaginal wall with a minimum amount of pressure required for the probe to be in contact with the vagina. This was to avoid a distortion or pressure effect on the measurements,” positioning the calipers “at the edge of the vaginal wall closest to the probe and at the point closest to but not touching the organ adjacent to the vaginal wall at the relevant anatomical point.” However, by doing this,

it seems difficult to avoid some kind of pressure over the vaginal wall, and the resolution for measuring the vaginal wall, with the endovaginal probe just in contact with the vagina, could be very limited for differentiating the true limits of the vaginal wall. These authors reported that this approach was reproducible between two observers.

Recently, Pereira et al. have compared vaginal wall thickness measurements using transabdominal and transvaginal approaches.<sup>9</sup> Interestingly, these authors, in the transvaginal approach, used 40 mL of water-based gel in the vagina for separating vaginal walls and avoiding vaginal wall pressure with the probe. The measurements were performed in the anterior and posterior vaginal walls, at the proximal third of the vagina (anterior and posterior vaginal fornix), at the middle third (at the transition from the proximal urethra and rectum), and at the distal third (distal to urethra/vaginal introitus and anorectal junction). These authors observed significant differences in vaginal wall thickness (up to 3 mm) depending on the approach used, demonstrating that both techniques could not be used interchangeably. However, these authors did not assess inter-observer repeatability.

More recently, Ros et al. have reported a further study using a similar approach to Pereira's method, but measuring the vaginal wall at the four quadrants; that is, not only measuring the anterior and posterior vaginal walls but also the right and left lateral walls.<sup>10</sup> These measurements were performed in the proximal third of the vagina, “near the cervix” (it was not specified where exactly the measurements were performed). These authors did not assess the inter-observer repeatability of this approach.

Peker and Gursoy proposed the use of 3D transvaginal ultrasound for measuring vaginal wall thickness.<sup>11</sup> Measurements of the vaginal

wall thickness were performed at the level of the bladder neck and the anorectal junction. However, these authors propose inserting the probe into the vagina without gel, using a 360° endovaginal–endoanal probe, therefore, resolution could be limited and vaginal wall pressure cannot be avoided.

From the clinical point of view, ultrasound vaginal wall thickness measurement could be interesting for several reasons: as an additional tool for assessing the severity of GSM or as an objective method for predicting or evaluating response to different types of treatments, such as local estrogens, local dehydroepiandrosterone, selective estrogen receptor modulators or laser therapy.<sup>2</sup>

Our proposal for using 3D ultrasound might have the advantage of the precise location of anatomical landmarks for making measurements, which could yield a more standardized approach and more reproducible measurements. However, our proposal has, in turn, some limitations. Precisely, the use of 3D ultrasound as well as the use of specific software for performing measurements are not available in all ultrasound laboratories. Other limitations are that we just performed measurements in 10 patients, and no other patients' clinical data, such as parity, were taken into consideration.

In conclusion, measurements of vaginal wall thickness can be reliably performed using 3D ultrasound. In this small pilot study, the approach proposed seems to be reproducible between examiners. However, this approach needs to be validated in future studies. Furthermore, it must be assessed whether significant differences exist, in terms of measurements and reproducibility, between 2D and 3D approaches, as well as if using gel within the finger glove or directly into the vagina.

#### AUTHOR CONTRIBUTIONS

**Conceptualization:** Juan Luis Alcazar. **Methodology:** Juan Luis Alcazar, Elisa Para, Aida Tomaizhe, and Maria Victoria Laza. **Formal analysis:** Juan Luis Alcazar. **Investigation:** Aida Tomaizhe, Maria Victoria Laza, and Juan Luis Alcazar. **Data curation:** Juan Luis Alcazar. **Writing—original draft preparation:** Juan Luis Alcazar. **Writing—review and editing:** All authors. All authors have read and agreed to the published version of the manuscript.

#### CONFLICT OF INTEREST STATEMENT

The authors declare no conflict of interest.

#### DATA AVAILABILITY STATEMENT

Data are available upon reasonable request.

#### ORCID

Juan Luis Alcazar  <https://orcid.org/0000-0002-9700-0853>

#### REFERENCES

1. The NAMS 2020 GSM Position Statement Editorial Panel. The 2020 genitourinary syndrome of menopause position statement of the North American Menopause Society. *Menopause*. 2020;27:976-992.
2. Marino JM. Genitourinary syndrome of menopause. *J Midwifery Womens Health*. 2021;66:729-739.
3. Gandhi J, Chen A, Dagur G, et al. Genitourinary syndrome of menopause: an overview of clinical manifestations, pathophysiology, etiology, evaluation, and management. *Am J Obstet Gynecol*. 2016;215:704-711.
4. Sarmiento ACA, Costa APF, Vieira-Baptista P, Giraldo PC, Eleutério J Jr, Gonçalves AK. Genitourinary syndrome of menopause: epidemiology, physiopathology, clinical manifestation and diagnostic. *Front Reprod Health*. 2021;3:779398.
5. Balica A, Wald-Spielman D, Schertz K, Egan S, Bachmann G. Assessing the thickness of the vaginal wall and vaginal mucosa in premenopausal versus post-menopausal women by transabdominal ultrasound: a feasibility study. *Maturitas*. 2017;102:69-72.
6. Balica A, Schertz K, Wald-Spielman D, Egan S, Bachmann G. Transabdominal sonography to measure the total vaginal and mucosal thicknesses. *J Clin Ultrasound*. 2017;45:461-464.
7. Türk S, Ertürk Coşkun AD, Vural F. Ultrasonographic measurement of vaginal thickness: relation to menopausal status and genitourinary syndrome of menopause. *J Obstet Gynaecol Res*. 2022;48:2911-2917.
8. Panayi DC, Digesu GA, Tekkis P, Fernando R, Khullar V. Ultrasound measurement of vaginal wall thickness: a novel and reliable technique. *Int Urogynecol J*. 2010;21:1265-1270.
9. Pereira GMV, Juliato CRT, de Almeida CM, Valente IS, de Andrade KC, Brito LGO. Measurement of the vaginal wall thickness by transabdominal and transvaginal ultrasound of women with vaginal laxity: a cross-sectional study. *Int Urogynecol J*. 2022;33:3563-3572.
10. Ros C, Mension E, Rius M, et al. Assessing vaginal wall thickness by transvaginal ultrasound in breast cancer survivors: a pilot study. *Maturitas*. 2023;171:7-12.
11. Peker H, Gursoy A. Relationship between genitourinary syndrome of menopause and 3D high-frequency endovaginal ultrasound measurement of Vaginal Wall thickness. *J Sex Med*. 2021;18:1230-1235.

**How to cite this article:** Alcazar JL, Para E, Tomaizhe A, Laza MV, Guerriero S. Vaginal wall thickness as potential biomarker of vaginal health. A proposal for standardized ultrasound measurement using three-dimensional transvaginal ultrasound. *J Clin Ultrasound*. 2023;51(8):1366-1369. doi:10.1002/jcu.23547