



Observational Study

Hepatobiliary manifestations following two-stages elective laparoscopic restorative proctocolectomy for patients with ulcerative colitis: A prospective observational study

Tamer A A M Habeeb, Abdulzahra Hussain, Mauro Podda, Pasquale Cianci, Bruce Ramshaw, Khaled Safwat, Wesam M Amr, Tamer Wasefy, Alaa A Fiad, Mohamed Ibrahim Mansour, Adel Mahmoud Moursi, Gamal Osman, Anass Qasem, Mohamed Fawzy, Mohamed Ibrahim Abo Alsaad, Abd-Elfattah Kalmoush, Mohammed Shaaban Nassar, Fawzy M Mustafa, Mahmoud Hassib Morsi Badawy, Ahmed Hamdy, Hamdi Elbelkasi, Bassam Mousa, Abd-Elrahman M Metwalli, Walid A Mawla, Mostafa M Elaidy, Muhammad Ali Baghdadi, Ahmed Raafat

Specialty type: Gastroenterology and hepatology

Provenance and peer review: Unsolicited article; Externally peer reviewed.

Peer-review model: Single blind

Peer-review report's scientific quality classification

Grade A (Excellent): 0
Grade B (Very good): B
Grade C (Good): C
Grade D (Fair): 0
Grade E (Poor): 0

P-Reviewer: Hakimi T, Afghanistan; Piltcher-da-Silva R, Brazil

Received: October 7, 2022

Peer-review started: October 7, 2022

First decision: January 3, 2023

Revised: January 5, 2023

Accepted: February 3, 2023

Article in press: February 3, 2023

Published online: February 27, 2023

Tamer A A M Habeeb, Khaled Safwat, Wesam M Amr, Tamer Wasefy, Alaa A Fiad, Mohamed Ibrahim Mansour, Adel Mahmoud Moursi, Gamal Osman, Bassam Mousa, Abd-Elrahman M Metwalli, Walid A Mawla, Mostafa M Elaidy, Muhammad Ali Baghdadi, Ahmed Raafat, Department of General Surgery, Faculty of Medicine, Zagazig University, Zagazig 44759, Sharkia, Egypt

Abdulzahra Hussain, Homerton University Hospital, London E9 6SR, UK

Mauro Podda, Department of Surgical Science, University of Cagliari, Cagliari 2432, Italy

Pasquale Cianci, Department of Medical and Surgical Sciences, Università degli studi di Foggia, Foggia 546, Italy

Bruce Ramshaw, MD CQInsights PBC, Co-founder & CEO, Tennessee, TN 37010, United States

Anass Qasem, Department of Internal Medicine, Zagazig University, Zagazig 2355, Egypt

Mohamed Fawzy, Department of Internal Medicine, Suez University, Suez 235, Egypt

Mohamed Ibrahim Abo Alsaad, Department of General Surgery, Faculty of Medicine -Merit University, Sohag 82511, Egypt

Abd-Elfattah Kalmoush, Mohammed Shaaban Nassar, Fawzy M Mustafa, Mahmoud Hassib Morsi Badawy, Department of General Surgery, Al-azhar University, Cairo 285, Egypt

Ahmed Hamdy, Department of Hepato-Bilio-Pancreatic (HBP) Surgery, National Hepatology and Tropical Medicine Research Institute, Cairo 285, Egypt

Hamdi Elbelkasi, Department of General Surgery, Mataryia Teaching Hospital, Cairo 285, Egypt

Corresponding author: Tamer A A M Habeeb, MD, Professor, Department of General Surgery, Faculty of Medicine, Zagazig University, Zagazig 44759, Sharkia, Egypt.



tameralnaimy@hotmail.com

Abstract

BACKGROUND

Hepatobiliary manifestations occur in ulcerative colitis (UC) patients. The effect of laparoscopic restorative proctocolectomy (LRP) with ileal pouch anal anastomosis (IPAA) on hepatobiliary manifestations is debated.

AIM

To evaluate hepatobiliary changes after two-stages elective laparoscopic restorative proctocolectomy for patients with UC.

METHODS

Between June 2013 and June 2018, 167 patients with hepatobiliary symptoms underwent two-stage elective LRP for UC in a prospective observational study. Patients with UC and having at least one hepatobiliary manifestation who underwent LRP with IPAA were included in the study. The patients were followed up for four years to assess the outcomes of hepatobiliary manifestations.

RESULTS

The patients' mean age was 36 ± 8 years, and males predominated (67.1%). The most common hepatobiliary diagnostic method was liver biopsy (85.6%), followed by Magnetic resonance cholangiopancreatography (63.5%), Antineutrophil cytoplasmic antibodies (62.5%), abdominal ultrasonography (35.9%), and Endoscopic retrograde cholangiopancreatography (6%). The most common hepatobiliary symptom was Primary sclerosing cholangitis (PSC) (62.3%), followed by fatty liver (16.8%) and gallbladder stone (10.2%). 66.4% of patients showed a stable course after surgery. Progressive or regressive courses occurred in 16.8% of each. Mortality was 6%, and recurrence or progression of symptoms required surgery for 15%. Most PSC patients (87.5%) had a stable course, and only 12.5% became worse. Two-thirds (64.3%) of fatty liver patients showed a regressive course, while one-third (35.7%) showed a stable course. Survival rates were 98.8%, 97%, 95.8%, and 94% at 12 mo, 24 mo, 36 mo, and at the end of the follow-up.

CONCLUSION

In patients with UC who had LRP, there is a positive impact on hepatobiliary disease. It caused an improvement in PSC and fatty liver disease. The most prevalent unchanged course was PSC, while the most common improvement was fatty liver disease.

Key Words: Courses; Hepatobiliary manifestations; Primary sclerosing cholangitis; Restorative proctocolectomy

©The Author(s) 2023. Published by Baishideng Publishing Group Inc. All rights reserved.

Core Tip: There has been little research on the efficacy of proctocolectomy in ulcerative colitis patients with hepatobiliary manifestations. The course of hepatobiliary symptoms after proctocolectomy is being evaluated prospectively in our study. The main finding of this study was that two-thirds of patients had an unchanged course following surgery, whereas 16.8% had a progressive or regressive course. The mortality rate was 6%, and 15% of patients required surgery due to recurrence or worsening symptoms. Most primary sclerosing cholangitis patients (87.5%) had an unchanged course, with only 12.5% progressing. Two-thirds (64.3%) of fatty liver patients progressed, whereas one-third (35.7%) remained stationary. At 12, 24, 36, and 48 mo, the survival rates were 98.8%, 97%, 95.8%, and 94%, respectively.

Citation: Habeeb TAAM, Hussain A, Podda M, Cianci P, Ramshaw B, Safwat K, Amr WM, Wasefy T, Fiad AA, Mansour MI, Moursi AM, Osman G, Qasem A, Fawzy M, Alsaad MIA, Kalmoush AE, Nassar MS, Mustafa FM, Badawy MHM, Hamdy A, Elbelkasi H, Mousa B, Metwalli AEM, Mawla WA, Elaidy MM, Baghdadi MA, Raafat A. Hepatobiliary manifestations following two-stages elective laparoscopic restorative proctocolectomy for patients with ulcerative colitis: A prospective observational study. *World J Gastrointest Surg* 2023; 15(2): 234-248
URL: <https://www.wjgnet.com/1948-9366/full/v15/i2/234.htm>
DOI: <https://dx.doi.org/10.4240/wjgs.v15.i2.234>

INTRODUCTION

Inflammatory bowel disease (IBD) is expected to affect 1% of the population over the next decade[1]. Although the primary clinical manifestations of IBD are centred on the gastrointestinal tract, 25%–40% of IBD patients develop at least one extraintestinal manifestation (EIM)[2].

Hepatobiliary manifestations constitute one of the most common EIMs in IBD[3]. Primary sclerosing cholangitis (PSC), autoimmune hepatitis (AIH), fatty liver, cholelithiasis, primary biliary cholangitis, portal vein thrombosis, and hepatic abscess are the most prevalent hepatobiliary manifestations of ulcerative colitis (UC)[4,5].

Most UC patients can be managed with medications, but minorities require proctocolectomy[6]. Two-stage laparoscopic proctocolectomy (LRP) with ileal pouch-anal anastomosis (IPAA) is a cure for UC, but its effect on hepatobiliary diseases is controversial[6-10]. Therefore, we conducted a prospective observational study to examine the effects of LRP with IPAA on hepatobiliary symptoms to evaluate the role of surgery in preventing or ameliorating liver damage from the disease progression.

MATERIALS AND METHODS

Study design and participants

This is a prospective observational study on 167 patients with hepatobiliary manifestations who underwent two-stage elective LRP with IPAA for UC from June 2013 to June 2018 at our universities' hospitals. Inclusion criteria were all patients between 18 and 69 years; men and women with at least one hepatobiliary manifestation. In patients with UC, surgery was decided according to The European Crohn's and Colitis Organisation guidelines on therapeutics in UC[11]. Exclusion criteria included: Alcohol abuse, severe heart failure or type II diabetes mellitus, complications or death related to LRP operation, liver toxicity of IBD-related medications, active or chronic viral hepatitis, hemochromatosis, Wilson's disease, drugs-induced steatosis (amiodarone or tamoxifen), morbid obesity or patients undergoing bariatric surgery, immunoglobulin G4-related cholangitis; human immunodeficiency virus/acquired immune deficiency syndrome; tuberculosis; secondary sclerosing cholangitis; cholangiocarcinoma; complications of advanced PSC (hepatic encephalopathy, portal hypertension, hepatorenal syndrome, or hepato-pulmonary syndrome; end-stage liver failure), hypercoagulability status (systemic lupus erythematosus, increased von Willebrand factor or increased homocysteine level), oral contraceptive pills, Grave's disease, dyslipidemia, and previous biliary tract surgery including cholecystectomy.

Study ethics

The Institutional Review Board approved the study (Approval No. ZU IRB#9841). Each patient signed a written consent form, and the study followed the rules of the 1975 Declaration of Helsinki principles. In addition, the study was registered on ClinicalTrials.gov (NCT05495178) and done according to the Strengthening the Reporting of Observational Studies in Epidemiology guidelines.

Definitions of outcomes and measurements

PSC is progressive biliary fibrosis affecting intra and/or extrahepatic bile ducts[12] and diagnosed by laboratory tests [(cholestasis, Antineutrophil cytoplasmic antibodies (ANCA)], radiology [abdominal ultrasonography (US), abdominal computed tomography (CT), endoscopic retrograde cholangiopancreatography (ERCP), or magnetic resonance cholangiopancreatography (MRCP)], and liver biopsy. Primary biliary cholangitis (PBC) is characterized by the loss of small and medium-sized bile ducts on liver biopsy, elevated anti-mitochondrial antibodies, and altered gamma-glutamyl transferase and alkaline phosphatase (ALP) levels[13]. Non-alcoholic fatty liver disease (NAFLD) is characterized by fat storage in $\geq 5\%$ of hepatic steatosis in the absence of concomitant liver disease (chronic viral hepatitis), use of steatosis-inducing medications (amiodarone or tamoxifen), autoimmune hepatitis, hemochromatosis, Wilson's disease, or excessive alcohol consumption[14]. Diagnosis of NAFLD was made by liver biopsies or US[15], and the severity score was previously stated[16]. Autoimmune hepatitis

diagnosis based on the International Autoimmune Hepatitis Group criteria with a score of > 15 points consisting of demographic, histologic, and laboratory markers, including antinuclear antibodies with a titer of at least 1:40 and liver histology[17]. An aseptic liver abscess is diagnosed based on IBD history, US, and CT[18]. Ultrasound, colour Doppler, and/or CT scans were used to detect portal vein thrombosis.

Perioperative technique and follow-up after surgery

For patients with UC who require surgery, two stages of LRP with IPAA and a diverting loop ileostomy are the gold standard[19]. The diverting loop ileostomy was reversed 2-3 mo following surgery. Because of the increased risk of thromboembolic events, prophylactic anticoagulation medication was scheduled and continued for six months after surgery. The follow-up period was four years, and cases lost during the follow-up period were excluded from the study.

Follow-up with the clinical progression of patients' conditions and laboratory evaluations was performed at six months, one year, two years, three years, and four years, or at any time of patients' complaint. These data were compared to data obtained immediately before surgery (at the time of surgery). Follow-ups were performed at outpatient clinics, *via* phone, or by email. Laboratory (Liver function tests, antibodies, Cancer antigen 19-9) and radiology (abdominal ultrasonography, colour Doppler, CT, MRCP) tests were performed as part of the follow-up assessments. An endoscopic examination of the ileal pouch on an annual basis was arranged. A liver biopsy was planned at the end of the study.

Statistical methods

Version 28 of SPSS was used for data management and statistical analysis (IBM, Armonk, New York, United States). The normality of quantitative data was evaluated using the Kolmogorov-Smirnov test, the Shapiro-Wilk test, and direct data visualization methods. Means and standard deviations, or medians and ranges based on normality tests, were used to summarize the quantitative data. As a summary of categorical data, numbers and percentages were used. The McNemar test compared laboratory and clinical findings before and after surgery. We used a Kaplan-Meier analysis to estimate overall survival and recurrence-free survival. The independent *t*-test or the Mann-Whitney *U* test for normally and non-normally distributed quantitative variables was used to compare the regression rates of hepatobiliary manifestations in the two groups. We compared categorical data using the Chi-square test. Multivariate logistic regression analysis was done to predict no regression of hepatobiliary manifestations. Each significant variable on the univariate levels was included in a multivariate regression model and adjusted for age, gender, smoking, family history of UC, and UC duration. The odds ratios and confidence intervals at 95% were calculated. All statistical tests were two-sided. *P* values < 0.05 were considered statistically significant.

RESULTS

General characteristics

Figure 1 shows the flow diagram of the inclusion and exclusion criteria of the study cohort. As shown in Table 1, the mean age was 36 ± 8 years, with male predominance (67.1%). The most frequent diagnostic method for hepatobiliary manifestations was liver biopsy (85.6%), followed by MRCP (63.5%), ANCA (62.5%), US (35.9%), and ERCP (6%). Figure 2 shows the frequency of different hepatobiliary manifestations.

Outcomes

After surgery, there were clinical and laboratory improvements (Table 2 and Figure 3). Figure 4 showed that 66.4% of patients had a stationary course. In comparison, 16.8% of patients showed a progressive or regressive course, and there are variations in the courses of different types of hepatobiliary manifestations.

Overall survival and recurrence-free survival using kaplan-meier analysis

The survival rate was 98.8%, 97%, 95.8%, and 94% at 12 mo, 24 mo, 36 mo, and at the end of the follow-up. Regarding the recurrence or progression of symptoms requiring surgery, the recurrence-free rate at 12 mo was 98.2%. At 24 mo, it was 92.8%. At 36 mo, it was 89.2%. At the end of the follow-up, it reached 85% (Figure 5).

Factors affecting regression of hepatobiliary manifestations

Patients with no regression (stationary and progressive course) demonstrated higher use of anti-Tumor necrosis factor (15.1% *vs* 0%, *P* = 0.028), corticosteroids (43.2% *vs* 17.9%, *P* = 0.012), and hepatobiliary treatment (80.6% *vs* 7.1%, *P* < 0.001). In addition, they demonstrated higher percentages of high alanine transaminase (ALT) (74.8 *vs* 39.3%, *P* < 0.001), high aspartate aminotransferase (AST) (75.5% *vs* 57.1%, *P*

Table 1 General characteristics of the studied patients, *n* (%)

General characteristics	
Age (yr) (mean ± SD)	36 ± 8
Sex	
Male	112 (67.1)
Female	55 (32.9)
Smoking	50 (29.9)
Family history of ulcerative colitis	35 (21.0)
Ulcerative colitis disease duration before surgery (mo)	39 (4 - 90)
Treatment of ulcerative colitis	
Mesalazine	137 (82.0)
Sulphasalazine	30 (18.0)
Anti-TNF	21 (12.6)
Corticosteroids	65 (38.9)
Type of PSC ¹	
Large duct PSC	83 (79.8)
Small duct PSC	21 (20.2)
Family history of PSC	14 (8.4)
Diagnosis and treatment of hepatobiliary manifestations	
Diagnostic methods	
ANCA	104 (62.3)
MRCP	106 (63.5)
ERCP	10 (6.0)
Liver biopsy	143 (85.6)
Ultrasound	60 (35.9)
Treatment	
UDCA	106 (63.5)
LMWH	6 (3.6)
Steroid	2 (1.2)
Obeticholic acid	2 (1.2)
Sonar guided drainage	1 (0.6)
Fibrates	2 (1.2)
Azathioprine	1 (0.6)

¹Percentages calculated based on a total of 104 patients with PSC.

Data were presented as mean ± SD, median (min-max), or number (percentage).

Anti-TNF: Anti-tumour necrosis factor; PSC: Primary sclerosing cholangitis; ANCA: Antineutrophil cytoplasmic antibodies; MRCP: Magnetic resonance cholangiopancreatography; ERCP: Endoscopic retrograde cholangiopancreatography; UDCA: Ursodeoxycholic acid; LMWH: Low-molecular-weight heparin.

= 0.047), high alkaline phosphatase (71.2% vs 3.6%, $P < 0.001$), jaundice (67.6% vs 46.4%, $P = 0.033$), pruritus (59% vs 14.3%, $P < 0.001$), and fever (24.5% vs 3.6%, $P = 0.013$). Age ($P = 0.578$), gender ($P = 0.327$), smoking ($P = 0.780$), family history ($P = 0.278$), duration of UC ($P = 0.877$), treatment for UC ($P = 0.601$), family history of PSC ($P = 0.079$), pain ($P = 0.496$), and fatty liver score ($P = 0.121$) were not found to be significantly different (Table 3).

Prediction of no regression of hepatobiliary symptoms

The predictors of no regression were steroid treatment (OR = 3.68, 95%CI = 1.29 - 10.45, $P = 0.015$), high

Table 2 Laboratory and clinical findings before (immediately before surgery) and after surgery (at the end of the study), n (%)

		P value
High ALT		
Before surgery	115 (68.9)	< 0.001 ¹
After surgery	54 (32.3)	
High AST		
Before surgery	121 (72.5)	< 0.001 ¹
After surgery	68 (40.7)	
High alkaline phosphatase		
Before surgery	100 (59.9)	< 0.001 ¹
After surgery	63 (37.7)	
High bilirubin		
Before surgery	114 (68.3)	< 0.001 ¹
After surgery	74 (44.3)	
Pain		
Before surgery	110 (65.9)	< 0.001 ¹
After surgery	71 (42.5)	
Jaundice		
Before surgery	107 (64.1)	< 0.001 ¹
After surgery	73 (43.7)	
Pruritus		
Before surgery	86 (51.5)	< 0.001 ¹
After surgery	59 (35.3)	
Fever		
Before surgery	35 (21.0)	< 0.001 ¹
After surgery	21 (12.6)	
Fatty liver score		
Before surgery	2 (1-3)	< 0.001 ¹
After surgery	1 (0-3)	

¹Significant bilirubin (normal range < 20 mmol/L) alanine aminotransferase (ALAT) (normal range < 39 U/L, gamma-glutamyl transpeptidase (GGT) (normal range < 42 U/L), alkaline phosphatase (ALP) (normal range 60-275 U/L).

Data were presented as number (percentage) or median (min-max).

ALT: Alanine aminotransferase; AST: Aspartate transaminase ALP: Alkaline phosphatase; GGT: Gamma-glutamyl transpeptidase; ALAT: Alanine aminotransferase.

ALT (OR = 5.39, 95%CI = 2.19 - 13.28, $P < 0.001$), high AST (OR = 2.59, 95%CI = 1.08 - 6.2, $P = 0.032$), high ALP (OR = 73.59, 95%CI = 9.52 - 568.93, $P < 0.001$), high bilirubin (OR = 2.72, 95%CI = 1.16 - 6.4, $P = 0.022$), jaundice (OR = 2.49, 95%CI = 1.07 - 5.8, $P = 0.034$), pruritus (OR = 9.75, 95%CI = 3.12 - 30.5, $P < 0.001$), and fever (OR = 9.7, 95%CI = 1.25 - 75.03, $P = 0.029$). The predictors with their odds ratios and 95% confidence intervals are illustrated in [Table 4](#).

DISCUSSION

To the best of our knowledge, this is the first current study to investigate the course of hepatobiliary symptoms in patients with UC after elective two-stage LRP with IPAA. Colectomy was correlated to a considerably low rate of progressive course in this study of 167 patients: 66.4% for an unchanged course, 16.8% for a regressive course, and 16.8% for a progressive course. There were not many changes for PSC

Table 3 Factors affecting regression of hepatobiliary manifestations, *n* (%)

	Manifestations regression		P value
	Yes (<i>n</i> = 28)	No (<i>n</i> = 139)	
Age (yr)	37 ± 7	36 ± 8	0.578
Sex			
Males	21 (75)	91 (65.5)	0.327
Females	7 (25)	48 (34.5)	
Smoking	9 (32.1)	41 (29.5)	0.780
Family history	8 (28.6)	27 (19.4)	0.278
UC duration (mo)	37 (7-81)	40 (4-90)	0.877
UC treatment			
Mesalazine	22 (78.6)	115 (82.7)	0.601
Sulphasalazine	6 (21.4)	24 (17.3)	
Anti-TNF	0 (0)	21 (15.1)	0.028 ¹
Corticosteroids	5 (17.9)	60 (43.2)	0.012 ¹
Hepatobiliary manifestations			
Autoimmune hepatitis	1 (3.6)	0 (0)	NA
Fatty liver	18 (64.3)	10 (7.2)	
Gall bladder stone	0 (0)	17 (12.2)	
Liver abscess	0 (0)	1 (0.7)	
Primary biliary cholangitis	1 (3.6)	1 (0.7)	
PSC	0 (0)	104 (74.8)	
Portal vein thrombosis	0 (0)	6 (4.3)	
Reactive hepatitis	8 (28.6)	0 (0)	
Type of PSC			
Large duct PSC	0 (0)	83 (79.8)	NA
Small duct PSC	0 (0)	21 (20.2)	
Family history of PSC	0 (0)	14 (10.1)	0.079
Hepatobiliary treatment	2 (7.1)	112 (80.6)	< 0.001 ¹
High ALT	11 (39.3)	104 (74.8)	< 0.001 ¹
High AST	16 (57.1)	105 (75.5)	0.047 ¹
High Alkaline phosphatase	1 (3.6)	99 (71.2)	< 0.001 ¹
High bilirubin	14 (50)	100 (71.9)	0.023 ¹
Pain	20 (71.4)	90 (64.7)	0.496
Jaundice	13 (46.4)	94 (67.6)	0.033 ¹
Pruritus	4 (14.3)	82 (59)	< 0.001 ¹
Fever	1 (3.6)	34 (24.5)	0.013 ¹
Fatty liver score	2 (1-3)	2 (2-3)	0.121

¹Significant.

Data were presented as mean ± SD, number (percentage), or median (min-max).

PSC: Primary sclerosing cholangitis; NA: Not applicable; Anti-TNF: Anti-tumour necrosis factor; UC: Ulcerative colitis; ALT: Alanine aminotransferase; AST: Aspartate transaminase.

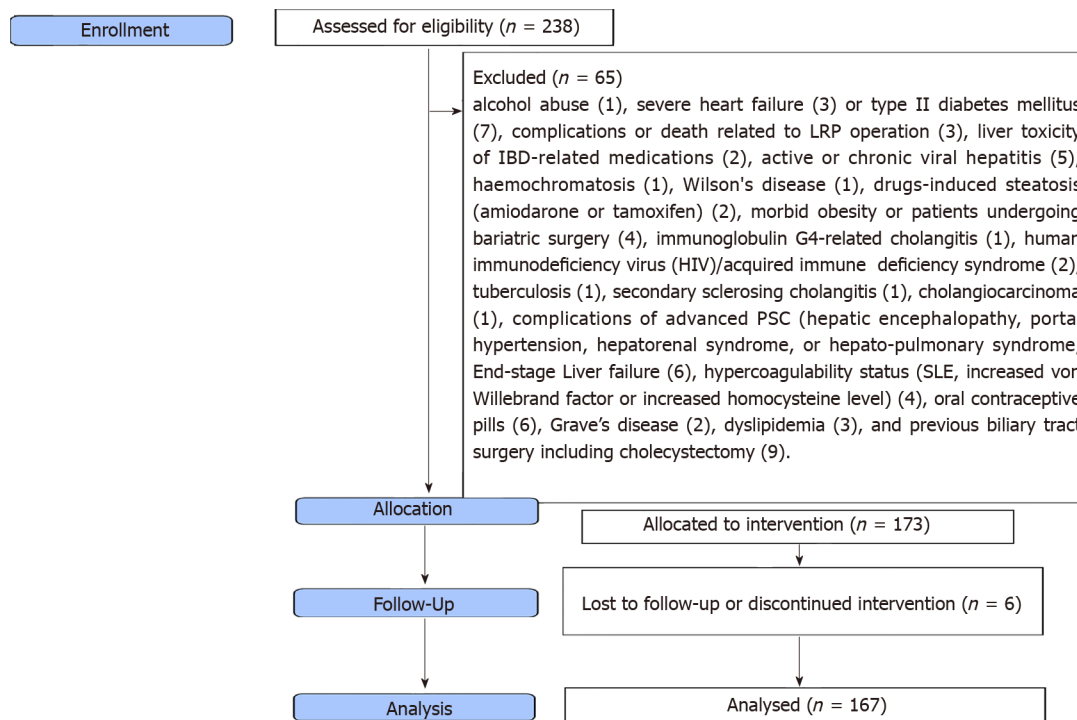
Table 4 Multivariate logistic regression analysis to predict no regression of hepatobiliary symptoms

	OR (95%CI) ²	P value
Steroid treatment	3.68 (1.29-10.45)	0.015 ¹
High ALT	5.39 (2.19-13.28)	< 0.001 ¹
High AST	2.59 (1.08-6.20)	0.032 ¹
High ALP	73.59 (9.52-568.93)	< 0.001 ¹
High bilirubin	2.72 (1.16-6.4)	0.022 ¹
Jaundice	2.49 (1.07-5.8)	0.034 ¹
Pruritus	9.75 (3.12-30.50)	< 0.001 ¹
Fever	9.7 (1.25-75.03)	0.029 ¹

¹Significant.

²Adjusted for age, gender, smoking, family history of UC, and UC duration; OR: Odds ratio; 95%CI: 95% confidence interval.

UC: Ulcerative colitis; ALT: Alanine aminotransferase; AST: Aspartate transaminase ALP: Alkaline phosphatase.

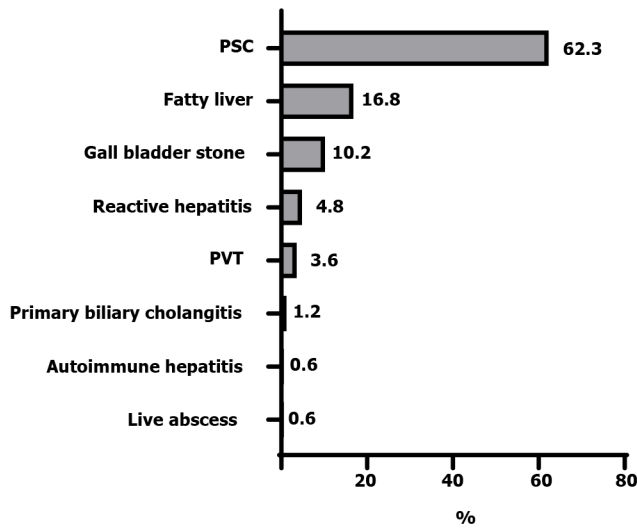


DOI: 10.4240/wjgs.v15.i2.234 Copyright © The Author(s) 2023.

Figure 1 Flow diagram of inclusion and exclusion criteria of the studied patients. IBD: Inflammatory bowel disease; HIV: Human immunodeficiency virus; SLE: Systemic lupus erythematosus; PSC: Primary sclerosing cholangitis.

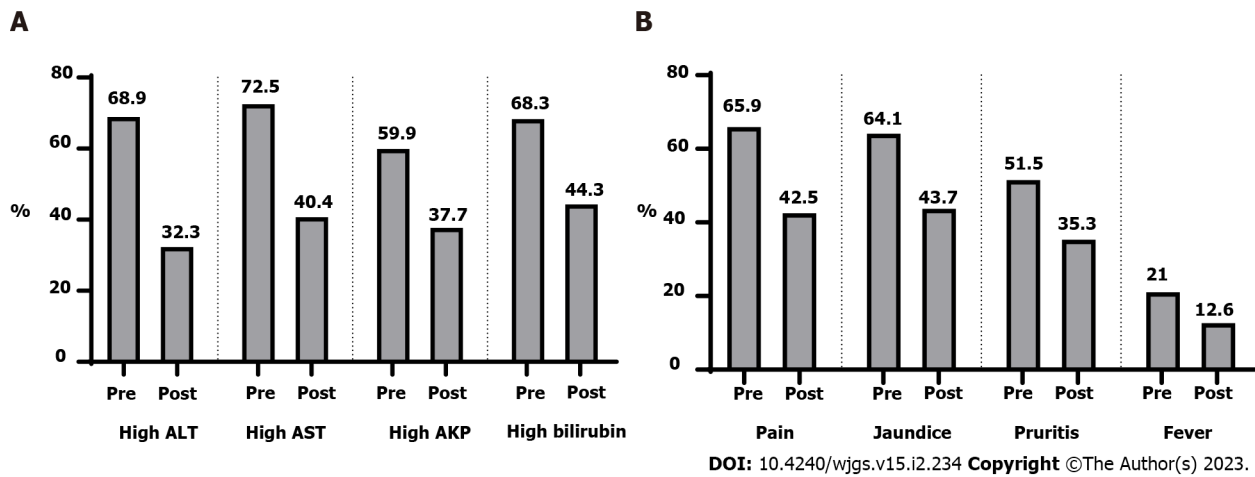
(91/104, 87.5%), while the most progressive cases were gallbladder disorders (12/17, 70.5%), and the most regressive cases were fatty liver (18/28, 64.3%).

Many theories have been proposed to explain the course of PSC after LRP with IPAA, including autoimmune phenomena[20], liver-gut crosstalk[21], the influence of saturated fat on changes in the bile acid pool, with an increase in the taurocholic acid[22], and bacterial translocation or absorption of bacterial endotoxins into the portal circulation *via* a chronically inflamed bowel with Kupffer cell activation[23-26]. The effects of colectomy on PSC have been documented in conflicting ways. Colectomy was beneficial according to a study by Lepistö *et al*[6] that stated that PSC severity increased in four (13%) patients, regressed in 15 (50%), and stayed stationary in 11 (37%). Regarding the incidence of progression, our findings are identical to those of this study, but not in the incidence of stationary and regressive courses. Our stationary course of PSC is higher (87.5% *vs* 37%), and none of the cases in our study demonstrated a regression course. We performed liver biopsies and MRCP on all PSC patients prior to surgery and during the follow-up period, whereas the previous study relied on liver function



DOI: 10.4240/wjgs.v15.i2.234 Copyright ©The Author(s) 2023.

Figure 2 Hepatobiliary manifestations of the studied patients. PSC: Primary sclerosing cholangitis.; PVT: Portal vein thrombosis.



DOI: 10.4240/wjgs.v15.i2.234 Copyright ©The Author(s) 2023.

Figure 3 Laboratory and clinical findings before and after surgery. A: Laboratory findings before and after surgery; B: Clinical findings before and after surgery. ALT: Alanine transaminase; AST: Aspartate aminotransferase; AKP: Alkaline phosphatase.

for diagnosis and did not perform liver biopsies on all patients. Furthermore, our study had a large number of patients, and cases lost to follow-up were excluded from our study (in comparison to earlier study). Our study's higher stable course of PSC may be attributable to Ursodeoxycholic acid (UDCA) (15 mg/kg/day) in all patients after LRP, whereas only 9/30 patients had UDCA following colectomy in the prior study. Treatment with UDCA has a beneficial effect on the course of PSC; studies have demonstrated efficacy[27-30]. A good proportion of PSC cases not progressing to a more severe form is associated with the absence of pouchitis in all of our patients' ileoanal pouch anastomosis. The study corroborated our conclusion that pouchitis may aggravate PSC[31].

In contrast, another study by Cangemi *et al*[7] stated that proctocolectomy exerted no beneficial effect on PSC, the stage of which has remained unchanged or has progressed with no statistically significant improvements in liver function test values[7]. On the contrary, our results showed a statistically significant improvement in liver function test values after surgery. Variations in the results could be attributed to methodological differences, diagnostic procedures (liver biopsy in 71% of cases only), and the number of cases. Perhaps, the effect of LRP on PSC is beneficial, as evidenced by the higher percentage of stable disease and smaller progressive cases. Another study by Treeprasertsuk *et al*[32] discovered that proctocolectomy had no benefit and a lower survival rate than expected. They experienced only progressive courses with higher mortality rates; LCF, acute cholangitis, right hepatic vein thrombosis with liver infarcts, and many cases that needed liver transplantation. The poor prognosis could be attributed to the study's small sample size, open approach, surgical difficulties, and heterogeneity in selection criteria, particularly the inclusion of cirrhotic patients with low platelet counts and albumin levels.

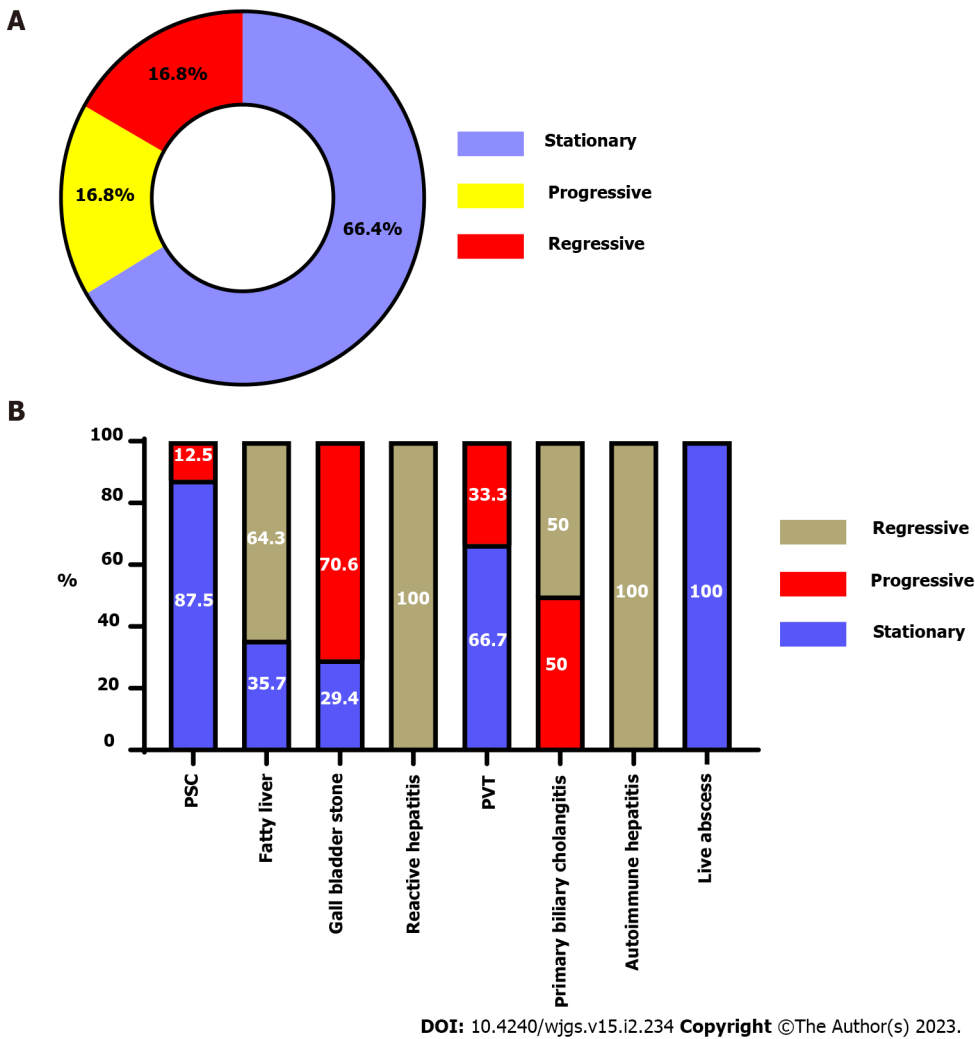


Figure 4 The course and outcome of each hepatobiliary manifestations. A: Hepatobiliary manifestations course in the studied patients; B: The outcome for each hepatobiliary manifestation. PSC: Primary sclerosing cholangitis.; PVT: Portal vein thrombosis.

In patients with LRP, resection of a short segment of the ileum and the entire colon inhibits bile acid absorption, resulting in supersaturation of biliary cholesterol[8], pouch metaplasia with decreased primary bile acid absorption[33], and delayed gall bladder emptying[34]. We found a high incidence of recurrent biliary colic requiring surgery (12/17, 70.5%), while the remaining five cases had a stationary course without symptoms. Concomitant cholecystectomy with LRP may prolong the operative time (nearly 40 min) and add more risk of complications. However, it saves the patient from going through more difficult cholecystectomy operation /gallstone complications in the future[35]. There were no cases of gallbladder cancer in our study. This is because most gallstone cases develop symptoms following LRP, necessitating cholecystectomy. Another problem is the short duration of follow-up (4 years).

Multiple studies showed that proctocolectomy could help with fatty liver regression[7,36,37]. We agree with prior evidence that proctocolectomy is favourable for NAFLD. LRP had a positive effect on fatty liver, with 18 cases (18/28, 64%) showing complete regression to normal liver and the remaining ten patients (36%) showing a stationary course. This improvement is due to improvements in malnutrition, anaemia, and a reduction in corticosteroid dosage during the surgical follow-up period, as supported by a study[38]. NAFLD progression was not observed in our cases due to the absence of pouchitis. As a result, we concluded that proctocolectomy plays a definitive role in the management of NAFLD-complicating UC, as evidenced by radiology and liver biopsy (improvement of fatty liver score from a median of 2 (range 1-3) in preoperative biopsies to a median of 1 (range 0-3) in postoperative biopsies).

High incidence of portal vein thrombosis (PVT) in IBD may be due to increased factors V and VIII levels, platelet counts, fibrinogen levels, or decreased antithrombin III levels[39,40]. In our study, we identified six patients with PVT: Four cases before surgery, no recurrence after surgery, and two patients who developed PVT after surgery. One of the two postoperative PVT cases exhibited partial portal vein obstruction, which was treated with anticoagulants. In contrast, the second case exhibited complete obstruction of PVT with intestinal gangrene, necessitating resection of the majority of the

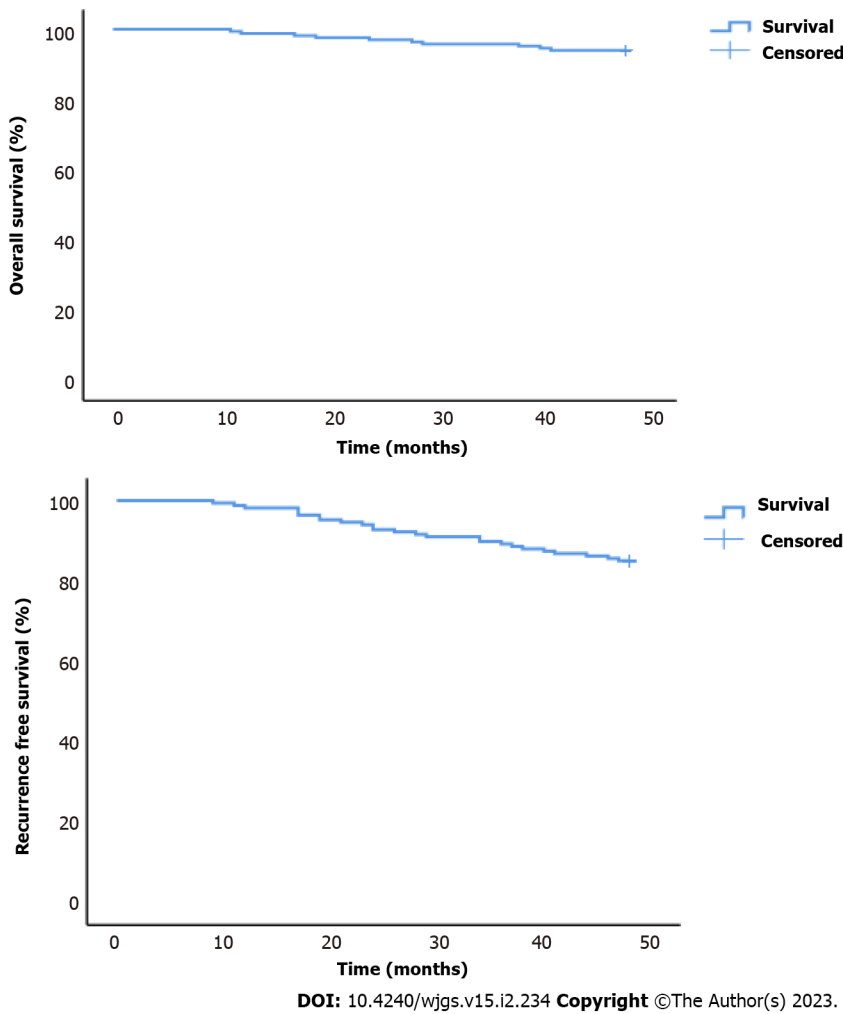


Figure 5 Overall and recurrence-free survival of the studied patients.

small intestine with short bowel syndrome, and died two months later. The low incidence of postoperative PVT can be due to the small number of cases, the routine use of low molecular heparin in the postoperative period for six months in all cases according to the current society guidelines and expert opinion[40], absence of pouchitis which increases the incidence of PVT[41], and the possible occurrence of PVT not associated with specific symptoms or asymptomatic[42]. The use of abdominal ultrasound and colored Doppler at regular intervals unquestionably aided in detecting asymptomatic cases. We concluded that proctocolectomy decreases the incidence but not the severity of PVT with an unfavorable outcome, despite the small number of cases, with a mortality rate of 50% among those who developed PVT is similar to the findings of other studies[43].

Two isolated PBC accidentally discovered cases were included; one regressed to normal liver condition, while the other progressed to liver cell failure and required liver transplantation without mortality. We thought that the excellent prognosis was due to obeticholic acid that improved the course of the disease[44], removal of the colon, the site of antibody production, which helped make the prognosis better after surgery, and absence of pouchitis[9].

One patient with UC developed a liver abscess before surgery, whereas no such case was reported after LRP. We concur with the pathogenesis that liver abscess may be caused by antibodies produced by patients with UC attacking the liver, resulting in necrosis and abscess formation that was negative for bacteria[45]. Proctocolectomy permanently eliminates the site of antibody production. Furthermore, postoperative corticosteroids help to prevent recurrence[46]. Proctocolectomy prevents liver abscesses, according to our findings.

One case of AIH was diagnosed before surgery and regressed to normal following LRP with a favourable prognosis, demonstrating the positive effects of proctocolectomy[47]. The favorable prognosis of our patient was likely due to the removal of the inflamed colon and steroid-based immunosuppressive therapy[10].

An earlier study confirmed the efficacy of proctocolectomy for nonspecific reactive hepatitis[7]. In accordance with the previous study's findings, we diagnosed 8 patients with nonspecific reactive hepatitis, and complete regression in every case was confirmed.

Strengths and limitations

This is a large prospective multicenter study of different hepatobiliary manifestations assessment after LRP with a relatively long duration of patient follow-up. We also included comprehensive clinical points evaluating different courses of hepatobiliary manifestations. A prospective study prevents selection bias with accurate results that could be generalized.

However, our study has some limitations. One is the lack a control group of patients that were not operated on. Therefore, this study did not handle the severity of preoperative colitis and its effect on the course of hepatobiliary manifestations in the postoperative period. Another limitation is that it did not evaluate the disease course after liver transplantation. Another limitation is that we did not evaluate the treatment of both UC and hepatobiliary manifestations during the postoperative course. Finally, we did not evaluate the causes of the high incidence of symptomatic gallbladder stones.

CONCLUSION

This is a large prospective multicenter study of different hepatobiliary manifestations assessment after LRP with a relatively long duration of patient follow-up. We also included comprehensive clinical points evaluating different courses of hepatobiliary manifestations. A prospective study prevents selection bias with accurate results that could be generalized.

However, our study has some limitations. One is the lack a control group of patients that were not operated on. Therefore, this study did not handle the severity of preoperative colitis and its effect on the course of hepatobiliary manifestations in the postoperative period. Another limitation is that it did not evaluate the disease course after liver transplantation. Another limitation is that we did not evaluate the treatment of both UC and hepatobiliary manifestations during the postoperative course. Finally, we did not evaluate the causes of the high incidence of symptomatic gallbladder stones.

ARTICLE HIGHLIGHTS**Research background**

Inflammatory bowel disease (IBD) is expected to affect 1% of the population over the next decade. Hepatobiliary manifestations constitute one of the most common extraintestinal manifestations in IBD. Primary sclerosing cholangitis (PSC), autoimmune hepatitis, fatty liver, cholelithiasis, primary biliary cholangitis, portal vein thrombosis, and hepatic abscess are the most prevalent hepatobiliary manifestations of ulcerative colitis (UC). Most UC patients can be managed with medications, but minorities require proctocolectomy.

Research motivation

Two-stage laparoscopic proctocolectomy (LRP) with ileal pouch-anal anastomosis (IPAA) is a cure for UC, but its effect on hepatobiliary diseases is controversial.

Research objectives

Therefore, we conducted a prospective observational study to examine the effects of LRP with IPAA on hepatobiliary symptoms to evaluate the role of surgery in preventing or ameliorating liver damage from the disease progression.

Research methods

This is a prospective observational study on 167 patients with hepatobiliary manifestations who underwent two-stage elective LRP with IPAA for UC. We examined the effects of LRP with IPAA on hepatobiliary symptoms to evaluate the role of surgery in preventing or ameliorating liver damage from the disease progression.

Research results

The course of hepatobiliary manifestations after surgery is improved in most forms. Most PSC patients had a stable course, Two-thirds of fatty liver patients showed a regressive course with an improved survival rate at the end of the study.

Research conclusions

Our study emphasized the positive and improving effects of surgery on hepatobiliary manifestations in patients with UC.

Research perspectives

Further studies are required in a larger sample size to evaluate the effect of surgery on different forms of hepatobiliary manifestations in patients with UC. further studies are required to compare the effect of surgery and effects of medical treatment.

FOOTNOTES

Author contributions: Habeeb TAAM is the corresponding author and is responsible for patient recruitment; Habeeb TAAM, Hussain A, Podda M, Cianci P, Ramshaw B, Safwat K, Amr WM, Wasefy T, Fiad AA, Mansour MI, Moursi AM, Osman G, Qasem A, Fawzy M, Alsaad MIA, Kalmoush A, Nassar MS, Mustafa FM, Badawy MHM, Hamdy A, Elbelkasi H, Mousa B, Metwalli AM, Mawla WA, Elaiddy MM, Baghdadi MA, Raafat A shared data collection, data analysis, study design, and writing up the first draft and final form of the manuscript; All authors accept the final version of the manuscript.

Institutional review board statement: The study was reviewed and approved by the Zagazig University Institutional Review Board (Approval No. ZU IRB#9841).

Informed consent statement: Informed written consent was obtained from the patient and her family for publication of this report and any accompanying images.

Conflict-of-interest statement: All the authors report no relevant conflicts of interest for this article.

Data sharing statement: Data will be available by the author on demand.

STROBE statement: The authors have read the STROBE Statement – checklist of items, and the manuscript was prepared and revised according to the STROBE Statement – checklist of items.

Open-Access: This article is an open-access article that was selected by an in-house editor and fully peer-reviewed by external reviewers. It is distributed in accordance with the Creative Commons Attribution NonCommercial (CC BY-NC 4.0) license, which permits others to distribute, remix, adapt, build upon this work non-commercially, and license their derivative works on different terms, provided the original work is properly cited and the use is non-commercial. See: <https://creativecommons.org/licenses/by-nc/4.0/>

Country/Territory of origin: Egypt

ORCID number: Tamer A A M Habeeb 0000-0002-7049-4267; Mauro Podda 0000-0001-9941-0883; Pasquale Cianci 0000-0003-2839-2520.

S-Editor: Liu GL

L-Editor: A

P-Editor: Liu GL

REFERENCES

- 1 **Kaplan GG**, Windsor JW. The four epidemiological stages in the global evolution of inflammatory bowel disease. *Nat Rev Gastroenterol Hepatol* 2021; **18**: 56-66 [PMID: 33033392 DOI: 10.1038/s41575-020-00360-x]
- 2 **Guillo L**, D'Amico F, Serrero M, Angioi K, Loeuille D, Costanzo A, Danese S, Peyrin-Biroulet L. Assessment of extraintestinal manifestations in inflammatory bowel diseases: A systematic review and a proposed guide for clinical trials. *United European Gastroenterol J* 2020; **8**: 1013-1030 [PMID: 32778004 DOI: 10.1177/2050640620950093]
- 3 **Venkatesh PG**, Navaneethan U, Shen B. Hepatobiliary disorders and complications of inflammatory bowel disease. *J Dig Dis* 2011; **12**: 245-256 [PMID: 21791019 DOI: 10.1111/j.1751-2980.2011.00511.x]
- 4 **Yarur AJ**, Czul F, Levy C. Hepatobiliary manifestations of inflammatory bowel disease. *Inflamm Bowel Dis* 2014; **20**: 1655-1667 [PMID: 24874461 DOI: 10.1097/MIB.0000000000000065]
- 5 **Navaneethan U**. Hepatobiliary manifestations of ulcerative colitis: an example of gut-liver crosstalk. *Gastroenterol Rep (Oxf)* 2014; **2**: 193-200 [PMID: 24951514 DOI: 10.1093/gastro/gou036]
- 6 **Lepistö A**, Kivistö S, Kivisaari L, Arola J, Järvinen HJ. Primary sclerosing cholangitis: outcome of patients undergoing restorative proctocolectomy for ulcerative colitis. *Int J Colorectal Dis* 2009; **24**: 1169-1174 [PMID: 19636573 DOI: 10.1007/s00384-009-0773-4]
- 7 **Cangemi JR**, Wiesner RH, Beaver SJ, Ludwig J, MacCarty RL, Dozois RR, Zinsmeister AR, LaRusso NF. Effect of proctocolectomy for chronic ulcerative colitis on the natural history of primary sclerosing cholangitis. *Gastroenterology* 1989; **96**: 790-794 [PMID: 2914641]
- 8 **Gotthardt DN**, Sauer P, Schaible A, Stern J, Stiehl A, Beuers U. Kinetics of primary bile acids in patients after proctocolectomy and ileal pouch-anal anastomosis. *Digestion* 2014; **90**: 27-32 [PMID: 25139081 DOI: 10.1159/000362403]

- 9 **Sandborn WJ**, Landers CJ, Tremaine WJ, Targan SR. Association of antineutrophil cytoplasmic antibodies with resistance to treatment of left-sided ulcerative colitis: results of a pilot study. *Mayo Clin Proc* 1996; **71**: 431-436 [PMID: [8628021](#) DOI: [10.4065/71.5.431](#)]
- 10 **Macsween R N M**. Liver pathology associated with diseases of other organs. Pathology of the liver. Churchill Livingstone Inc.1987. Available from: <https://cir.nii.ac.jp/crid/1571135650655409792>
- 11 **Spinelli A**, Bonovas S, Burisch J, Kucharzik T, Adamina M, Annese V, Bachmann O, Bettenworth D, Chaparro M, Czuber-Dochan W, Eder P, Ellul P, Fidalgo C, Fiorino G, Gionchetti P, Gisbert JP, Gordon H, Hedin C, Holubar S, Iacucci M, Karmiris K, Katsanos K, Kopylov U, Lakatos PL, Lytras T, Lyutakov I, Noor N, Pellino G, Piovani D, Savarino E, Selvaggi F, Verstockt B, Doherty G, Raine T, Panis Y. ECCO Guidelines on Therapeutics in Ulcerative Colitis: Surgical Treatment. *J Crohns Colitis* 2022; **16**: 179-189 [PMID: [34635910](#) DOI: [10.1093/ecco-jcc/jjab177](#)]
- 12 **Fousekis FS**, Theopistos VI, Mitselos IV, Skamnelos A, Kavvadias A, Katsanos KH, Christodoulou DK. Specific Features of Patients With Inflammatory Bowel Disease and Primary Sclerosing Cholangitis. *J Clin Med Res* 2019; **11**: 81-88 [PMID: [30700999](#) DOI: [10.14740/jocmr3680](#)]
- 13 **European Association for the Study of the Liver**. EASL Clinical Practice Guidelines: The diagnosis and management of patients with primary biliary cholangitis. *J Hepatol* 2017; **67**: 145-172 [PMID: [28427765](#) DOI: [10.1016/j.jhep.2017.03.022](#)]
- 14 **Chalasani N**, Younossi Z, Lavine JE, Diehl AM, Brunt EM, Cusi K, Charlton M, Sanyal AJ. The diagnosis and management of non-alcoholic fatty liver disease: practice Guideline by the American Association for the Study of Liver Diseases, American College of Gastroenterology, and the American Gastroenterological Association. *Hepatology* 2012; **55**: 2005-2023 [PMID: [22488764](#) DOI: [10.1002/hep.25762](#)]
- 15 **Hernaez R**, Lazo M, Bonekamp S, Kamel I, Brancati FL, Guallar E, Clark JM. Diagnostic accuracy and reliability of ultrasonography for the detection of fatty liver: a meta-analysis. *Hepatology* 2011; **54**: 1082-1090 [PMID: [21618575](#) DOI: [10.1002/hep.24452](#)]
- 16 **Tiniakos DG**. Nonalcoholic fatty liver disease/nonalcoholic steatohepatitis: histological diagnostic criteria and scoring systems. *Eur J Gastroenterol Hepatol* 2010; **22**: 643-650 [PMID: [19478676](#) DOI: [10.1097/MEG.0b013e32832ca0cb](#)]
- 17 **Mieli-Vergani G**, Vergani D, Czaja AJ, Manns MP, Krawitt EL, Vierling JM, Lohse AW, Montano-Loza AJ. Autoimmune hepatitis. *Nat Rev Dis Primers* 2018; **4**: 18017 [PMID: [29644994](#) DOI: [10.1038/nrdp.2018.17](#)]
- 18 **Bollegala N**, Khan R, Scaffidi MA, Al-Mazroui A, Tessolini J, Showler A, Colak E, Grover SC. Aseptic Abscesses and Inflammatory Bowel Disease: Two Cases and Review of Literature. *Can J Gastroenterol Hepatol* 2017; **2017**: 5124354 [PMID: [28265555](#) DOI: [10.1155/2017/5124354](#)]
- 19 **Stanciulea O**, Eftimie MA, Mosteanu I, Ciortan R, Popescu I. Laparoscopic Restorative Proctocolectomy for Ulcerative Colitis - How I Do It? *Chirurgia (Bucur)* 2022; **117**: 328-340 [PMID: [35792543](#) DOI: [10.21614/chirurgia.2743](#)]
- 20 **Shah A**, Macdonald GA, Morrison M, Holtmann G. Targeting the Gut Microbiome as a Treatment for Primary Sclerosing Cholangitis: A Conceptual Framework. *Am J Gastroenterol* 2020; **115**: 814-822 [PMID: [32250997](#) DOI: [10.14309/ajg.0000000000000604](#)]
- 21 **Worthington J**, Cullen S, Chapman R. Immunopathogenesis of primary sclerosing cholangitis. *Clin Rev Allergy Immunol* 2005; **28**: 93-103 [PMID: [15879616](#) DOI: [10.1385/CRIAI:28:2:093](#)]
- 22 **Devkota S**, Wang Y, Musch MW, Leone V, Fehlner-Peach H, Nadimpalli A, Antonopoulos DA, Jabri B, Chang EB. Dietary-fat-induced taurocholic acid promotes pathobiont expansion and colitis in IL10^{-/-} mice. *Nature* 2012; **487**: 104-108 [PMID: [22722865](#) DOI: [10.1038/nature11225](#)]
- 23 **Aoki CA**, Bowlus CL, Gershwin ME. The immunobiology of primary sclerosing cholangitis. *Autoimmun Rev* 2005; **4**: 137-143 [PMID: [15823499](#) DOI: [10.1016/j.autrev.2004.09.003](#)]
- 24 **Eksteen B**, Grant AJ, Miles A, Curbishley SM, Lalor PF, Hübscher SG, Briskin M, Salmon M, Adams DH. Hepatic endothelial CCL25 mediates the recruitment of CCR9⁺ gut-homing lymphocytes to the liver in primary sclerosing cholangitis. *J Exp Med* 2004; **200**: 1511-1517 [PMID: [15557349](#) DOI: [10.1084/jem.20041035](#)]
- 25 **Adams DH**, Eksteen B. Aberrant homing of mucosal T cells and extra-intestinal manifestations of inflammatory bowel disease. *Nat Rev Immunol* 2006; **6**: 244-251 [PMID: [16498453](#) DOI: [10.1038/nri1784](#)]
- 26 **Liaskou E**, Karikoski M, Reynolds GM, Lalor PF, Weston CJ, Pullen N, Salmi M, Jalkanen S, Adams DH. Regulation of mucosal addressin cell adhesion molecule 1 expression in human and mice by vascular adhesion protein 1 amine oxidase activity. *Hepatology* 2011; **53**: 661-672 [PMID: [21225644](#) DOI: [10.1002/hep.24085](#)]
- 27 **Olsson R**, Boberg KM, de Muckadell OS, Lindgren S, Hultcrantz R, Folvik G, Bell H, Gangsøy-Kristiansen M, Matre J, Rydning A, Wikman O, Danielsson A, Sandberg-Gertzén H, Ung KA, Eriksson A, Lööf L, Prytz H, Marschall HU, Broomé U. High-dose ursodeoxycholic acid in primary sclerosing cholangitis: a 5-year multicenter, randomized, controlled study. *Gastroenterology* 2005; **129**: 1464-1472 [PMID: [16285948](#) DOI: [10.1053/j.gastro.2005.08.017](#)]
- 28 **Cullen SN**, Rust C, Fleming K, Edwards C, Beuers U, Chapman RW. High dose ursodeoxycholic acid for the treatment of primary sclerosing cholangitis is safe and effective. *J Hepatol* 2008; **48**: 792-800 [PMID: [18314215](#) DOI: [10.1016/j.jhep.2007.12.023](#)]
- 29 **Al Mamari S**, Djordjevic J, Halliday JS, Chapman RW. Improvement of serum alkaline phosphatase to <1.5 upper limit of normal predicts better outcome and reduced risk of cholangiocarcinoma in primary sclerosing cholangitis. *J Hepatol* 2013; **58**: 329-334 [PMID: [23085647](#) DOI: [10.1016/j.jhep.2012.10.013](#)]
- 30 **Harnois DM**, Angulo P, Jorgensen RA, Larusso NF, Lindor KD. High-dose ursodeoxycholic acid as a therapy for patients with primary sclerosing cholangitis. *Am J Gastroenterol* 2001; **96**: 1558-1562 [PMID: [11374699](#) DOI: [10.1111/j.1572-0241.2001.03777.x](#)]
- 31 **Shen B**, Bennett AE, Navaneethan U, Lian L, Shao Z, Kiran RP, Fazio VW, Remzi FH. Primary sclerosing cholangitis is associated with endoscopic and histologic inflammation of the distal afferent limb in patients with ileal pouch-anal anastomosis. *Inflamm Bowel Dis* 2011; **17**: 1890-1900 [PMID: [21830267](#) DOI: [10.1002/ibd.21594](#)]
- 32 **Treeparsertsuk S**, Björnsson E, Sinakos E, Weeding E, Lindor KD. Outcome of patients with primary sclerosing cholangitis and ulcerative colitis undergoing colectomy. *World J Gastrointest Pharmacol Ther* 2013; **4**: 61-68 [PMID: [23919218](#) DOI: [10.4292/wjgpt.v4.i3.61](#)]
- 33 **Kuisma J**, Nuutinen H, Luukkonen P, Järvinen H, Kahri A, Färkkilä M. Long term metabolic consequences of ileal pouch-

- anal anastomosis for ulcerative colitis. *Am J Gastroenterol* 2001; **96**: 3110-3116 [PMID: [11721757](#) DOI: [10.1111/j.1572-0241.2001.05256.x](#)]
- 34 **Damião AO**, Sipahi AM, Vezozzo DP, Gonçalves AL, Habr-Gama A, Teixeira MG, Fukushima JT, Laudanna AA. Effects of colectomy on gallbladder motility in patients with ulcerative colitis. *Dig Dis Sci* 1997; **42**: 259-264 [PMID: [9052503](#) DOI: [10.1023/a:1018841213480](#)]
- 35 **Habeeb TAAM**, Kermansaravi M, Giménez ME, Manangi MN, Elghadban H, Abdelsalam SA, Metwalli AM, Baghdadi MA, Sarhan AA, Moursi AM, El-TaHER AK. Sleeve Gastrectomy and Cholecystectomy are Safe in Obese Patients with Asymptomatic Cholelithiasis. A Multicenter Randomized Trial. *World J Surg* 2022; **46**: 1721-1733 [PMID: [35397750](#) DOI: [10.1007/s00268-022-06557-2](#)]
- 36 **Eade MN**, Cooke WT, Brooke BN. Liver disease in ulcerative colitis. II. The long-term effect of colectomy. *Ann Intern Med* 1970; **72**: 489-497 [PMID: [5437631](#) DOI: [10.7326/0003-4819-72-4-489](#)]
- 37 **Broomé U**, Glaumann H, Hultcrantz R. Liver histology and follow up of 68 patients with ulcerative colitis and normal liver function tests. *Gut* 1990; **31**: 468-472 [PMID: [2338276](#) DOI: [10.1136/gut.31.4.468](#)]
- 38 **Matsumoto T**, Yamasaki S, Arakawa A, Abe K, Abe H, Kon K, Kobayashi S, Takasaki Y. Exposure to a high total dosage of glucocorticoids produces non-alcoholic steatohepatitis. *Pathol Int* 2007; **57**: 388-389 [PMID: [17539971](#) DOI: [10.1111/j.1440-1827.2007.02112.x](#)]
- 39 **Rojas-Feria M**, Castro M, Suárez E, Ampuero J, Romero-Gómez M. Hepatobiliary manifestations in inflammatory bowel disease: the gut, the drugs and the liver. *World J Gastroenterol* 2013; **19**: 7327-7340 [PMID: [24259964](#) DOI: [10.3748/wjg.v19.i42.7327](#)]
- 40 **Naymagon L**, Tremblay D, Zubizarreta N, Moshier E, Naymagon S, Mascarenhas J, Schiano T. The Natural History, Treatments, and Outcomes of Portal Vein Thrombosis in Patients With Inflammatory Bowel Disease. *Inflamm Bowel Dis* 2021; **27**: 215-223 [PMID: [32185400](#) DOI: [10.1093/ibd/izaa053](#)]
- 41 **Ball CG**, MacLean AR, Buie WD, Smith DF, Raber EL. Portal vein thrombi after ileal pouch-anal anastomosis: its incidence and association with pouchitis. *Surg Today* 2007; **37**: 552-557 [PMID: [17593473](#) DOI: [10.1007/s00595-006-3470-8](#)]
- 42 **Maconi G**, Bolzacchini E, Dell'Era A, Russo U, Ardizzone S, de Franchis R. Portal vein thrombosis in inflammatory bowel diseases: a single-center case series. *J Crohns Colitis* 2012; **6**: 362-367 [PMID: [22405175](#) DOI: [10.1016/j.crohns.2011.10.003](#)]
- 43 **Talbot RW**, Heppell J, Dozois RR, Beart RW Jr. Vascular complications of inflammatory bowel disease. *Mayo Clin Proc* 1986; **61**: 140-145 [PMID: [3080643](#) DOI: [10.1016/s0025-6196\(12\)65200-8](#)]
- 44 **Hirschfield GM**, Dyson JK, Alexander GJM, Chapman MH, Collier J, Hübscher S, Patanwala I, Pereira SP, Thain C, Thorburn D, Tiniakos D, Walmsley M, Webster G, Jones DEJ. The British Society of Gastroenterology/UK-PBC primary biliary cholangitis treatment and management guidelines. *Gut* 2018; **67**: 1568-1594 [PMID: [29593060](#) DOI: [10.1136/gutjnl-2017-315259](#)]
- 45 **Hasan B**, Khalid R, Charles R, Shen B. Abdominal Pain in a Patient With Diverted Bowel and Inflammatory Bowel Disease. *ACG Case Rep J* 2020; **7**: e00437 [PMID: [32821767](#) DOI: [10.14309/crj.0000000000000437](#)]
- 46 **Floreani A**, Rizzotto ER, Ferrara F, Carderi I, Caroli D, Blasone L, Baldo V. Clinical course and outcome of autoimmune hepatitis/primary sclerosing cholangitis overlap syndrome. *Am J Gastroenterol* 2005; **100**: 1516-1522 [PMID: [15984974](#) DOI: [10.1111/j.1572-0241.2005.41841.x](#)]
- 47 **Epstein MP**, Kaplan MM. A pilot study of etanercept in the treatment of primary sclerosing cholangitis. *Dig Dis Sci* 2004; **49**: 1-4 [PMID: [14992426](#) DOI: [10.1023/b:ddas.0000011827.87103.2e](#)]



Published by **Baishideng Publishing Group Inc**
7041 Koll Center Parkway, Suite 160, Pleasanton, CA 94566, USA
Telephone: +1-925-3991568
E-mail: bpgoffice@wjgnet.com
Help Desk: <https://www.f6publishing.com/helpdesk>
<https://www.wjgnet.com>

