

THREE-DIMENSIONAL RETINAL DISPLACEMENT BEFORE AND AFTER MACULAR PUCKER SURGERY

TOMMASO ROSSI, MD,* GIORGIO QUERZOLI, PhD,† PAMELA COSIMI, MD,* GUIDO RIPANDELLI, MD,* LUCA PLACENTINO, MD,* DAVID H. STEEL, MD,‡ MARIO R. ROMANO, MD, PhD§

Purpose: To measure the coronal and sagittal retinal displacement before and after surgery for epiretinal membranes in InfraRed horizontal foveal sections and optical coherence tomography scans and describe displacement tridimensionality, vision loss, and metamorphopsia.

Methods: Retrospective series with greater than 6-month average follow-up before and after surgery. The record included best-corrected visual acuity, optical coherence tomography, M-charts, and InfraRed retinography. Overall, pre- and postoperative coronal and sagittal retinal displacement across the entire field, concentric circles at 0.5-, 1.5-, and 4.5-mm radii, and the central horizontal and vertical meridian were calculated as the optical flow of consecutive images.

Results: This study comprised 10 patients (4 men, 6 women), with 22.7 ± 25.2 months follow-up before surgery and 16.2 ± 7.3 months after. Best-corrected visual acuity reduced before surgery (0.15 ± 0.67 logarithm of minimum angle of resolution to 0.38 ± 0.85 logarithm of minimum angle of resolution; $P < 0.05$) and increased afterward (0.086 ± 0.61 logarithm of minimum angle of resolution; $P = 0.003$). Preoperative coronal displacement was $30.1 \pm 29.1 \mu\text{m}$ versus $67.0 \pm 23.4 \mu\text{m}$ after ($P = 0.002$). Sagittal retinal displacement was $140.9 \pm 84.6 \mu\text{m}$ before surgery, $339.7 \pm 172.5 \mu\text{m}$ after ($P = 0.017$), and $357.6 \pm 320.8 \mu\text{m}$ across the entire follow-up. Preoperative best-corrected visual acuity decreases correlated with the foveal coronal displacement. Vertical metamorphopsia correlated with the average coronal displacement within a 4.5-mm radius. Pre- and postoperative sagittal displacement correlated with horizontal metamorphopsia ($P = 0.006$ and $P = 0.026$). Postoperative sagittal displacement correlated with postoperative best-corrected visual acuity ($P = 0.026$) and foveal thickness ($P = 0.009$).

Conclusion: This study confirms that postoperative displacement is greater than preoperative and that sagittal displacement is greater than coronal and correlates with best-corrected visual acuity and metamorphopsia changes.

RETINA 44:1329–1336, 2024

Idiopathic epiretinal membranes (ERMs) form after incomplete detachment of the posterior vitreous when hyaloid remnants remain adherent to the retinal surface and cellular elements acquire contractile capabilities.¹ Epiretinal membranes may cause profound alterations of both the inner and outer retina² resulting in macular pucker requiring pars plana vitrectomy (PPV) with membrane peeling if visual acuity is significantly impaired.³

We recently calculated the tangential displacement of the retina (i.e., across the coronal plane), using a novel image analysis technique⁴ on InfraRed (IR) images taken before and after macular pucker surgery

and demonstrated that retinal coronal dislocation after surgery is indeed greater than before. We also found only an erratic association between coronal displacement, visual acuity, and metamorphopsia changes, in agreement with previous studies.^{5,6}

The purpose of this study is to add yet another tile to the mosaic, calculating the retinal displacement both on the coronal plane using IR images and on the sagittal plane analyzing structural optical coherence tomography (OCT) horizontal sections across the fovea. The rationale is to explore displacement tridimensionality and look for association with loss of vision and metamorphopsia.

Materials and Methods

Study Participants

We retrospectively analyzed all patients undergoing PPV and peeling for idiopathic ERM affecting the fovea and classified them as Stages 2 and 3 according to Govetto et al⁷ with documented pre- and postoperative follow-up greater than 6 months.

All patients received surgery at the IRCCS Bietti Foundation between June 2019 and January 2023 and were operated by a single surgeon. The diagnosis was confirmed by ophthalmoscopic examination and spectral-domain optical coherence tomography.

Exclusion criteria were as follows: 1) concomitant history of ocular and specifically macular disorders including age-related macular degeneration, retinal vascular occlusions, retinal detachment, trauma, ametropias exceeding $sf +1$ and $sf -3$ in spherical equivalent, and uveitis; 2) history of systemic diseases, including hypertension and diabetes; 3) poor imaging quality due to media opacity; 4) incomplete medical records.

All included patients underwent at least two comprehensive office visits including refraction, best corrected visual acuity (BCVA), biomicroscopy and indirect ophthalmoscopy. Visual acuity measurement used the Early Treatment Diabetic Retinopathy Study acuity charts and Snellen fraction was converted to the logarithm of the minimum angle of resolution (logMAR). The degree of horizontal and vertical metamorphopsia was assessed using M-charts (Inami, Co, Tokyo, Japan).⁸ All included patients underwent a complete visit at least 6 months before surgery and 1, 3, 6 months after surgery (± 7 days).

We defined as T-earliest (T_E) the very first available preoperative office visit, T_0 the visit immediately before surgery (within 7 days), and T-latest (T_L) the very last available postoperative visit. The number of patients whose data were available per time interval before and after surgery is reported in Table 1.

From the *IRCCS, Fondazione Bietti ONLUS, Roma, Italy; †DICAAR Faculty of Engineering, University of Cagliari, Cagliari, Italy; ‡Biosciences Institute, Newcastle University, Newcastle Upon Tyne, UK; and §Department of Biomedical Science, Humanitas University, Milan, Italy.

None of the authors has any financial/conflicting interests to disclose.

This is an open access article distributed under the terms of the Creative Commons Attribution-Non Commercial-No Derivatives License 4.0 (CCBY-NC-ND), where it is permissible to download and share the work provided it is properly cited. The work cannot be changed in any way or used commercially without permission from the journal.

Reprint requests: Tommaso Rossi, MD, Director of Ophthalmology, IRCCS Fondazione Bietti ONLUS, Via Livorno 3, Roma 00198, Italy; e-mail: tommaso.rossi@usa.net

All patients provided written informed consent, and this study adhered to the tenets of the Declaration of Helsinki and received approval from the local Ethics Committee (ERMLAB01 No. 77/18/FB).

Surgical Procedure

All patients underwent a standard 25-gauge 3-port PPV with combined phacoemulsification if phakic (using BVI R-Evolution CR800; BVI Medical Waltham, MA) with ERM and internal limiting membrane peeling with single Brilliant Blue G staining (Monoblue, BVI Medical Waltham).

Optical Coherence Tomography Image Acquisition

Spectral-domain OCT (Spectralis HRA-OCT, version 1.5.12.0; Heidelberg Engineering, Heidelberg, Germany) images were acquired using the horizontal spectral-domain optical coherence tomography cross-section (an average of 25–30 frames for each B-scan was used to improve image quality as elsewhere reported⁹). Only patients whose scans enabled the follow-up modality were included in this study to ensure the repeatability of scan location.

Coronal and Sagittal Displacement Measures

Coronal and sagittal distortion was measured by comparing the displacement occurring between couples of successive images as elsewhere described.⁴ This study compared T_E-T_0 representing the preoperative period, T_0-T_L (postoperative), and T_E-T_L for the entire course of the disease.

Coronal displacement measures used IR scanning laser ophthalmoscope scans obtained with an OCT machine during each visit, while sagittal displacement measures compared structural horizontal OCT scans obtained across the fovea in follow-up mode. The measurement procedure is based on the comparison of the local anatomical structures visible on couples of images using the Farneback motion estimation method as described in detail by Scarinci et al.⁴ The same procedure was used for the sagittal images but for the preprocessing procedure that, in this case, included the segmentation of the retinal layers, to exclude from the analysis the region below the retinal pigmented epithelium.

As a result of the image analysis, the two components (D_x , horizontal and D_y , vertical) of the displacement in the reference frame of the images are obtained in microns (as given by the OCT image scale) and the statistics such as mean values are computed using the magnitude of the displacement vectors $D = \sqrt{D_x^2 + D_y^2}$ included in the selected region of

Table 1. Number of Patients Available at Each Time Interval

<T-12	T-12	T-6	T0	T + 3	T + 6	T + 12	T + 18	>T + 18
8	9	10	10	10	10	10	9	7

interest. It should be noticed that since we obtained the displacements in the reference frame of the images, the “sagittal” displacements are not measured on a plane but on the retinal layer segmented by the OCT. For the same reason, in the structural scans, the third (“depth”) dimension is not locally orthogonal to the retinal surface but is rather oriented according to the y-axis of the image. Furthermore, some deviation from the ideal anatomic planes could be due to the posture of the patient during the scan.

Main Outcome Measures

Main study outcome measures included BCVA, M-charts grading, foveal thickness, and mean retinal displacement of IR en face and structural OCT images.

Statistical Analysis

The analysis of variance with *t*-test and *t*-test for repeated measures were used for numerical variables. Bivariate Pearson’s *r* correlation coefficient was applied for continuous variables, while Spearman’s rho and Kendall’s Tau were used for the assessment of ordinal variables such as ERM classification grades. Shapiro–Wilk test was employed for the Gaussian distribution of data.

In all cases, *P* values <0.05 were considered statistically significant.

Results

Visual Acuity, Foveal Thickness, and Metamorphopsia

Ten patients (four men and six women) satisfied the inclusion criteria; the mean age was comparable among the sexes: 72.1 ± 7.3 years for men and 68.1 ± 8.2 for women. Two patients were phakic before surgery and underwent a combined PPV and

phacoemulsification procedure with intraocular lens implantation.

The average preoperative follow-up was 22.7 ± 25.2 months (range 6–85 months), and the average postoperative follow-up was 16.2 ± 7.3 months (range 6–30 months).

Visual acuity (Table 2 and Figure 1) significantly reduced from T_E to T_0 (0.15 ± 0.67 logMAR [20/28 Snellen] to 0.38 ± 0.85 logMAR [20/47 Snellen]; $P < 0.05$) and increased from T_0 to T_L (0.086 ± 0.61 logMAR [20/24 Snellen]; $P = 0.003$).

The preoperative BCVA decrease between T_E and T_0 correlated with the coronal displacement within the central fovea (1.5 mm radius; $P = 0.039$) and the horizontal component of vertical crosshair line distortion ($P = 0.032$). The postoperative BCVA increase ($T_L - T_0$) correlated with the coronal displacement of the vertical component of the vertical crosshair line during the same period ($P = 0.001$).

Foveal thickness (Table 2 and Figure 1) slightly decreased throughout follow-up, but the difference between visits never reached statistical significance; however, preoperative foveal thickness changes ($T_E - T_0$) correlated with the coronal displacement of the vertical crosshair line vertical component during the same time frame ($P = 0.010$) and the postoperative foveal thickness decrease correlated with coronal displacement in the horizontal line of the crosshair region ($P = 0.049$).

Horizontal and vertical metamorphopsia increased significantly in the pre-operative period (between T_E and T_0). (Table 2 and Figure 2) while postoperative changes did not reach statistical significance ($T_0 - T_L$).

Horizontal metamorphopsia changes correlated with the vertical ones after surgery ($T_L - T_0$; $P = 0.002$) but not before. Vertical metamorphopsia correlated with the average retinal coronal displacement within a 4.5 radius between T_L and T_E ($P = 0.029$) but not with smaller radii.

Table 2. Main Clinical Outcome Measures: BCVA, Foveal Thickness, and Vertical and Horizontal Metamorphopsia

	T_E	T_0	<i>P</i> (T_E vs. T_0)	T_L	<i>P</i> (T_0 vs. T_L)
BCVA (logMAR)	0.17 ± 0.11	0.43 ± 0.22	<0.01	0.10 ± 0.16	0.003
OCT foveal thickness (μ)	427.6 ± 97	426.2 ± 111.4	0.91	395.0 ± 44.2	0.82
Horizontal metamorphopsia (°)	0.28 ± 0.18	1.11 ± 0.71	0.003	0.41 ± 0.39	0.36
Vertical metamorphopsia (°)	0.36 ± 0.19	1.18 ± 0.74	<0.01	0.84 ± 0.24	<0.001

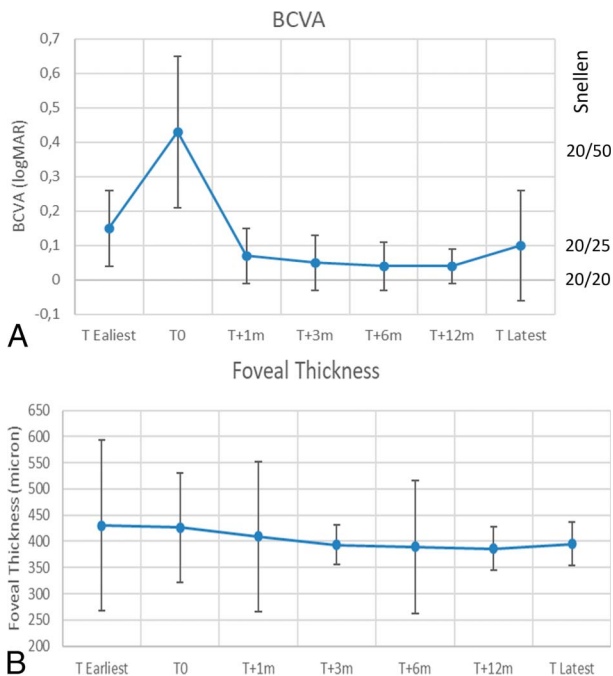


Fig. 1. Visual acuity (BCVA; top right; **A**) and foveal thickness (bottom right; **B**) during follow-up. Note the decrease between T_E-T₀ and subsequent recovery.

Coronal (En Face) Retinal Displacement

The average preoperative coronal (T₀-T_E) displacement across the entire 9 × 9-mm area was 30.1 ± 29.1 μm versus 67.0 ± 23.4 μm after surgery (T_L-T₀; P = 0.002). Pre- and postoperative displacement in the central 1.5-mm radius was similar, while for a 4.5-mm radius, the postoperative displacement was significantly greater (T₀-T_E: 19.8 ± 17.9 μm vs. T_L-T₀: 40.7 ± 11.6 μm; P = 0.017; Table 3).

Coronal displacement in the crosshair region where the M-charts project is also reported in Table 3.

There was a centrifugal gradient in coronal displacement: the 4.5-mm radius area showed a significantly higher displacement compared with the central 1.5 mm (Table 3) in the preoperative (T_E-T₀; P = 0.004), postoperative (T_L-T₀; P = 0.002), and entire follow-up (T_L-T_E; P > 0.001).

Interestingly, the coronal displacement occurring across the entire pre- and postoperative follow-up (T_L-T_E: 67.0 ± 11.1 μm; Table 3) represented the greatest linear dimension measured on the coronal plane throughout this study.

Retinal coronal displacement across the entire 9 × 9-mm IR photos highly correlated with the x component of the horizontal crosshair line in the preoperative (T_E-T₀; P < 0.001) and with the vertical component of the vertical crosshair line (P = 0.002).

Sagittal (In-Depth) Retinal Displacement

The average sagittal retinal displacement measured in OCT scans is reported in Table 4 and is significantly greater after surgery than before.

Interestingly, the average sagittal displacement was significantly greater than the corresponding coronal displacement of the horizontal crosshair line for each considered time frame (P < 0.001 for T₀-T_E and T_L-T₀; P = 0.01 for T_L-T_E).

Preoperative (T₀-T_E) and postoperative (T_L-T₀) sagittal displacement correlated with horizontal metamorphopsia changes through the same time frame (P = 0.006 and P = 0.026, respectively).

Postoperative (T_L-T₀) sagittal displacement correlated with postoperative BCVA changes (P = 0.026) while both postoperative (T_L-T₀) and overall (T_L-T_E) sagittal displacement correlated with OCT foveal thickness changes (P = 0.009 and P = 0.035, respectively).

Sagittal displacement also correlated with the coronal displacement along the crosshair horizontal and vertical lines (P = 0.029 and P = 0.034, respectively), the tangential displacement in the central 0.5 mm radius (P = 0.077), and the change in horizontal metamorphopsia in the preoperative (T₀-T_E; P = 0.046) and postoperative period (T_L-T₀; P = 0.034).

Discussion

Retinal displacement represents the hallmark of ERMs, and the surgical removal of epiretinal tissue

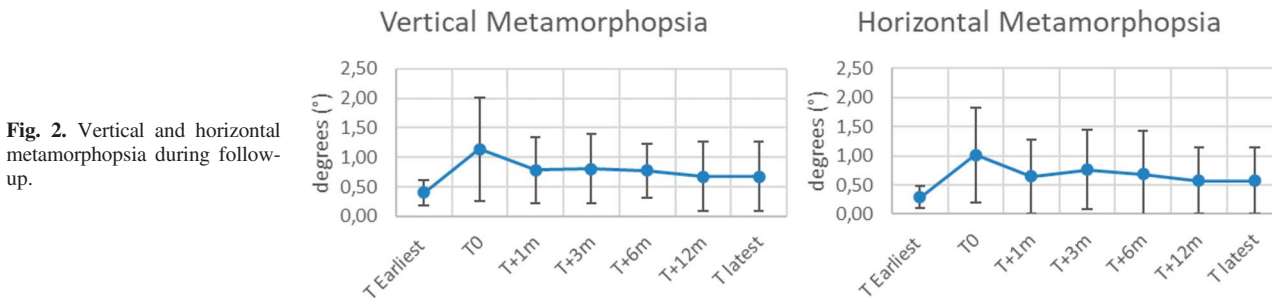


Fig. 2. Vertical and horizontal metamorphopsia during follow-up.

Table 3. Average Coronal Retinal Displacement Vector (in μm) of the Entire Considered Area and Concentric Circular Areas Centered on the Foveola of Increasing Radius

	T_0-T_E	T_L-T_0	<i>P</i>	T_L-T_E
Entire 9×9 mm field	30.1 ± 29.1	65.9 ± 18.8	0.020*	67.0 ± 23.4
$R < 0.5$ mm	14.4 ± 6.4	18.3 ± 14.0	0.378	13.5 ± 5.3
$R < 1.5$ mm	15.4 ± 10.2	22.7 ± 7.3	0.72	27.9 ± 11.5
$R < 4.5$ mm	19.8 ± 17.9	41.1 ± 11.5	0.017*	40.7 ± 11.6
Horizontal crosshair line	23.4 ± 14.4	46.3 ± 29.6	0.027*	51.2 ± 31.1
Vertical crosshair line	22.8 ± 13.3	47.0 ± 23.8	0.027*	45.9 ± 29.8

T_0 is immediately (<1 week) before surgery.

*Flags significant *P* values.

is the treatment of choice if vision decreases.¹⁰ The pathogenic mechanism is often and improperly simplified as a “contraction” of the “retinal surface” and the coronal (often and somehow improperly defined as “tangential” in clinical speech) component is regarded as the predominant feature, while ERMs indeed affect the entire retinal structure, and displacement occurs along all three axes as shown by en face¹¹ (coronal) and sagittal OCT imaging.¹² Artificial intelligence algorithms also found alterations in the inner perifoveal retina to be better predictors of visual impairment¹³ than surface indicators, and Li et al.¹⁴ found the amount of retinal surface undergoing thickening as the only significant predictor of visual impairment before surgery. A recent meta-analysis, however, found the integrity of EZ, interdigitation zones, and photoreceptor outer segment length as predictors of better visual outcomes after surgery.¹⁵

The effects of retinal displacement and resultant vascular pattern modifications¹⁶ interfere with axonal transport¹⁷ and affect all retinal layers and cells, including Muller,¹⁸ bipolar, astrocytes,¹⁹ ganglion,²⁰ and photoreceptors, thus explaining vision loss and metamorphopsia.

Although it is always impossible to pinpoint the exact “beginning” of a disease, our series spanned most if not all the pathological process with a lengthy follow-up before and after surgery and most likely included the most functionally significant part of disease development leading to visual loss and its restoration. All patients, in fact, had T_E visits at least six months before surgery was deemed necessary and an average BCVA of 20/28 (Table 2, Figure 1) at their first visit.

Interestingly, both coronal and sagittal postoperative displacement largely exceeded the preoperative (see Tables 3 and 4) confirming earlier findings.⁴ Even more importantly, the displacement vectors orientation across the posterior pole (9×9 mm image; Figures 3 and 4) and occurring between the latest and earliest visits (T_L-T_E) pointed in the most diverse directions.

The postoperative visual restoration and metamorphopsia reduction (Figure 1), reported in the literature²¹ and consistent with our series (Figure 2), do not correspond to restoration of the previous anatomical architecture since postoperative displacement exceeded the preoperative one and the mean difference in retinal displacement between the earliest and latest visits (T_L-T_E) was $67.0 \pm 23.4 \mu\text{m}$ on the coronal plane and $357.6 \pm 320.8 \mu\text{m}$ across the sagittal plane of the horizontal macular scan, respectively (Table 4). In other words, whatever pathological displacement occurred before surgery, causing visual loss and metamorphopsia, it did not reverse during the postoperative period which is by no means a “disease rewinding” process, despite functional improvement (see displacement vectors in Figures 3 and 4).

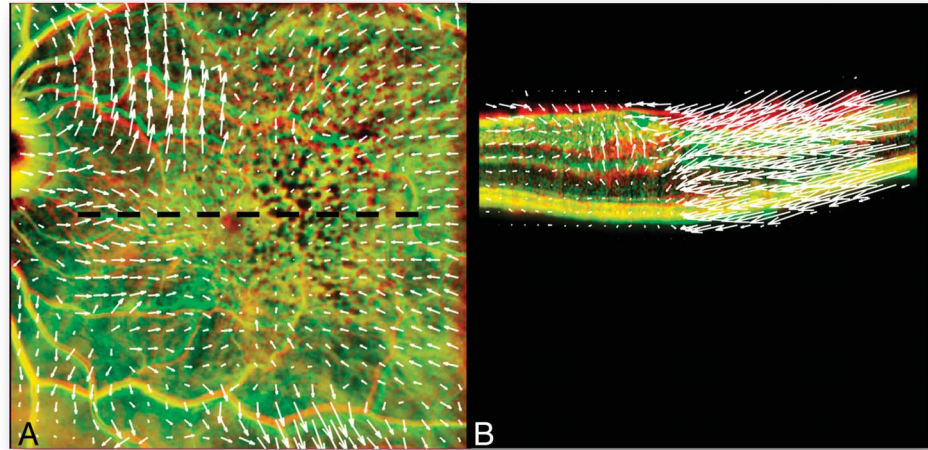
The coronal displacement surprisingly did not correlate with horizontal metamorphopsia, which instead correlated with the sagittal displacement across the horizontal macular OCT scan both in the preoperative (T_0-T_E ; $P = 0.046$) and postoperative period (T_L-T_0 ; $P = 0.034$). The reason could be related to the “flattening effect” of all retinal layers within IR images but is most likely due to the preferential displacement along the sagittal axis and/or the higher impact of such displacement on visual function. In addition, it should be noted that the algorithm detection capability in

Table 4. Average Sagittal Retinal Displacement Vector (in μm) Measured in OCT Horizontal Scan Transecting the Fovea Images

	T_0-T_E	T_L-T_0	<i>P</i>	T_L-T_E
Structural OCT	140.9 ± 84.6	339.7 ± 172.5	0.017	357.6 ± 320.8

T_0 is immediately (<1 week) before surgery.

Fig. 3. Pt 12 coronal (A) and sagittal (B) displacement vectors displaying the entire course of the disease from the earliest (−24 months) to the latest (+30 months) available visit (T_E – T_L). The sagittal OCT scan (B) is a horizontal foveal scan taken where the dashed black line is in (A). Vision in the same time frame returned close to pre-op values from 0.22 logMAR (20/33 Snellen) to 0.30 logMAR (20/40 Snellen).



sagittal OCT scan is higher, and therefore there is a higher density of vectors within the fovea and possibly more chances of achieving significance.

Our findings support the concept that ERMs should not be considered a retinal surface disease since the average sagittal dislocation was significantly higher than the coronal one at any time frame (see Results and Table 4). Such displacement also appeared to be functionally relevant as it correlated with postoperative BCVA changes and horizontal metamorphopsia both in the pre- and postoperative periods, unlike coronal displacement. The reason for such an apparent contradiction may reside as previously mentioned in the highest resolution of OCT images offering more data to the analysis but is most likely related to the stretching of cellular elements along the sagittal plane shown by OCT images and perpendicular (and therefore invisible) to the IR images plane (Figures 3, 5, and 6).

Interestingly, the coronal displacement showed a centrifugal gradient with more displacement occurring in the periphery (Table 3). This is likely due to the force exerted by the vascular arcades being the stiffest structure in the retina after ERM has been peeled, often together with the internal limiting membrane or with fragments of it. However, this behavior could also be attributed to an algorithm selection bias due to the preferential identification of “conspicuous points” representing vessels in IR images.

In summary, we applied matrix dislocation analysis to IR retinographies and OCT macular horizontal scans to measure the vector dislocation along the coronal and sagittal planes thus trying to compare them with functional indicators before PPV for ERM removal. Although we succeeded in demonstrating significant dislocation and meaningful correlations, predictors of visual behavior remain elusive and difficult to identify.




Fig. 4. Pt 14 coronal displacement between T_E (12 months before surgical indication was given) and T_L (48 months after surgery). Note the erratic direction of displacement vectors and their module (length of the arrow): they indicate quite a significant change in retinal topography after surgery and visual improvement from 20/50 (0.29 logMAR at T_E) dropping to 20/80 (0.60 logMAR at T_0) and improving to 20/25 (0.09 logMAR at T_L).

Key words: metamorphopsia, epiretinal membrane, macular pucker, retinal layer, retinal displacement.

Acknowledgments

The authors would like to thank the “Fondazione Roma” and the Italian Ministry of Health for financial support. The authors would also like to thank Giuliana Facciolo, Francesca Petruzzella, and Veronica Cherubini for patient study and data gathering.

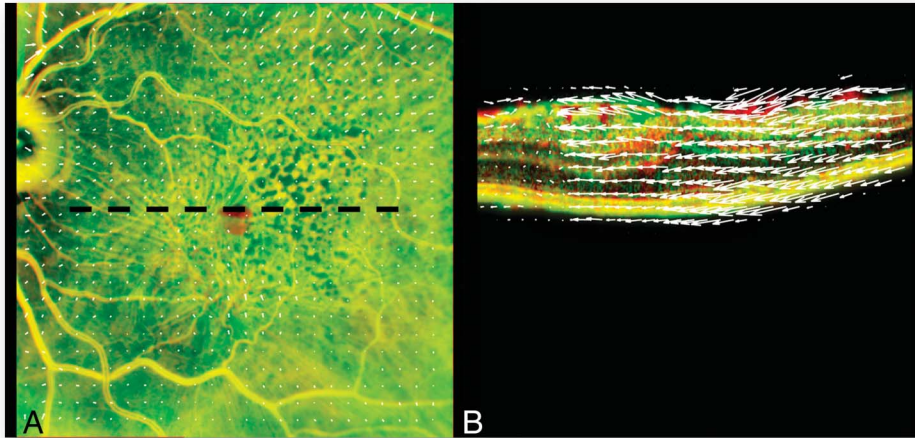


Fig. 5. Pt 12 tangential (A) and sagittal (B) displacement vectors between 24 months before surgery and surgery (T_E-T_0). The sagittal OCT scan (B) is a horizontal foveal scan taken where the dashed black line is in (A). Vision in the same time frame dropped from 0.22 logMAR (20/33 Snellen) to 0.30 logMAR (20/66 Snellen). Note the relative scarcity of tangential dislocation compared with sagittal.

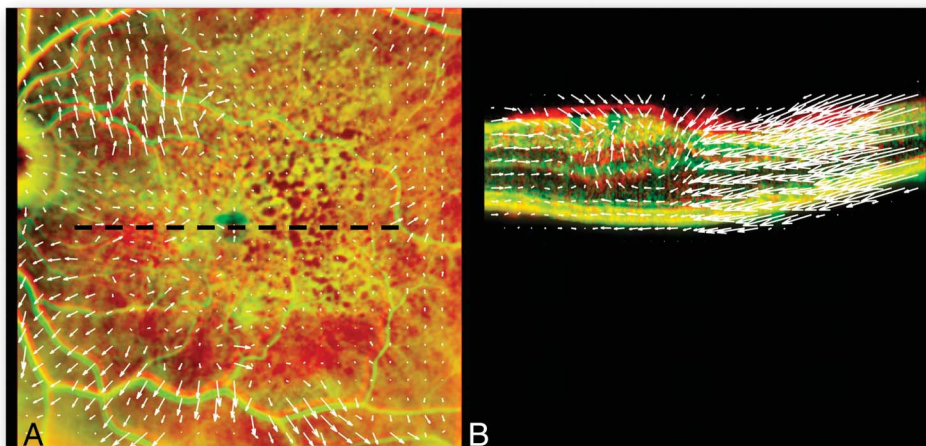


Fig. 6. Pt 12 coronal (A) and sagittal (B) displacement vectors between right before surgery and 30 months later (T_0-T_L). The sagittal OCT scan (B) is a horizontal foveal scan taken where the dashed black line is in (A). Vision in the same time frame increased from 0.52 logMAR (20/66 Snellen) to 0.30 logMAR (20/40 Snellen).

References

1. Simunovic MP. Metamorphopsia and its quantification. *Retina* 2015;35:1285–1291.
2. Romano MR, Cennamo G, Amoroso F, et al. Intraretinal changes in the presence of epiretinal traction. *Graefes Arch Clin Exp Ophthalmol* 2017;255:31–38.
3. Chang S, Gregory-Roberts EM, Park S, et al. Double peeling during vitrectomy for macular pucker: the Charles L. Schepens Lecture. *JAMA Ophthalmol* 2013;131:525–530.
4. Scarinci F, Querzoli G, Cosimi P, et al. Retinal tectonics after macular pucker surgery: thickness changes and en face displacement recovery. *Retina* 2024;44:102–110.
5. Ichikawa Y, Imamura Y, Ishida M. Inner nuclear layer thickness, a biomarker of metamorphopsia in epiretinal membrane, correlates with tangential retinal displacement. *Am J Ophthalmol* 2018;193:20–27.
6. Sakai D, Takagi S, Hirami Y, et al. Correlation between tangential distortion of the outer retinal layer and metamorphopsia in patients with epiretinal membrane. *Graefes Arch Clin Exp Ophthalmol* 2021;259:1751–1758.
7. Govetto A, Lalane RA III, Sarraf D, et al. Insights into epiretinal membranes: presence of ectopic inner foveal layers and a new optical coherence tomography staging scheme. *Am J Ophthalmol* 2017;175:99–113.
8. Arimura E, Matsumoto C, Nomoto H, et al. Correlations between M-CHARTS and PHP findings and subjective perception of metamorphopsia in patients with macular diseases. *Invest Ophthalmol Vis Sci* 2011;52:128–135.
9. Parravano M, De Geronimo D, Scarinci F, et al. Progression of diabetic microaneurysms according to the internal reflectivity on structural optical coherence tomography and visibility on optical coherence tomography angiography. *Am J Ophthalmol* 2019;198:8–16.
10. Fung AT, Galvin J, Tran T. Epiretinal membrane: a review. *Clin Exp Ophthalmol* 2021;49:289–308.
11. Matoba R, Kanzaki Y, Doi S, et al. Assessment of epiretinal membrane formation using en face optical coherence tomography after rhegmatogenous retinal detachment repair. *Graefes Arch Clin Exp Ophthalmol* 2021;259:2503–2512.
12. Bringmann A, Unterlauff JD, Barth T, et al. Foveal configurations with disappearance of the foveal pit in eyes with macular pucker: presumed role of Müller cells in the formation of foveal herniation. *Exp Eye Res* 2021;207:108604.
13. Hsia Y, Lin YY, Wang BS, et al. Prediction of visual impairment in epiretinal membrane and feature analysis: a deep learn-

- ing approach using optical coherence tomography. *Asia-Pac J Ophthalmol (Phila)* 2023;12:21–28.
14. Li DQ, Rudkin AK, Altomare F, et al. Predicting progression of untreated macular pucker using retinal surface en face optical coherence tomography. *Ophthalmologica* 2020;243:323–333.
 15. Patheja RS. Preoperative ocular coherence tomographic prognosticators of visual acuity after idiopathic epiretinal membrane surgery. *Int Ophthalmol* 2022;42:3243–3252.
 16. Lee EK, Kim HJ, Lee SY, et al. Retinal vessel geometry in patients with idiopathic epiretinal membrane. *Sci Rep* 2023;13:5108.
 17. Ryoo NK, Gu BH, Lee PY. Regression of axoplasmic stasis after Pars Plana vitrectomy with epiretinal membrane peeling. *JAMA Ophthalmol* 2019;137:e185991.
 18. Bringmann A, Wiedemann P. Involvement of Müller glial cells in epiretinal membrane formation. *Graefes Arch Clin Exp Ophthalmol* 2009;247:865–883.
 19. Bringmann A, Unterlauff JD, Barth T, et al. Müller cells and astrocytes in tractional macular disorders. *Prog Retin Eye Res* 2022;86:100977.
 20. Song SJ, Lee MY, Smiddy WE. Ganglion cell layer thickness and visual improvement after epiretinal membrane surgery. *Retina* 2016;36:305–310.
 21. Watanabe A, Ishida M, Shibata M, et al. One-year outcomes of metamorphopsia and retinal displacement after epiretinal membrane surgery. *Retina* 2022;42:1756–1761.