

## Petal-shaped corneal pattern in a patient with posterior amorphous corneal dystrophy

Massimiliano Borselli<sup>a</sup>, Costanza Rossi<sup>a</sup>, Adriano Carnevali<sup>a</sup>, Vincenzo Scordia<sup>a,\*</sup>,  
Giuseppe Giannaccare<sup>b</sup>

<sup>a</sup> Department of Ophthalmology, University Magna Graecia of Catanzaro, Catanzaro, Italy

<sup>b</sup> Eye Clinic, Department of Surgical Science, University of Cagliari, Cagliari, Italy

### ABSTRACT

**Purpose:** To describe the petal-shaped corneal pattern in a patient with posterior amorphous corneal dystrophy.

**Observation:** A 19-year-old male affected by Graves' disease presented corneal grey sheet-like opacities and high hyperopia. Corneal topography showed reduced k-values compatible with cornea plana and reduced corneal pachymetry. The anterior segment optical coherence tomography showed a hyperreflective band at the posterior stroma-Descemet-Endothelium layers in both eyes. Slit lamp examination with cobalt blue filter showed a corneal pattern resembling a petal in right eye; the pattern was similar but incomplete in left eye.

**Conclusion & importance:** After an exhaustive literature review conducted from October 1st to 30th, 2023, utilizing online databases like PubMed and Google Scholar, and employing keywords such as "Corneal Dystrophy," "Slit Lamp," "Cornea," and "Posterior Amorphous Corneal Dystrophy," we found no previous reports detailing the whole corneal pattern using a blue cobalt filter on the slit lamp in cases of posterior amorphous corneal dystrophy. Cobalt blue filter was an effective method for capturing the full photographic corneal pattern of the patient posterior amorphous corneal dystrophy.

### 1. Introduction

Corneal dystrophies constitute a group of rare inherited disorders characterized by bilaterality, symmetry, early onset and a slowly progressive course. They are often characterized by the deposition of various substances into the affected corneal layer(s), impacting refraction and vision.<sup>1</sup> According to the latest update from the International Committee for the Classification of Corneal Dystrophies (IC3D), these entities are categorized into four different types based on genetic, clinical, and histological characteristics: (i) epithelial and subepithelial dystrophies, (ii) epithelial-stromal TGFBI dystrophies, (iii) stromal dystrophies, and (iv) endothelial dystrophies.<sup>1</sup> Posterior Amorphous Corneal Dystrophy (PACD) is an autosomal dominant disease classified within the group of stromal dystrophies. It is associated with known gene deletions of keratocan (KERA), lumican (LUM), decorin (DCN) and epiphycan (EPYC) at the 12q21.33 locus.<sup>2</sup> Typically, it is diagnosed in the first decade of life in children exhibiting other systemic disorders with non-established correlations. High hyperopia has been observed, and visual acuity is generally 20/40 or better.<sup>1</sup> Slit lamp examination reveals grey sheet-like stromal opacities extending to the limbus with interspersed areas of clear cornea.<sup>3</sup> Two distinct types have been described: i) a centropetal form with entire corneal involvement

extending to the limbus, associated with higher hyperopia; ii) a peripheral form characterized by a lower grade of hyperopia.<sup>4</sup> Stromal breaks with involvement of the Descemet complex may be present. Cases featuring corectopia, a prominent Schwalbe line, pupillary remnants, iris abnormalities and keratoglobus have been reported.<sup>5,6</sup> Corneal topography highlights a flat cornea (<41 diopters) and a reduced corneal thickness (<400 μm). In vivo confocal microscopy has revealed microfolds and hyperreflectivity in the posterior stroma. Extracellular colloidal iron staining has been observed in the posterior stroma with light microscopy.<sup>7,8</sup>

Due to the rarity of this condition, to date, there is limited data on the exact pattern of posterior stromal opacification. We describe herein a case of centropetal PACD that shows a novel corneal pattern resembling a petal.

### 2. Case report

A 19-year-old male was referred to our center for reduced visual acuity. Graves' disease (GD) was diagnosed 3 years before by the endocrinology unit staff. The levels of TSH receptor antibodies (TRAb) were found to be higher than 1.75 IU/L. On physical examination, patient had a height of 163 cm (5'4") and a weight of 59 kg (130 lbs),

\* Corresponding author. Department of Ophthalmology, University Magna Graecia of Catanzaro, Viale Europa, 88100, Catanzaro, Italy.

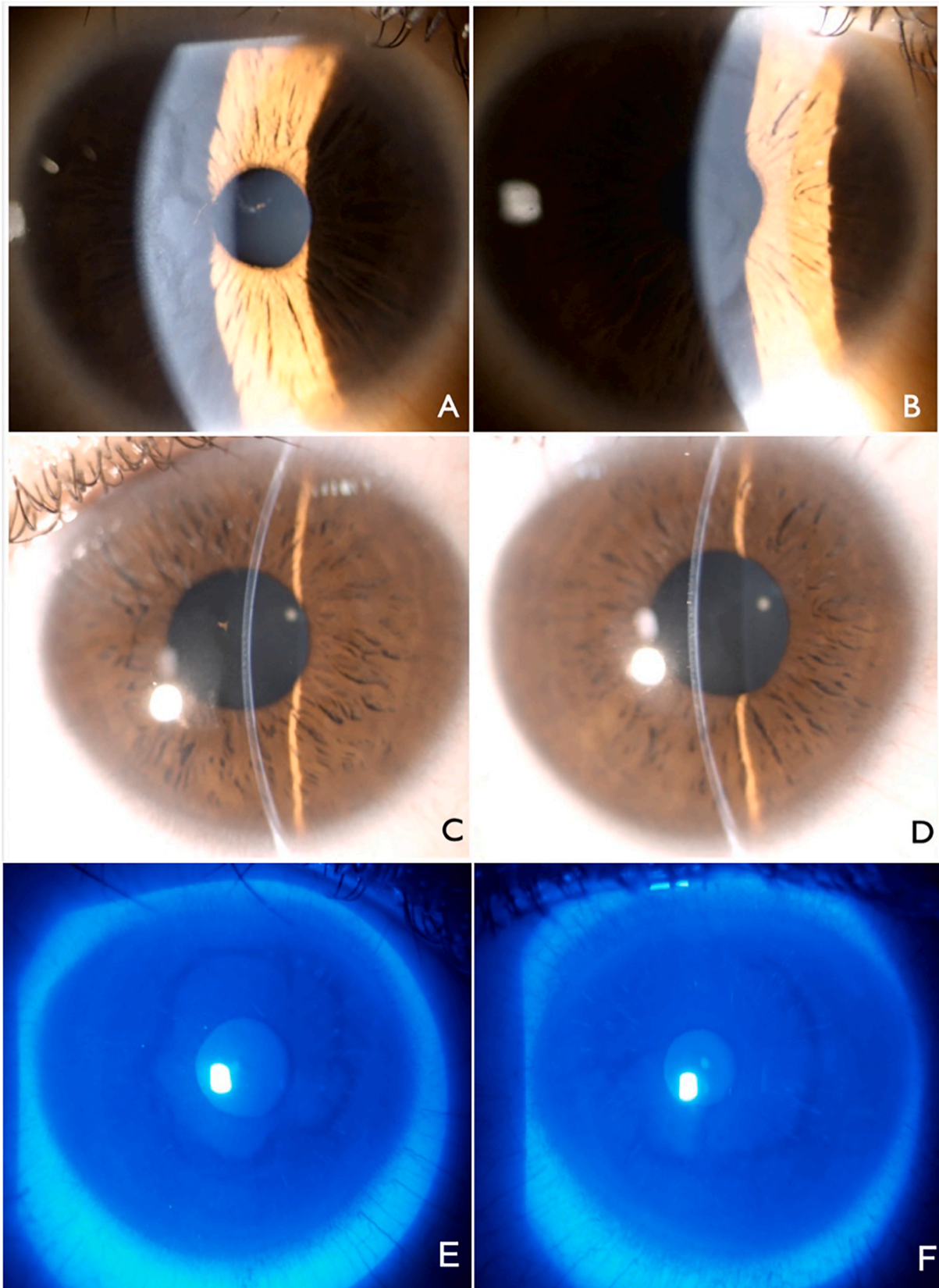
E-mail address: [vscordia@unicz.it](mailto:vscordia@unicz.it) (V. Scordia).

<https://doi.org/10.1016/j.ajoc.2024.102081>

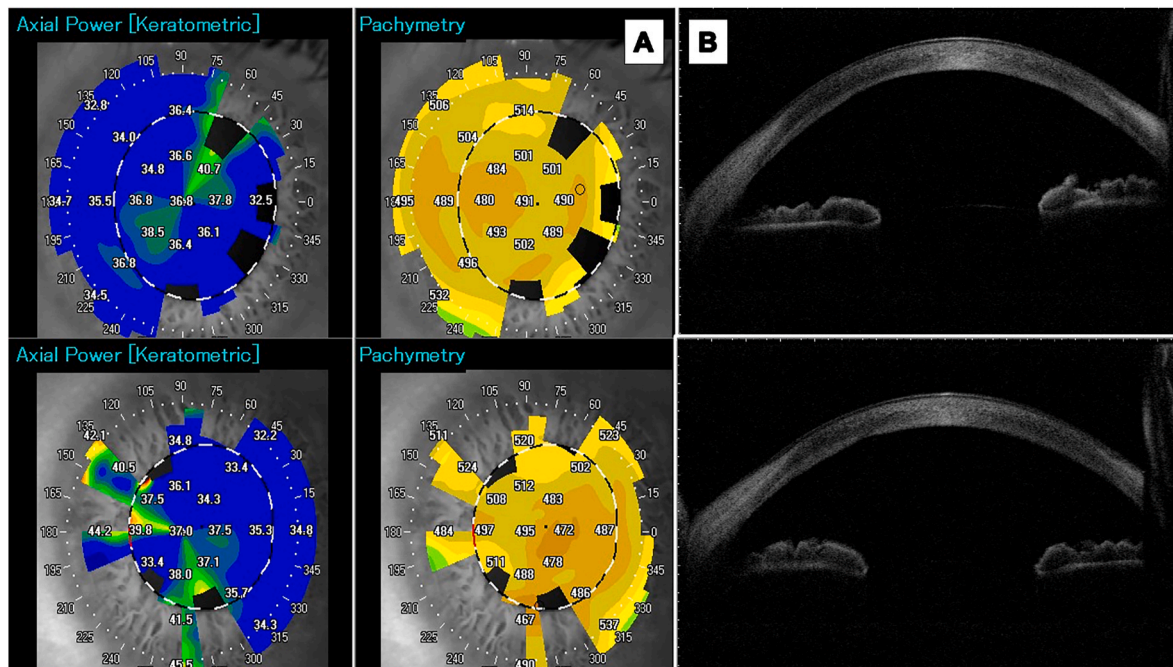
Received 2 November 2023; Received in revised form 22 April 2024; Accepted 3 May 2024

Available online 21 May 2024

2451-9936/© 2024 Published by Elsevier Inc. This is an open access article under the CC BY-NC-ND license (<http://creativecommons.org/licenses/by-nc-nd/4.0/>).



**Fig. 1.** Slit lamp examination of PACD. (A, B) Grey sheet-like opacities spaced by clear cornea areas (slit lamp: 5 mm wide light beam at 45°). (C, D) Hyperreflectivity of the posterior cornea layers (slit lamp: 0.2 mm wide light beam at 45°). (A, C) Small pupillary membrane remnant. (E, F) Slit lamp examination with cobalt blue filter showed a corneal pattern resembling a petal in RE; the pattern was similar but incomplete in LE. (For interpretation of the references to colour in this figure legend, the reader is referred to the Web version of this article.)



**Fig. 2.** (A) The corneal topography shows reduced k-values compatible with a cornea plana. In the lower part of the figure, the pachymetry maps show a corneal thinning with values less than 480  $\mu\text{m}$ . (B) The AS-OCT image shows a corneal section presenting an hyperreflective band at the posterior stroma-Descemet-Endothelium layers in OU.

without any other pathological signs. Family history revealed that the father suffered from high hyperopia with traces of white, deep-stromal corneal opacities. The patient does not have any siblings, and accurate data on previous generations were not available. Previous ophthalmological charts highlighted a history of contact lens wearing since the age of 5 when exoforia was diagnosed and treated with alternating occlusion. Corneal grey sheet-like opacities were also detected in both eyes (BE) for the first time. Absence of corneal iron deposit were noted. Best corrected visual acuity (BCVA) was 20/70 in the right eye (RE) and 20/40 in the left eye (LE) with a hyperopic correction. Slit lamp examination revealed grey sheet-like opacities spaced by clear cornea areas (Fig. 1A–B) and hyperreflectivity of the posterior cornea layers (Fig. 1C–D). A small pupillary membrane remnant was also present in the RE anterior chamber (Fig. 1A–C). The use of blue cobalt filter enhanced, in the paracentral zone, a continuous (RE) and incomplete (LE) ring of clear cornea surrounded by grey sheet-like opacities, organized in a petal-shaped corneal pattern in the patient's RE that was incomplete in his LE (Fig. 1E–F). The areas of the clear cornea highlighted with a blue cobalt filter corresponded to the conformation observed in diffuse illumination. Corneal topography (CASIA SS-1000 OCT, Tomey Corporation, Japan) showed a cornea plana (Kf = 35.1 D, Ks = 39.5 D in RE and Kf = 34.4 D, Ks = 39.7 D in LE). Pachymetry revealed corneal thinning (490  $\mu\text{m}$  in RE and 467  $\mu\text{m}$  in LE) (Fig. 2A). A hyperreflective band was visible in the inner stromal-Descemet-endothelium complex at the anterior segment optical coherence tomography (AS-OCT) scan (CASIA SS-1000 OCT, Tomey Corporation, Japan) (Fig. 2B). Axial length (AL) measured using IOL Master 700 (Carl Zeiss Meditec AG, Jena, Germany) was normal (23.15 mm in RE and 23.27 mm in LE). Noncontact specular microscopy (Cell Check, Konan Specular Microscope XVII, Japan) performed in the corneal areas without abnormalities showed a normal endothelial cell density (2340 cells/ $\text{mm}^2$  in RE and 2442 cells/ $\text{mm}^2$  in LE); conversely, the density was not measurable in the transition zones between clear and grey sheet-like cornea. Since no data concerning patient's relatives were available, the diagnosis of PACD was reached based on clinical findings only.

### 3. Discussion

PACD is a rare autosomal dominant inherited corneal dystrophy. The associated genetic mutations for this condition are located at Locus 12q21.33 and involve the deletion of genes: KERA, LUM, DCN, and EPYC.<sup>2</sup> Being a rare disorder, genetic diagnosis has historically been a primary focus of investigation. Yet, an exact description of corneal opacification is also lacking. Amorphous sheet-like opacifications in the posterior third of the corneal stroma have been first described in 1977 based on slit lamp examination,<sup>3</sup> as well as using in vivo confocal microscopy, ultrasound biomicroscopy and AS-OCT.<sup>8–11</sup> In a case, electron microscopy was used to assess the corneal tissue of a patient with PACD following penetrating keratoplasty. This examination revealed disorganization of collagen fibers in the posterior stroma, loss of endothelial cells, and disruption of the Descemet membrane.<sup>7</sup> GD is a targeted autoimmune condition that causes an excessive release of thyroid hormones, known as hyperthyroidism. While various conditions can lead to hyperthyroidism, GD is the predominant cause in Western nations, presenting an annual rate of 20 instances per 100,000 individuals.<sup>12</sup> One of the hallmark clinical features, beyond hyperthyroidism, is the ocular involvement, often referred to as Graves' ophthalmopathy or thyroid eye disease. Although GD disease and its ocular manifestations are well known, no correlation with any corneal dystrophy has been described.<sup>13,14</sup>

Over the years, PACD has been extensively researched to better understand its clinical and genetic features. Each researcher has contributed, adding a piece to the comprehensive understanding we have of this disease today (Table 1). After an exhaustive literature review conducted from October 1st to 30th, 2023, utilizing online databases like PubMed and Google Scholar, and employing keywords such as "Corneal Dystrophy," "Slit Lamp," "Cornea," and "Posterior Amorphous Corneal Dystrophy," we found no previous reports detailing the whole corneal pattern using a blue cobalt filter on the slit lamp in cases of posterior amorphous corneal dystrophy. In 1977, Carpel et al. presented a case series of 3 generations of relatives presenting at the slit lamp examination bilateral, large and amorphous sheet-like opacifications and corneal thinning. The progression over the generations indicated for an

**Table 1**

List of scientific papers published in the literature detailing the number of patients involved, along with all updates and new findings that have contributed to the current understanding of PACD.

Journal, Year	Author	Study Design	N° of patients	Findings
American Journal of Ophthalmology, 1977	Carpel E.F.	Case Series	10	<ul style="list-style-type: none"> <li>• Grey sheet-like corneal opacities and corneal thinning</li> </ul>
Archives of Ophthalmology, 1984	Dunn S.P.	Case Series	8	<ul style="list-style-type: none"> <li>•PACD features: iris abnormalities, prominent Schwalbe line and extension of the opacity to the limbus.</li> </ul>
Ophthalmology, 1990	Johnson A.T.	Case Report	1	<ul style="list-style-type: none"> <li>•Light microscopy: irregulates of the posterior stroma and focal attenuation of endothelial cells</li> <li>•Electron microscopy: disorganization in the collagen fibers in the posterior stromal</li> </ul>
Ophthalmology, 1990	N/A	Case Report	1	<ul style="list-style-type: none"> <li>•Penetrating Keratoplasty</li> </ul>
Cornea, 1992	Roth S.	Case Report	1	<ul style="list-style-type: none"> <li>•Suggesting that PACD is a general corneal condition instead of posterior stromal only, due to microscopy findings.</li> </ul>
American Journal of Ophthalmology, 1995	Bradford B.	Case Series	7	<ul style="list-style-type: none"> <li>•Suggest a more suitable classification among corneal dysgeneses rather than corneal dystrophies.</li> <li>•Cornea ectasia associated with 1 case of PACD.</li> </ul>
Ophthalmology, 1996	Moshegov C. N.	Case Series	9	<ul style="list-style-type: none"> <li>•Characterization of centrop peripheral and peripheral forms</li> </ul>
Cornea, 2002	Castelo Branco B.	Case Series	2	<ul style="list-style-type: none"> <li>•UBM: deep stromal linear opacities and superior corneal thinning</li> </ul>
Arquivos Brasileiros de Oftalmologia, 2006	Oliveira L.A.	Case Report	1	<ul style="list-style-type: none"> <li>•Confirmation of UBM findings</li> </ul>
Clinical & Experimental Ophthalmology, 2007	Erdem U.	Case Report	1	<ul style="list-style-type: none"> <li>•In vivo confocal microscopy: microfolds and hyper-reflective band at the posterior stroma-endothelium</li> </ul>
Investigative Ophthalmology & Visual Science, 2010	Aldave A.J.	Cross-sectional study	21	<ul style="list-style-type: none"> <li>•Linkage and haplotype analyses identified 12q21.33 as a locus for PACD</li> </ul>
PLoS One, 2014	Kim M.J.	Cross-sectional study	35	<ul style="list-style-type: none"> <li>•Array-based copy number analysis and qPCR: hemizygous deletion in the PACD linkage interval containing 4 genes encoding SLRPs: KERA, LUM, DCN, and EPYC. PACD is characterized by haploinsufficiency of SLRPs on chromosome 12.</li> </ul>
Ophthalmic Genetics, 2017	Odent S.	Case Report	1	<ul style="list-style-type: none"> <li>•Description of a PACD with de novo deletion of chromosome 12q21.33-q22</li> </ul>
Cornea, 2017	Fay J.	Case Report	1	<ul style="list-style-type: none"> <li>•Description of a case of PACD developing a bilateral Keratoglobus</li> </ul>
Ophthalmic Genetics, 2018	Cervantes A. E.	Case Series	3	<ul style="list-style-type: none"> <li>•Description of AS-OCT appearance</li> <li>• Confirmation of a heterozygous deletion of chromosome 12q21.33 as the cause of PACD.</li> <li>•Identification of the smallest deletion: 0.304-Mb</li> </ul>
Ophthalmic Genetics, 2018	Lenk J.	Case Report	1	<ul style="list-style-type: none"> <li>•Corroboration of the previous observations that PACD is a contiguous gene syndrome caused by combined haploinsufficiency of DCN, KERA, LUM, and EPYC.</li> <li>•The first example of a balanced chromosome rearrangement involving 12q21.33 in an unaffected parent.</li> </ul>
Ophthalmic Genetics, 2021	Yung M.	Case Series	2	<ul style="list-style-type: none"> <li>•Possible association of corneal ectasia with PACD. Being the genetic testing for PACD fails to reveal pathogenic deletions or mutations, other genetic factors could be possibly involved.</li> </ul>
Cornea, 2022	Basbus F.J.	Case Report	1	<ul style="list-style-type: none"> <li>•Confocal microscopy: enlarged keratocytes and small reflective deposits extending from the pre-Desemet line to the endothelium.</li> <li>•Identification of 447-kb deletion of the small leucine-rich proteoglycan-coding region at locus 12q21.33.</li> </ul>

autosomal dominant inheritance pattern.<sup>3</sup> In 1984, the main examination findings were enhanced in a group of 8 relatives spanned in 5 generation. Some features were found to be related to this condition, such as iris abnormalities, prominent Schwalbe line and extension of the opacity to the limbus.<sup>6</sup> In 1990, Johnson et al. described for the first time the findings of light microscopy and electron microscopy in the corneal lamellae of a PACD patient obtained after penetrating keratoplasty. Light microscopy showed irregulates and rupture of the posterior stroma of and focal attenuation of endothelial cells, while electron microscopy enhanced disorganization in the collagen fibers in the posterior stromal. Endothelial cells loss and Descemet membrane interruption were also present.<sup>7</sup> Penetrating keratoplasty was proposed as surgical treatment in a patient suffering from PACD.<sup>15</sup> An ultrastructural evaluation of the sample collected revealed subepithelial deposits, mild stromal abnormalities and a dense layer of collagen is located behind Descemet's membrane, indicating that this form of PACD is a general corneal condition encompassing both endothelial and epithelial irregularities.<sup>16</sup> In 1995, Bradford et al. described 7 cases exhibiting known signs of PACD, associated with iridocorneal adhesions, cornea plana and progressive corneal ectasia. According the authors, these findings suggested a more suitable classification among corneal dysgeneses rather than corneal dystrophies.<sup>17</sup> In 1996, two different forms of PACD, analyzing a family of 9 relatives, were characterized. The centrop peripheral form presented a whole corneal involvement up to the limbus associated with high

grade of hyperopia due to corneal flattening with less than 41 diopters. The less severe form, the peripheral one, showed only peripheral involvement and minor hyperopia, with more than 41 diopters but a similar central corneal thinning.<sup>4</sup> In 2002, the ultrasound biomicroscopy (UBM) findings showing deep stromal linear opacities and superior corneal thinning were described for the first time in two relatives<sup>18</sup> and later confirmed in 2006 in another case.<sup>11</sup> In 2007, one patient with PACD underwent in vivo confocal microscopy of the cornea showing microfolds and hyper-reflective band at the posterior stroma-endothelium.<sup>8</sup> In 2010, genome-wide analysis was performed in 21 patients affected by PACD and significant evidence of linkage to chromosome region 12q21.33 and 8q22.3 was provided. No coding region mutations were identified in *KERA*, *LUM*, *DCN*, and *EPYC*.<sup>19</sup> In 2014, Kim et al. analyzed 3 different families with overall 35 affected patients and discovered that small leucine-rich proteoglycans (SLRPs) gene has a role in maintaining cornea clarity and the PACD is characterized by haploinsufficiency of SLRPs on chromosome 12. Array-based copy number analysis and quantitative Polymerase Chain Reaction (qPCR) confirmed a hemizygous deletion in the PACD linkage interval containing 4 genes SLRPs: *KERA*, *LUM*, *DCN*, and *EPYC*.<sup>20</sup> Cases of PACD with de novo deletion were described for the first time in 2017.<sup>21</sup> In the same year, a case of confirmed PACD, with 15 years of follow-up, demonstrated a progressive development of bilateral keratoglobus-type corneal ectasia. Further analysis could highlight a possible correlation between these

two conditions involving the cornea.<sup>5</sup> In 2018, Lenk et al. reported a case involving a young patient with cryptorchidism, delayed psychomotor development and signs of PACD, who had an interstitial deletion of 1.3 Mb in 12q21.33. It has corroborated that PACD is a contiguous gene syndrome resulting from combined haploinsufficiency of the DCN, KERA, LUM, and EPYC genes. Interestingly, this study also presented the first instance of a balanced chromosome rearrangement in 12q21.33 found in an unaffected parent.<sup>9</sup> Cervantes et al. reported 3 cases of PACD in a family describing the appearance on AS-OCT with an evenly distributed posterior stromal hyperreflectivity across the cornea involving the posterior third of the stroma. Moreover, it has been reported that the 0.304-Mb deletion is the smallest identified to date.<sup>10</sup> In 2021, have been described 2 cases of likely PACD presenting concomitant corneal ectasia with steepening without a heterozygous deletion involving the PACD locus on chromosome 12.<sup>2</sup> Based on the most recent case of PACD described in the literature, confocal microscopy revealed enlarged keratocytes and small reflective deposits extending from the pre-Descemet line to the endothelium. Additionally, a 447-kb deletion encompassing the small leucine-rich proteoglycan-coding region at locus 12q21.33 was identified.<sup>22</sup> PACD is a rare condition that should be considered in young patients presenting grey sheet-like stromal opacities with K-related hyperopia. Interestingly, this condition was associated in our patients for the first time with GD. The cobalt blue filter was an effective method for capturing the full photographic pattern of the corneal of the patient PACD. To the best of our knowledge, this is the first description of a petal-shaped corneal pattern that was previously reported as amorphous.<sup>3</sup> Further research is imperative to elucidate a possible relationship between PACD and GD. Such inquiries might include exploring the genetic, immunological, and environmental factors contributing to the co-occurrence of these conditions, or examining the efficacy of different treatment approaches in patients presenting with both disorders. This line of inquiry not only aims to clarify the nature of the relationship between posterior amorphous corneal dystrophy and Graves' disease but also to enhance our understanding of their pathophysiology. Another aspect to investigate further is the density and morphology of the endothelial cells between the clear corneal areas and the areas of corneal opacities.

## Funding

No funding or grant support

## Patient consent

Written consent to publish this case report has been obtained from the patient.

## CRedit authorship contribution statement

**Massimiliano Borselli:** Writing – original draft, Validation, Methodology, Investigation, Formal analysis, Conceptualization. **Costanza Rossi:** Writing – original draft, Validation, Methodology, Formal analysis, Conceptualization. **Adriano Carnevali:** Writing – original draft, Visualization, Supervision, Project administration, Investigation, Data curation, Conceptualization. **Vincenzo Scoria:** Validation, Supervision, Investigation, Formal analysis, Data curation. **Giuseppe Giannaccare:** Visualization, Supervision, Project administration, Methodology, Data curation.

## Declaration of competing interest

The authors have no conflict of interest.

## Acknowledgements

None.

## References

- Weiss JS, Møller HU, Aldave AJ, et al. IC3D classification of corneal dystrophies—edition 2. *Cornea*. 2015 Feb;34(2):117–159. <https://doi.org/10.1097/ICO.0000000000000307>. Erratum in: *Cornea*. 2015 Oct;34(10):e32. Erratum in: *Cornea*. 2022 Dec 1;41(12):e23. PMID: 25564336.
- Yung M, Chen AC, Chung DD, et al. Corneal ectasia associated with posterior lamellar opacification. *Ophthalmic Genet*. 2021 Aug;42(4):486–492. <https://doi.org/10.1080/13816810.2021.1923034>. Epub 2021 May 18. PMID: 34003075.
- Carpel EF, Sigelman RJ, Doughman DJ. Posterior amorphous corneal dystrophy. *Am J Ophthalmol*. 1977 May;83(5):629–632. [https://doi.org/10.1016/0002-9394\(77\)90127-1](https://doi.org/10.1016/0002-9394(77)90127-1). PMID: 301356.
- Moshegov CN, Hoe WK, Wiffen SJ, Daya SM. Posterior amorphous corneal dystrophy. A new pedigree with phenotypic variation. *Ophthalmology*. 1996 Mar;103(3):474–478. [https://doi.org/10.1016/s0161-6420\(96\)30669-6](https://doi.org/10.1016/s0161-6420(96)30669-6). PMID: 8600425.
- Fay J, Herzlich AA, Florakis GJ. Posterior amorphous corneal dystrophy associated with keratoglobus: a case report. *Cornea*. 2017 Dec;36(12):1562–1566. <https://doi.org/10.1097/ICO.0000000000001304>. PMID: 28902010.
- Dunn SP, Krachmer JH, Ching SS. New findings in posterior amorphous corneal dystrophy. *Arch Ophthalmol*. 1984 Feb;102(2):236–239. <https://doi.org/10.1001/archoph.1984.01040030186023>. PMID: 6607727.
- Johnson AT, Folberg R, Vrabec MP, Florakis GJ, Stone EM, Krachmer JH. The pathology of posterior amorphous corneal dystrophy. *Ophthalmology*. 1990 Jan;97(1):104–109. [https://doi.org/10.1016/s0161-6420\(90\)32638-6](https://doi.org/10.1016/s0161-6420(90)32638-6). PMID: 2314832.
- Erdem U, Muftuoglu O, Hurmeric V. In vivo confocal microscopy findings in a patient with posterior amorphous corneal dystrophy. *Clin Exp Ophthalmol*. 2007 Jan-Feb;35(1):99–102. <https://doi.org/10.1111/j.1442-9071.2007.01426.x>. PMID: 17300585.
- Lenk J, Pormann J, Smitka M, et al. Posterior amorphous corneal dystrophy in a patient with 12q21.33 deletion. *Ophthalmic Genet*. 2018 Oct;39(5):645–647. <https://doi.org/10.1080/13816810.2018.1502792>. Epub 2018 Jul 30. PMID: 30058938.
- Cervantes AE, Gee KM, Whiting MF, Frausto RF, Aldave AJ. Confirmation and refinement of the heterozygous deletion of the small leucine-rich proteoglycans associated with posterior amorphous corneal dystrophy. *Ophthalmic Genet*. 2018 Aug;39(4):419–424. <https://doi.org/10.1080/13816810.2018.1459736>. Epub 2018 Apr 19. PMID: 29671669; PMCID: PMC6309915.
- Oliveira LA, Vieira LA, Freitas Dd, Sousa LB. Distrofia corneana amorfa posterior: relato de caso [Posterior amorphous corneal dystrophy: case report]. *Portuguese Arq Bras Oftalmol*. 2006 Nov-Dec;69(6):945–947. <https://doi.org/10.1590/s0004-27492006000600029>. PMID: 17273695.
- Antonelli A, Ferrari SM, Ragusa F, et al. Graves' disease: Epidemiology, genetic and environmental risk factors and viruses. *Best Pract Res Clin Endocrinol Metabol*. 2020 Jan;34(1), 101387. <https://doi.org/10.1016/j.beem.2020.101387>. Epub 2020 Feb 4. PMID: 32107168.
- Shah R, Amador C, Tormanen K, et al. Systemic diseases and the cornea. *Exp Eye Res*. 2021 Mar;204, 108455. <https://doi.org/10.1016/j.exer.2021.108455>. Epub 2021 Jan 21. PMID: 33485845; PMCID: PMC7946758.
- Hoang TD, Stocker DJ, Chou EL, Burch HB. 2022 update on clinical management of Graves disease and thyroid eye disease. *Endocrinol Metab Clin N Am*. 2022 Jun;51(2): 287–304. <https://doi.org/10.1016/j.ecl.2021.12.004>. Epub 2022 May 11. PMID: 35662442; PMCID: PMC9174594.
- No Authors listed. Penetrating keratoplasty in the management of posterior amorphous corneal dystrophy. *Ophthalmology*. 1990 Sep;97(9):1091–1092. [https://doi.org/10.1016/s0161-6420\(13\)38020-8](https://doi.org/10.1016/s0161-6420(13)38020-8). PMID: 2234837.
- Grimm Bradford B, Waring George O, Grimm Suzan B. Posterior amorphous corneal dysgenesis. *Am J Ophthalmol*. 1995;120(4):448–455. [https://doi.org/10.1016/S0002-9394\(14\)72658-3](https://doi.org/10.1016/S0002-9394(14)72658-3). ISSN 0002-9394.
- Roth SI, Mittelman D, Stock EL. Posterior amorphous corneal dystrophy: an ultrastructural study of a variant with histopathological features of an endothelial dystrophy. *Cornea*. March 1992;11(2):165–172.
- Castelo Branco B, Chalita MR, Casanova FH, Castelo Branco AB, Allemann N, de Freitas D. Posterior amorphous corneal dystrophy: ultrasound biomicroscopy findings in two cases. *Cornea*. 2002 Mar;21(2):220–222. <https://doi.org/10.1097/00003226-200203000-00020>. PMID: 11862100.
- Aldave AJ, Rosenwasser GO, Yellore VS, et al. Linkage of posterior amorphous corneal dystrophy to chromosome 12q21.33 and exclusion of coding region mutations in KERA, LUM, DCN, and EPYC. *Invest Ophthalmol Vis Sci*. 2010 Aug;51(8):4006–4012. <https://doi.org/10.1167/iovs.09-4067>. Epub 2010 Mar 31. PMID: 20357198; PMCID: PMC2910638.
- Kim MJ, Frausto RF, Rosenwasser GO, et al. Posterior amorphous corneal dystrophy is associated with a deletion of small leucine-rich proteoglycans on chromosome 12. *PLoS One*. 2014 Apr 23;9(4), e95037. <https://doi.org/10.1371/journal.pone.0095037>. PMID: 24759697; PMCID: PMC3997350.
- Odent S, Casteels I, Cassiman C, Dieltiens M, Hua MT, Devriendt K. Posterior amorphous corneal dystrophy caused by a de novo deletion. *Ophthalmic Genet*. 2017 Mar-Apr;38(2):167–170. <https://doi.org/10.3109/13816810.2016.1164194>. Epub 2016 Apr 20. PMID: 27096414.
- Basbus FJ, Cremona FA, Lucero Saá F, Chiaradía PA, Francipane L, Menazzi S. Posterior amorphous corneal dystrophy: new chromosomal breakpoints in the small leucine-rich proteoglycan-coding region. *Cornea*. 2022 Apr 1;41(4):491–495. <https://doi.org/10.1097/ICO.0000000000002961>. PMID: 35044970.