

SCHOLARLY REVIEW

Clinical management of external cervical resorption: A systematic review

Giulia Bardini DDS, PhD¹  | Cristiano Orrù DDS¹ | Francesca Ideo DDS¹ |
Venkateshbabu Nagendrababu BDS, MFDS RCS (Glasg), MDS, PhD² |
Paul Dummer BDS, MScD, PhD, DDSc, FDS RCS (Ed)³  | Elisabetta Cotti DDS, MS¹

¹Department of Conservative Dentistry and Endodontics, University of Cagliari, Cagliari, Italy

²Department of Preventive and Restorative Dentistry, College of Dental Medicine, University of Sharjah, Sharjah, UAE

³School of Dentistry, College of Biomedical and Life Sciences, Cardiff University, Cardiff, UK

Correspondence

Elisabetta Cotti, Department of Conservative Dentistry and Endodontics, University of Cagliari, Via Roma 149, Cagliari 09124, Sardinia, Italy.

Email: cottiendo@gmail.com

[Correction added on 25 September 2023, after first online publication: The affiliation of the author Dr Nagendrababu was amended and degrees of the co-authors Dr. Nagendrababu and Dr. Dummer were revised.]

Abstract

This review investigated whether any therapeutic options influenced the outcome of treatment for teeth with external cervical resorption. Out of 870 articles identified by an electronic search, 60 clinical case reports and six case series were included. No randomised clinical trials were found. Risk of bias was assessed using Joanna Briggs Institute's tools. External surgical intervention was the preferred method of accessing the lesions. Removal of resorptive tissue was most often achieved mechanically. Bioactive endodontic cements were the preferred materials for restoring teeth. The outcome measures were based on clinical and radiographic parameters. Of the cases included in the review, no specific treatment approach had a superior outcome in relation to Heithersay's classification. Furthermore, due to the absence of randomised clinical trials, and the low level of evidence associated with case reports/case series, it was not possible to define the optimum clinical treatment for external cervical resorption.

KEYWORDS

clinical approaches, external, invasive cervical resorption, invasive cervical resorption, management, review

INTRODUCTION

External cervical resorption (ECR) is an aggressive form of invasive root resorption at the enamel–cementum junction that if untreated leads to substantial loss of tooth tissue and eventually pulp, periodontal and periapical diseases that will ultimately lead to tooth loss [1–3]. The same resorptive process may also occur in the crown or other portions of roots [2].

ECR has been attributed to various predisposing factors, including trauma, orthodontic treatment, parafunctional habits, occlusal dysfunction, coronal bleaching, poor oral health, periodontal treatment, developmental and eruption disorders and viral infections [1, 4–7]. While the aetiology and pathogenesis of this process is not entirely understood, inflammation is a prerequisite for the initiation of resorption [8]. It has been hypothesised that ECR is initiated by the absence of or damage to the

[Correction added on 25 September 2023, after first online publication: The title of this article has been revised.]

This is an open access article under the terms of the [Creative Commons Attribution-NonCommercial-NoDerivs](https://creativecommons.org/licenses/by-nc-nd/4.0/) License, which permits use and distribution in any medium, provided the original work is properly cited, the use is non-commercial and no modifications or adaptations are made.

© 2023 The Authors. *Australian Endodontic Journal* published by John Wiley & Sons Australia, Ltd on behalf of Australian Society of Endodontology Inc.

external protective cementum layer located below the epithelial attachment at the cervical region of the tooth [9, 10]. This could occur due to a developmental gap in the cemento-enamel junction (CEJ) or following trauma to the pre-cementum [4, 5]. The unprotected dentine surface of the root is then susceptible to clastic cells, which initiate resorption and its progression [11]. ECR is a dynamic and progressive process during which the exposed dentine is invaded by clastic cells and progressively replaced by non-infective hyperplastic invasive fibrovascular tissue [1]. At the same time, apposition and remodelling of bone-like tissues can also occur [11–13], for this reason, the nature of ECR is considered not only to be destructive but also reparative [11]. The resorptive lesions have been reported to have one or several portals of entry into the dentine, while the dental pulp is ‘protected’ by the formation of a peri-canal resorption-resistant sheet (PRRS), consisting of odontoblastic and predentine layers that limit and delay the progression of the lesion towards the root canal [11, 12, 14]. In the later stages, the resorptive process reaches the pulp space, and pulpitis and ultimately pulp necrosis will occur if no treatment is initiated. Simultaneously, periodontal problems arise which may lead to tooth loss [1, 11, 14–16].

The clinical appearance of ECR ranges from resorptive defects at the gingival margin to pink coronal discoloration of the tooth. ECR is typically asymptomatic until pulpal or periodontal symptoms develop. Because of the lack of a pathognomonic clinical pattern, the definitive diagnosis of ECR depends on radiographic imaging [17]. The radiographic features of ECR vary from well-delineated to irregularly bordered mottled radiolucency [16, 18].

Heithersay [4] (H) introduced the first clinical classification for ECR consisting of four groups based on the location, size, proximity to the pulp chamber and degree of invasion into the root:

- Class 1 (H1), small cervical lesion with shallow penetration into the dentine;
- Class 2 (H2), well-defined lesion that has penetrated close to the pulp chamber, with little or no extension to radicular dentine;
- Class 3 (H3), lesion deeply extended to the coronal third of the root dentine; and.
- Class 4 (H4), large lesion extending beyond the coronal third of the root.

Following the introduction of cone-beam computed tomography (CBCT), Patel et al. [6] proposed a three-dimensional classification of ECR that significantly improves diagnostic accuracy and assists clinicians in assessing the treatment outcome [19]. This classification (P) is based on:

Height of the lesion (1 = supracrestal, 2 = subcrestal in the coronal third of the root, 3 = subcrestal in the middle third of the root, 4 = subcrestal in the apical third of the root);

Circumferential spread of the defect ($A = \leq 90^\circ$, $B = \leq 180^\circ$, $C = \leq 270^\circ$, $D = > 270^\circ$); and

Proximity of the lesion to the root canal (d = lesion confined to dentine, p = probable pulpal involvement).

Moreover, the authors suggested that additional elements related to the entry point of the lesion (i.e. accessibility, size and vertical extension along the root) should be considered during treatment planning [6].

A range of therapeutic options have been proposed for teeth with ECR [4, 20, 21]. The *European Society of Endodontology* Position Statement [7] listed several potential options ranging from external repair, internal repair, intentional replantation, periodic review and extraction, while a recent overview [22] discussed a list of treatment choices, comprising external repair, internal repair, palliative treatment and extraction. However, no standard protocol for the treatment of ECR has been proposed [23] and no formal and globally accepted guidelines have been developed that link the various therapeutic approaches to specific clinical situations involving ECR.

The treatment objectives focus on removing the resorbing ECR tissue, preventing its reoccurrence, retaining tooth structure and the restoration of the tooth to re-establish function and aesthetics [24].

It is generally accepted that the proper management of ECR is dependent on the patient's chief complaint [6], and on the accurate evaluation of the lesion, with treatment options based on the location and extent of the lesion and its accessibility [6, 23].

Currently, the prognosis of ECR lesions following treatment is supported by limited scientific evidence based on its classification [25, 26]. In 1999 the Heithersay benchmark paper [27] documented the first prospective extensive study of the management of ECR in 101 teeth using a standardised technique based on the four H classes, with a minimum follow-up of 3 years. It was concluded that the treatment regimen was successful in class 1 and 2 cases, reasonably successful in class 3 (77.8%) and mostly not successful in class 4 cases (12.5%). The outcome of ECR treatment, to date, has not been assessed in relation to local and treatment-related factors. Moreover, the *European Society of Endodontology* Position Statements identified limited evidence regarding ECR treatment outcomes, defining the ECR management options as *still experimental* [4, 7].

This review used a systematic approach to identify and investigate whether any therapeutic options influenced the outcome of restorative treatment of ECR lesions in a general population of patients, as the first step towards the

design of new prospective studies to provide definite treatment guidelines in the future.

MATERIALS AND METHODS

Protocol and registration

The protocol of this systematic review was registered in PROSPERO with the Centre for Reviews and Disseminations at the University of York under the code CRD42021225267. The review was reported according to the Preferred Reporting Items for Systematic Reviews and Meta-Analyses (PRISMA) guidelines [28].

Information sources, search and selection of the reports

A systematic electronic search was conducted in the PubMed Medline, Scopus and Web of Science databases independently by two reviewers (C.O. and G.B.), including articles published from inception to January 2023. Disagreements between the two reviewers were resolved by team discussion or by the help of third reviewer (E.C.). The search strategy comprised the following keywords coupled with Boolean operators to develop the following research algorithm: “cervical resorption” AND (“invasive” OR “external” OR “idiopathic”) AND (“treatment” OR “therapy” OR “management” OR “approach”). Additionally, a manual search of the reference lists of relevant reports was performed to identify additional eligible articles.

Research question

The research question was formulated in the following manner: ‘Does the choice of the external rather than internal and combined therapeutic approach influence the outcome of ECR, in a general population of patients, as a function of the clinical and/or radiographic criteria?’

The treatments chosen to manage ECR, once diagnosed, were considered the main outcomes. Consequently, to address the focused question (PICO) in detail this was divided into three sub-questions that were formulated as follows:

Among the approaches used to treat ECR, which one has shown the better outcome, in relation to the Heithersay classification?

Among the methods used to remove/inactivate the resorptive tissue, which one has shown the better outcome, in relation to the approach chosen, and the Heithersay classification?

Among the materials used to restore the access and repair the defect, which one has shown the better outcome, in relation to the approach chosen, and the Heithersay classification?

Selection criteria

The inclusion criteria were:

1. Clinical reports in humans with ECR that described the therapeutic management of the lesions in detail.
2. Clinical reports published in English.
3. Reports available in full text.
4. Clinical reports describing follow-ups and outcome measures, after a minimum period of 12 months.

The exclusion criteria were:

1. Reports examining tooth resorptions that were not ECR.
2. Reports that did not describe the therapeutic management of ECR.
3. Reports that did not specify the size and extensions of the resorptive defect, according to either the Heithersay or Patel classifications, and for which Heithersay’s classification could not be assigned by the reviewers.
4. Preclinical and laboratory reports.
5. Reports that did not have a minimum follow-up of 12 months.
6. Reports that did not describe the outcome assessment.

Selection of case reports/series

Two calibrated investigators (C.O. and G.B.) removed duplicates and evaluated the records. Upon assessing the title and the abstract, the investigators were calibrated for the inclusion criteria using the first 100 manuscripts obtained from the electronic search. The level of agreement was calculated using kappa statistics, and calibration exercises were performed until a good level of agreement was reached (k -value of 0.96 at the last examination). The titles and the abstracts were screened for subject relevance. All titles and abstracts for which exclusion criteria could not be clearly defined were selected for full-text reading. The full texts of the selected reports were read, and eligibility criteria were applied. For those articles that did not report any classification of the lesions, the reviewers assigned the Heithersay class to the respective cases, where possible. Disagreements were resolved by discussion, and when a consensus was not reached, a third reviewer (E.C.) was involved.

Data extraction

Reports satisfying the inclusion criteria were processed for data extraction. To better frame the aim of the study within the general context of specific clinical treatments, important background information was also obtained for each clinical report, including authors, year of publication, setting of the clinical treatment, characteristics of the patients and teeth treated and classification assigned when ECR was diagnosed. Within the description of the therapeutic approach chosen, the methods and the medicaments used to remove/inactivate the resorptive lesion and the materials used to restore the teeth were also recorded. Finally, follow-up, prognosis and outcomes were considered. Favourable outcome was described as the absence of symptoms and of radiological signs of no further progression of the resorption. Two Investigators (C.O. and G.B.) were involved in the data extraction, and conflicts were resolved by discussion; when a consensus was not achieved, a third reviewer (E.C.) was involved. To maximise the data available, Heithersay's classification was assigned by the authors in all the cases which were not classified (i.e. when the necessary information was available) and in those cases which used Patel's classification.

Quality assessment

The quality of the included reports was analysed by two reviewers independently (C.O. and G.B.) using the Joanna Briggs Institute case reports and case series appraisal checklist for inclusion in systematic reviews [29, 30]. In case of disagreements during quality assessment, a third reviewer (E.C.) provided a final decision. Quality appraisal checklists were used to elaborate a scoring system, where each item was scored as 0 if the item was not fulfilled, 0.5 if partially fulfilled, or 1 if the item was completely fulfilled. Publications with an overall score ≤ 3 were considered as 'low' quality, those with a score between 3 and 6 were classified as 'moderate' quality, while publications with a score ≥ 6.5 were considered as 'high' quality.

RESULTS

Selection of publications

The search yielded a total of 870 manuscripts. After removing duplicates, 425 articles were screened using the eligibility criteria. According to the inclusion criteria, 139 articles were eligible for full-text assessment. After reading, the full text 73 papers were excluded for

various reasons (Table S1) and 66 articles were included (Figure 1): 60 clinical case reports (CR) and six case series (CS); no randomised clinical trials were found.

Quality of the included case reports/series

The Quality of the included case reports and case series are presented in Tables S2 and S3, respectively. Among the 66 articles, 34 were classified as 'moderate' and 32 as 'high' quality.

Characteristics of the included case reports/series

Based on the distribution of the included reports over time, most were published between 2010 and 2022 (85%; Table 1). Information was obtained from 66 articles, which reported 95 teeth with ECR in 80 patients, who were almost always treated in university environments (94%), with only a few patients seen in military hospitals (1%) or private practices (5%). Cases were distributed similarly between men and women, with an average age of 33.51 years at the time of ECR diagnosis; however, it was not possible to obtain information on the ethnicity of the patients. Heithersay's (H) classification alone was the one used in the majority of reports (74%), [27], followed by the classification by Patel et al. (P) alone [6] (2%), or by merging both H and P (6%). Maxillary central incisors, mandibular molars, maxillary canines and maxillary lateral incisors were reported most often, followed by mandibular premolars and canines, maxillary molars, and, in a much lower percentage, maxillary premolars and mandibular central and lateral incisors (Table 1).

Outcomes

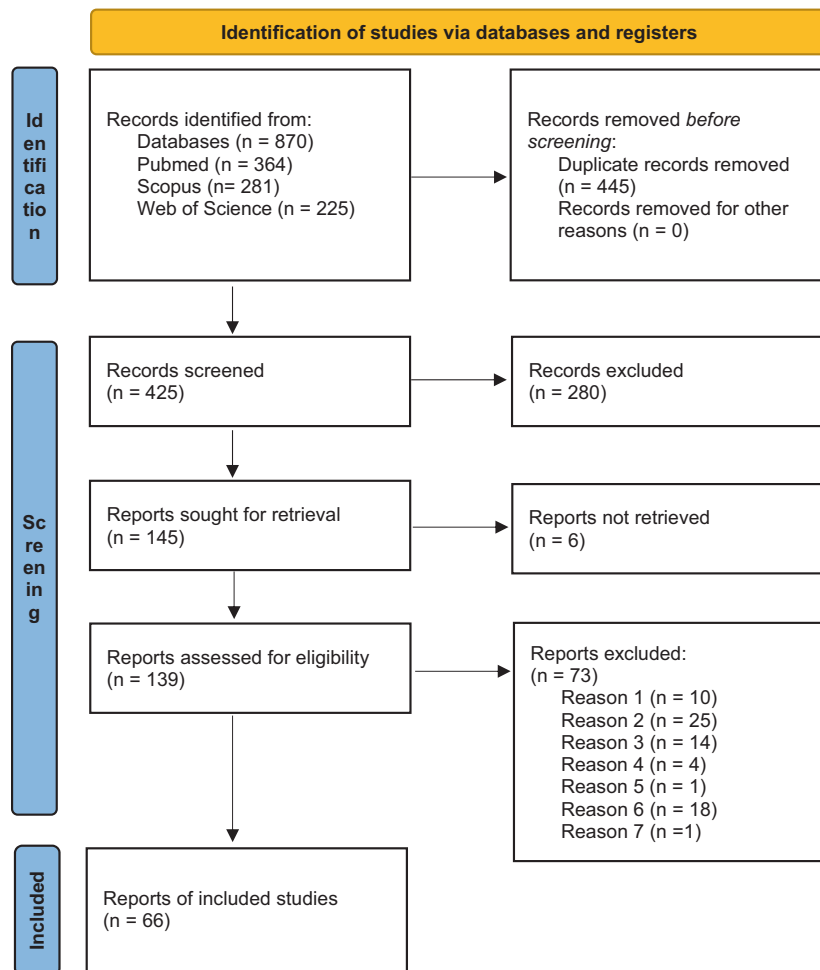
The outcome measures were based on the following clinical and radiographic criteria: physiological or stable periodontal probing depth in the area of the defect, absence of clinical signs indicating progression of the disease, reported in 86 cases (91%); absence of radiographic signs of the progression of the disease within the observed tooth, reported in 82 cases (86%), (Table 1).

Among the 95 cases/teeth treated there were 35 H2, 37 H3 and 23 H4, the recall periods were between 12 and 324 months, with an average of 36.38 months (Table 1).

Ninety-four teeth (99%) were functional and had no signs of progression of the disease at the recall, one case (H3) was extracted (Table 1) 180.5 months after its external surgical treatment due to vertical root fracture.

FIGURE 1 PRISMA flow diagram.

From: Page et al. [28]. For more information, visit: <http://www.prisma-statement.org/>.



Answer to the main question

Does the choice of the external rather than internal and combined therapeutic approach influence the outcome of ECR, in a general population of patients, as a function of the clinical and radiographic criteria?

External approaches to treat the lesions included non-surgical external access, the reflection of a surgical flap, orthodontic extrusion and intentional reimplantation.

An external access with a surgical flap was reported most frequently (61%), with a lower percentage of cases being treated using external non-surgical access (7%), orthodontic extrusion (7%) and intentional replantation (5%).

An internal approach, that is a non-surgical approach to access the resorptive tissue and its mechanical and/or chemical removal through root canal treatment [21], was documented in 34% of the treatments.

A combined approach, defined as the combination of internal and external (surgical and non-surgical) therapeutic access, was described in 5% of the reports.

Since 99% of the cases included in this review claimed a favourable outcome after a minimum follow-up of 12 months, no treatment approach was associated with a superior clinical and radiographic outcome.

Answers to the focused questions

Among the approaches used to treat ECR, which one has shown the better outcome, in relation to the Heithersay classification?

In H2 and H3 defects, the treatment reported most often was external surgical (58% and 60%, respectively), followed by internal (18% and 30%, respectively), whereas H4 lesions were mostly managed via an internal access (61%), followed by external surgical access (26%; Table S4).

Since 99% of the cases included in this review claimed a favourable outcome after a minimum follow-up of 12 months, no treatment approach was associated with a superior clinical and radiographic outcome, in relation to Heithersay's classification.

Among the methods used to remove/inactivate the resorptive tissue, which one has shown the better outcome, in relation to the approach chosen, and the Heithersay classification?

The techniques used to remove the pathologic tissue are shown in Table 1. Mechanical removal of the resorptive tissue with a bur, without complementary use of a chemical/medicament was reported most frequently

TABLE 1 Characteristics of the included studies, divided by the individual cases reported (in chronological order).

Authors	Patient	Age	Gender	Tooth	Classification	Treatment	
						Approach	Removal of resorption
Asgary, 2022 [75]	A	27	F	35	H: 4	Ext surg	EXC
Tavares et al., 2021 [59]	A	41	M	21	H: 4	Int + ext	EXC + PHTDYN
Bachesk et al., 2021 [76]	A	51	F	21	H: 2	Ext surg	EXC
Howait et al., 2021 [41]	A	26	F	15	H: 3 + P: 3Cp	Int	EXC + 2,5% NaOCl
Agrawal and Kapoor, 2020 [58]	A	35	F	11	H: 4	Int + ext	EXC + 90% TCA
Gión-Guerra et al., 2021 [77]	A	50	Ns	35	H: 2	Ext surg	EXC + CHX
	B	61	Ns	22	H: 2	Ext surg	EXC
	C	62	Ns	12	H: 2	Ext surg	EXC
Neto et al., 2020 [43]	A	21	M	46	H*: 2 + P: 2Ap	Int	EXC
Sarmiento et al., 2020 [62]	A	28	M	11	H*: 4	Int	Ca(OH) ₂ PT
Tonini et al., 2020 [40]	A	17	M	37	H: 3 + P: 3Dp	Int	EXC
	B	17	F	33	H: 3 + P: 2Bp	Ext surg	EXC
	C	12	F	12	H: 2 + P: 1 Bd	Ext surg	EXC
	D	52	F	33	H: 3 + P: 3Cp	Int	NS
Aljarbou, 2019 [78]	A	70	M	23	H: 3	Ext surg	EXC
Alqedairi, 2019 [79]	A	21	F	26	H: 3	Int	EXC + Ca(OH) ₂ PT
Asgary et al., 2019 [56]	A	45	F	36	H: 3	Int	EXC
	B	32	M	36	H: 2	Int	EXC
	C	29	F	17	H: 2	Int	EXC
	D	36	F	37	H: 3	Int	EXC
	E	27	F	46	H: 4	Int	EXC
	F	28	M	46	H: 4	Int	EXC
Ehlinger et al., 2019 [32]	A	15	F	21	H: 2	Ext surg	EXC
	B	27	F	23	H: 3	Int	EXC
	C	30	F	16	H: 4	Ext surg	EXC
	D	25	F	12	H: 4	Int	EXC
Krug et al., 2019 [42]	A	37	M	11	H*: 2 + 2Ap	Int rep	EXC
Espona et al., 2018 [23]	A	17	M	12	H: 2 + O: E	Ext: o + s	EXC + 90% TCA
	B	33	F	31	H: 4 + O: I	Int	EXC + Ca(OH) ₂
	C	32	F	11	O: N	Int rep	EXC + 90% TCA
Halboub et al., 2018 [64]	A	18	F	36	H: 3	Int	EXC + 6% NaOCl
Mehra et al., 2018 [80]	A	43	M	23	H: 3	Ext surg	EXC + 17% EDTA
Nagahara et al., 2018 [39]	A	68	F	36	H: 3 + P: 3Bp	Ext surg	EXC
	A	22	M	12	H: 4	Int	EXC
Eftekhar et al., 2017 [82]	A	51	F	33	H: 3	Ext surg	EXC + 90% TCA
Fernandes et al., 2017 [83]	A	21	F	12	H: 3	Ext surg	EXC + 90% TCA
Heithersay et al., 2017 [49]	A	38	F	12	H*: 2	Ex no sur	EXC + 90% TCA
Michelotto et al., 2017 [46]	A	31	F	14	H*: 3	Ext: o + s	EXC + MTA
Reston et al., 2017 [47]	A	65	Ns	11	H*: 4	Ext: o + s	EXC

Filling material/s	Medical and dental history	Intraoral clinical examination	2D X-rays	3D X-rays	Clinical follow-up	Rx follow-up	Follow-up (months)	Outcome
CEMC	Yes	Part	Yes	Yes	Yes	Yes	12	Suc
GIC	Part	Part	Yes	Yes	Yes	Yes	60	Suc
RMGIC	Yes	Part	Yes	Yes	Yes	Yes	14	Suc
MTA	Yes	Yes	Yes	Yes	Yes	Yes	12	Suc
BIOD	Yes	Part	Yes	Yes	Yes	Yes	12	Suc
MTA	Part	Part	Yes	No	Yes	No	36	Suc
MTA	Part	No	No	No	Yes	No	24	Suc
BIOD	Part	No	No	No	Yes	No	36	Suc
MTA + GIC	No	Part	Yes	Yes	Yes	Yes	20	Suc
MTA	Yes	Part	Yes	No	No	Yes	72	Suc
MTA	Yes	Yes	Yes	Yes	Yes	Yes	48	Suc
SUPER EBA	Yes	Part	Yes	Yes	Yes	Yes	24	Suc
CA(OH) ₂ PT + COMP RES	Yes	Part	Yes	Yes	Yes	Yes	12	Suc
MTA	Yes	Yes	Yes	Yes	Yes	Yes	12	Suc
AMALGAM	Part	Part	Yes	No	Yes	No	60	Suc
MTA	Yes	Part	Yes	Yes	Yes	Yes	12	Suc
CEMC	Part	Part	Yes	No	Yes	Yes	12	Suc
CEMC	Part	Part	Yes	No	Yes	Yes	36	Suc
CEMC	Part	Part	Yes	No	Yes	Yes	30	Suc
CEMC	Part	Part	Yes	No	Yes	Yes	12	Suc
CEMC	Part	Part	Yes	No	Yes	Yes	16	Suc
CEMC	Part	Part	Yes	No	Yes	Yes	12	Suc
COMP RES	Part	Part	Yes	Yes	Yes	Yes	36	Suc
BIOD	Part	Part	Yes	Yes	Yes	Yes	18	Suc
CR + CROWN	Part	Part	Yes	Yes	Yes	Yes	12	Suc
BIOD	No	Part	Yes	Yes	Yes	Yes	18	Suc
COMP RES	Yes	Part	Yes	Yes	Yes	Yes	30	Suc
COMP RES	No	Part	Yes	Yes	Yes	Yes	84	Suc
GP + RBS + FC	No	Part	Yes	Yes	Yes	Yes	36	Suc
COMP RES	No	Part	Yes	Yes	Yes	Yes	24	Suc
RMGIC	Yes	Part	Yes	Yes	Yes	Yes	24	Suc
BIOD	Part	Part	Yes	Yes	No	Yes	48	Suc
MTA + GIC	Part	Yes	Yes	Yes	Yes	Yes	36	Suc
BIOD	Part	Part	Yes	Yes	No	Yes	60	Suc
BIOD	Part	Part	Yes	Yes	Yes	Yes	24	Suc
MTA + RMGIC + CR	Yes	Part	Yes	Yes	Yes	Yes	12	Suc
GIC	Yes	Part	Yes	No	Yes	Yes	324	Suc
MTA	Part	Part	Yes	Yes	Yes	Yes	24	Suc
RMGIC	Part	Part	Yes	No	No	Yes	180	Suc

(Continues)

TABLE 1 (Continued)

Authors	Patient	Age	Gender	Tooth	Classification	Treatment	
						Approach	Removal of resorption
Lima et al., 2017 [84]	A	30	F	21	H: 2	Ext surg	EXC
Shemesh et al., 2017 [53]	A	22	M	21	H: 4	Int	EXC + NaOCl + Ca(OH) ₂
	B	44	M	21	H: 4	Int	EXC + NaOCl + Ca(OH) ₂
	C	37	M	23	H: 4	Int	EXC + NaOCl + Ca(OH) ₂
	D	41	F	21	H: 4	Int	EXC + NaOCl + Ca(OH) ₂
Tsaousoglou et al., 2017 [85]	A	44	F	11	H: 3	Ext surg	EXC
	B	58	F	21	H: 2	Ext surg	EXC
Asgary and Nosrat, 2016 [55]	A	28	F	42	H: 4	Int	EXC
Karypidou et al., 2016 [51]	A	20	F	11	H: 2	Ex no sur	EXC
	A	20	F	21	H: 3	Int	EXC
Lo Giudice et al., 2016 [86]	A	24	F	11	H: 3	Ext surg	EXC
	A	24	F	12	H: 2	Ext surg	EXC
	B	Ns	M	12	H: 2	Ext surg	EXC
	C	Ns	M	21	H: 3	Ext surg	EXC
Patel et al., 2016 [87]	D	Ns	F	33	H: 2	Ext surg	EXC
	A	22	M	43	H*: 3	Int rep	EXC
Yoshpe et al., 2016 [88]	A	12	M	43	H: 3	Ext surg	EXC
Asgary and Fazlyab, 2015 [89]	A	30	M	33	H: 3	Ext surg	EXC
Bal et al., 2015 [90]	A	50	F	41	H*: 2	Ext surg	EXC
Bhagabati et al., 2015 [91]	A	20	M	21	H: 3	Ext surg	EXC + 90% TCA
Costa et al., 2015 [92]	A	28	M	13	H: 2	Ext surg	EXC
	B	38	F	13	H: 3	Int	EXC + NaOCl + Ca(OH) ₂
Krishnan et al., 2015 [93]	A	32	M	11	H: 3	Ext surg	EXC
Salzano and Tirone, 2015 [52]	A	46	F	15	H: 4	Int	EXC + 5,25% NaOCl + H ₂ O ₂
	B	22	F	27	H: 4	Int	EXC
Bharti et al., 2014 [54]	A	18	F	11	H: 2	Int + ext	EXC
Gürsoy et al., 2014 [94]	A	60	F	45	H*: 3	Ext surg	EXC
Harris et al., 2014 [95]	A	78	M	21	H: 3	Ext surg	EXC + 90% TCA
Alves et al., 2013 [96]	A	12	F	21	H*: 2	Int + ext	EXC
Gandi and Disha, 2013 [97]	A	24	M	21	H*: 4	Ext surg	EXC
Ikhar et al., 2013 [63]	A	19	M	21	H: 3	Ext surg	EXC + 5% NaOCl + 17% EDTA
Johns et al., 2013 [98]	A	35	M	23	H*: 4	Ext surg	EXC + 90% TCA
Tavares et al., 2013 [99]	A	31	M	11	H: 3	Ext surg	EXC + 90% TCA
Umer et al., 2013 [100]	A	23	M	11	H: 2	Int	Ca(OH) ₂ FAMILY
Kqiku et al., 2012 [101]	A	31	F	21	H: 2	Ext surg	0,1% CHX + MTA
Fernández and Rincón, 2011 [102]	A	67	M	41	H: 4	Ext surg	EXC + 90% TCA
	A	17	F	22	H: 4	Ext surg	EXC
Vinothkumar et al., 2011 [104]	A	15	M	21	H: 2	Ext surg	TCA 90%
Schwartz et al., 2010 [3]	A	47	M	17	H*: 2	Int	EXC + TCA
	B	80	F	21	H*: 3	Ext surg	EXC + 90 %TCA
Estevez et al., 2010 [105]	A	28	M	21	H: 3	Ext surg	EXC + 90% TCA
Yilmaz et al., 2010 [106]	A	59	M	23	H*: 3	Ext surg	EXC

Filling material/s	Medical and dental history	Intraoral clinical examination	2D X-rays	3D X-rays	Clinical follow-up	Rx follow-up	Follow-up (months)	Outcome
RMGIC	Part	Part	Yes	Yes	Yes	Yes	18	Suc
GP + RBS	Yes	Yes	Yes	Yes	Yes	Yes	50	Suc
GP + RBS	Part	Yes	Yes	Yes	Yes	Yes	36	Suc
GP + RBS	Yes	Yes	Yes	Yes	Yes	Yes	36	Suc
GP + RBS	Part	Yes	Yes	Yes	Yes	Yes	36	Suc
MTA + GIC	Yes	Yes	Yes	No	Yes	Yes	36	Suc
MTA + GIC	Yes	Yes	Yes	No	Yes	Yes	36	Suc
CEMC	Part	Part	Yes	No	Yes	Yes	24	Suc
BIOD + CR	Yes	Part	Yes	No	Yes	Yes	36	Suc
BIOD + CR	Yes	Part	Yes	No	Yes	Yes	36	Suc
COMP RES	Yes	Part	Yes	No	Yes	Yes	36	Suc
COMP RES	Yes	Part	Yes	No	Yes	Yes	36	Suc
COMP RES	Yes	Part	Yes	No	Yes	Yes	36	Ns
COMP RES	Yes	Part	Yes	No	Yes	Yes	36	Ns
COMP RES	Yes	Part	Yes	No	Yes	Yes	36	Ns
GIC	Yes	Part	Yes	Yes	Yes	Yes	18	Suc
MTA	Part	Part	Yes	No	No	No	18	Suc
CEMC + CR	Part	Part	Yes	No	Yes	Yes	12	Suc
COMP RES	Yes	Part	Yes	No	Yes	Yes	36	Suc
MTA	Yes	Part	Yes	No	Yes	Yes	36	Suc
BIOD + CR	Part	Part	Yes	No	Yes	Yes	36	Suc
BIOD	Part	Part	Yes	Yes	Yes	Yes	18	Suc
RMGIC	Yes	Yes	Yes	Yes	Yes	Yes	18	Suc
MTA	Part	Part	Yes	Yes	Ns	Yes	18	Suc
MTA	Part	Part	Yes	Yes	Ns	Yes	12	Suc
MTA + GIC	Part	Part	Yes	No	Yes	Yes	12	Suc
MTA + CR	Part	Part	Yes	No	Yes	Yes	18	Suc
RMGIC	Part	Part	Yes	No	Yes	Yes	30	Suc
MTA + CR	Part	Part	Yes	No	Yes	Yes	12	Suc
MTA	Yes	Part	Yes	No	No	Yes	18	Suc
MTA + CR	Yes	Part	Yes	No	Yes	Yes	48	Suc
CR + GIC	Yes	Yes	Yes	No	Yes	Yes	24	Suc
RMGIC	Part	Part	Yes	No	Yes	Yes	12	Suc
GP + PCH RCS	Yes	Yes	Yes	No	Yes	Yes	36	Suc
MTA + GIC + CR	Part	Part	Yes	No	Yes	Yes	48	Suc
MTA + FC	Yes	Part	Yes	Yes	Yes	Yes	72	Suc
GIC	Part	Yes	Yes	Yes	Yes	Yes	19	Suc
GIC + CR	Yes	Yes	Yes	No	Yes	Yes	12	Suc
COMP RES	Part	Part	Yes	No	Yes	Yes	96	Suc
RMGIC	Part	Part	Yes	No	Yes	Yes	180,5	Ext
RMGIC	Yes	Part	Yes	Yes	Yes	Yes	12	Suc
MTA	Part	Yes	Yes	No	Yes	Yes	12	Suc

TABLE 1 (Continued)

Authors	Patient	Age	Gender	Tooth	Classification	Treatment Approach	Removal of resorption
Nikolidakis et al., 2008 [107]	A	46	M	13	H*: 2	Ext surg	EXC
	A	46	M	23	H*: 2	Ext surg	EXC
	A	46	M	33	H*: 3	Ext surg	EXC
Park and Lee, 2008 [108]	A	28	M	45	H*: 3	Int	EXC
Gonzales and Rodekirchen, 2007 [61]	A	27	M	12	H*: 2	Int + ext	EXC
Heithersay, 2007 [18]	A	21	F	11	H: 2	Ex no sur	EXC + 90% TCA
Hata et al., 2007 [50]	A	11	M	42	H*: 2	Ex no sur	EXC
Patel and Dawood, 2007 [109]	A	32	M	45	H*: 2	Ext surg	EXC
Smidt et al., 2007 [48]	A	22	F	12	H: 3	Ext: o + s	EXC + 90% TCA
Jensen, 2006 [110]	A	40	M	46	H: ½	Int	EXC + 90% TCA
Baratto-Filho et al., 2005 [111]	A	23	M	22	H: 4	Int	EXC + Ca(OH) ₂ + 1% NaOCl
Patel et al., 2002 [112]	A	29	M	21	H*: 2	Ext surg	EXC
Hokett and Hoen, 1998 [37]	A	28	F	24	H*: 3	Ext surg	EXC
Montgomery, 1984 [36]	A	21	M	21	H*: 2	Int	EXC + Ca(OH) ₂ + CAMPH CHLF

Note: Patients: A indicate the first case, followed by B, C, D etc. when the article reported more than one case.

Age: age of the patient at the time of diagnosis.

Gender: M, male; F, female; Ns, not stated.

Classification: H: Heithersay's classification, H*: Heithersay's classification assigned by reviewers P: Patel's classification; O: Others' classification.

Treatment approach: INT + EXT = internal + external, EXT SURG = external surgical, INT = internal, MON = monitoring, INT REP = intentional replantation, EXT: O + S = external: orthodontic + surgical, EX NO SUR = external not surgical.

Removal of resorption: Ca(OH)₂ PT, calcium hydroxide paste; CAMPH CHLF, camphorated chloramphenicol; CARNOY'S SOLUTION, Carnoy's solution; CHX, chlorhexidine; EXC, excavation; H₂O₂, hydrogen peroxide; MTA, mineral trioxide aggregate cement; NONE, no treatment; NS, not stated; PHTDYN, photodynamic protocol; x% EDTA, x% ethylenediaminetetraacetic acid solution; x% NaOCl, x% sodium hypochlorite solution; x% TCA, x% trichloroacetic acid aqueous solution.

Filling material/s: AMALGAM, alloy of mercury and silver; BIOD, Biodentine™; Ca(OH)₂ PT, calcium hydroxide paste;

CEMC, calcium-enriched mixture cement; CH + x, calcium hydroxide + x; CR, composite resins; FCOM, flowable composite; GIC, glass ionomer cement; GP + PCH RCS, gutta-percha + polymeric calcium hydroxide root canal sealer; GP + RBS + FC, gutta-percha + resin-based sealer + flowable composite; GP + RBS, gutta-percha + resin-based sealer; IRM, intermediate restorative material cement; LCC, light-cured compomer; MTA + FC, mineral trioxide aggregate cement + flowable compomer; MTA, mineral trioxide aggregate cement; NONE, no filling/s; P&C, post and crown; RMGIC, resin-modified glass ionomer cement; SUPER EBA, zinc oxide eugenol cement reinforced with ethoxy benzoic acid (EBA); TPC, temporary post crown.

Outcome: EXT, extracted; NS, not stated; SUC, successful.

(59%), in particular in the external (69%), and combined interventions, while these techniques were used less often in the cases managed internally. Chemicals/medicaments were used to complement the removal of the pathologic tissue in 41% of the cases, with trichloroacetic acid (TCA) compounds being most commonly reported (46%), followed by a combination of two or more chemicals (Table S5). Calcium hydroxide and sodium hypochlorite were used alone or associated with other medicaments (Table 1). One report introduced the 'photodynamic inactivation of the lesion' (Table 1). With regards to the H classifications, mechanical removal of resorptive tissue with a bur was reported most frequently for H2 and H3 (44% and 36% respectively). When medicaments were used, TCA, followed by calcium hydroxide were the most frequent choice in H2 and H3. Calcium hydroxide was often used in H4 lesions, with

sodium hypochlorite being widely used in H3 and H4, also combined with other chemicals (Table 1).

Since 99% of the cases included in this review claimed a favourable outcome after a minimum follow-up of 12 months, no method used to remove the resorptive tissue was associated with a superior clinical and radiographic outcome, in relation to the approach chosen, and to Heithersay's classification.

Among the materials used to restore the access and repair the defect, which one has shown the better outcome, in relation to the approach chosen, and to the Heithersay classification?

The dental material chosen most often to restore teeth were the calcium silicate-based cements (bioactive endodontic cements; BECs) used in combination with composite resins (42%), or alone (32%), followed by glass ionomer cements (GICs) (pure or resin-modified)

Filling material/s	Medical and dental history	Intraoral clinical examination	2D X-rays	3D X-rays	Clinical follow-up	Rx follow-up	Follow-up (months)	Outcome
GIC	Yes	Part	Yes	No	Yes	Yes	36	Suc
GIC	Yes	Part	Yes	No	Yes	Yes	36	Suc
GIC	Yes	Part	Yes	No	Yes	Yes	36	Suc
MTA	Yes	Yes	Yes	No	Yes	Yes	27	Suc
RMGIC	Part	Yes	Yes	No	Yes	Yes	24	Suc
GIC	Part	Part	Yes	No	Yes	Yes	60	Suc
CH + CR	Yes	Part	Yes	No	Yes	Yes	36	Suc
GIC	Yes	Part	Yes	Yes	Yes	Yes	12	Suc
GIC	Part	Part	Yes	No	Yes	Yes	42	Suc
GIC	Yes	Yes	Yes	No	Yes	Yes	12	Suc
MTA + GIC	Part	Part	Yes	No	Yes	Yes	24	Suc
GIC	Yes	Yes	Yes	No	No	Yes	36	Suc
IRM	Yes	Part	Yes	No	Yes	Yes	24	Suc
P&C	Yes	Part	Yes	No	Yes	Yes	78	Suc

(23%), composite resins (12%), amalgam and the association of two or more (28%), mostly BECs-based products (Table S6). In external surgical interventions, BECs were reported more frequently followed by GICs, two or more products and composites. Amalgam was seldom used. BECs+composite and GIC were used frequently also in external non-surgical treatments and in the combined approach. The use of BECS was more often reported for the internal management of ECR, followed by the association of other products, including gutta-percha and sealers and GIC. Lesions classified as H2 and H3 were restored predominantly with BECs alone (41%) or in association with bonded restorations followed by GIC and composites, whereas H4 defects were almost always restored with BECs (57%), followed by gutta-percha and sealer and GIC (Table S6).

Since 99% of the cases included in this review claimed a favourable outcome after a minimum follow-up of 12 months, no material used to repair the defect was associated with a superior clinical and radiographic outcome, in relation to the approach and to the Heithersay classification.

DISCUSSION

The clinical management of ECR aims to retain the affected teeth in a healthy, functional and aesthetic state [7]. However, there is often disagreement between the various dental specialties and even within the same group of specialists [3] regarding the best clinical approach to manage the condition. According to recent

ESE guidelines, treatment options depend on the extent, nature and accessibility of the defect and include external or internal repair of the resorptive defect (\pm root canal treatment) and intentional replantation [31]. Periodic review or immediate extraction is also considered an option for managing untreatable teeth [7]. Other protocols reported were based either on the accessibility and feasibility of effectively isolating the resorptive lacunae or on both the previous points with the addition of the size of the portal of entry of the lesion and its circumferential extension, as the discriminating factors for choosing specific treatment approaches [23, 32].

This study was designed to assess whether the choice of the external rather than internal and combined therapeutic approach influenced the outcome of ECR, in a general population of patients. The articles which met the inclusion criteria were all case series and case reports, a situation that creates an inherent bias; nevertheless, it was decided to perform the review, as randomised clinical trials were not available.

Most articles examined provided a clear description of the demographic characteristics, medical history and clinical condition of the patients, and all reported the diagnosis of the resorptive condition, the treatment procedures, their results and the post-intervention clinical assessment (Table 1).

Even if some significant publications were written before 2000s [33–37], the majority of reports were published between 2010 and 2021, which may imply a greater awareness of the disease more recently through clinical presentations, chapters in books, the availability of advanced diagnostic techniques (use of magnification, CBCT), better awareness of the potential for successful treatment, possible increase in predisposing factors and, potentially, an increase in ECR cases during the last 10 years [7, 38].

However, the reports selected do not reflect the totality of the reports in the literature, as many were rejected because they did not comply with the inclusion criteria.

A substantial amount of additional information on ECR was also obtained writing this review.

Importantly and of concern, was the fact that a range of terminology was used to describe the resorptive processes that were named in 10 different ways (Table 1): ECR—external cervical resorption; ECRR—external cervical root resorption; CER—cervical external resorption; EIRR—external invasive root resorption; ERR—external resorption/external root resorption; IRR—invasive root resorption; ICRR—invasive cervical root resorption; ICERR—invasive cervical external root resorption; ITR—internal tunnelling resorption. ICR (invasive cervical resorption) was the most commonly used term. This finding

suggests the need for an international agreement on universally accepted terminology.

In the reports, the H classification system was used more frequently to describe the lesions, probably as a consequence of the initial lack of CBCT technology. When the P classification was used, it was, in the majority of the cases, described in conjunction with the H system [39–41]; only in two cases was the P classification used alone [42, 43]. It is important to emphasise that 20 out of the 66 reports included did not describe the classification but, interestingly, in 23 cases/teeth the reviewers were able to assign one (H), based on the information available (Table 1). No descriptions of H1 resorptions were found, probably because these early lesions are not clinically evident and, when discovered, are often treated as restorative cavities [2]. Class H2 and H3 ECR lesions, as expected, were the most represented because they are easier to visualise and diagnose [2] (Table 1).

The findings of this review draw attention to the need to clarify the characteristics of resorption in all clinical cases which are reported, in order for readers to fully understand the position and extent of the lesion and how it links to the outcome of treatment. The only examination that was used in all the cases to diagnose ECR was the periapical radiograph (one or more), confirming that it remains the preferred baseline diagnostic tool in the endodontic field [44]. Periapical radiographs were complemented with a CBCT examination in almost half of the reports, in particular after 2010, as the availability of this diagnostic technique increased [6]. Needless to say, three-dimensional imaging plays a key role in the diagnosis, classification and choice of the best therapeutic approach in ECR, and the latest reports reviewed are encouraging because of the growing trend of incorporating CBCT in the first assessment of this condition. On the contrary, intra-oral periapical radiographs may be best used for the follow-ups over time, which will respect the ALARA principles [44].

The overall lack of standardised information in most cases did not help in understanding the possible predisposing factors for the pathologic condition, and this should become a major focus in the future reports [25, 45].

The cases illustrated, highlighted that most treated teeth, representing H2, H3 and H4 seemed to have a favourable outcome (Table 1), but it must be considered that 34 reports had only 1 year follow-up.

As a basic principle, early diagnosis, good access to the lesions, debridement, inactivation of the resorption, and restoration of the defect are considered the premises for successful outcomes in ECR, and diverse approaches to treat the lesions have been described [1, 2].

Answers to the focused questions

Among the approaches used to treat ECR, which one has shown the better outcome, in relation to the Heithersay classification?

Interestingly, as written in the results, not one of the techniques appeared to be more effective. An external surgical intervention was reported most often in the treatment of ECR lesions and was highly correlated with H3 cases (Table 1). This approach was considered where the lesions were wide and could be better reached externally and was considered advantageous to prevent unnecessary root canal treatments and to allow a more effective cleaning of these lesions [23]. Additionally, this modality would allow for pulp capping options when resorptive tissues are in close proximity to the pulp space and the PRRS is disrupted [22]. On the contrary, depending on the location and size of the defect, the amount of periodontal support that should be removed for surgical intervention must always be considered carefully [3]. Furthermore, surgical treatment should be avoided when resorptive lacunae have an entirely proximal location to prevent periodontal damage [32].

Orthodontic extrusion (OE) was described as an attractive alternative to surgery for exposing the ECR defect while preserving the osseous and gingival architecture [23, 27, 46–48]. Smidt et al. carried out the orthodontic extrusion of tooth 12 (H3) with two fiberotomies followed by a post and core prosthetic restoration and described the procedure as rapid, successful and a better choice to prevent attachment loss [48]. In all the other cases, orthodontic extrusion was uneventfully achieved in different modalities and over various time frames: from 80 days to 3 months, to 1 year, but without performing the fiberotomies. Among the disadvantages of OE, it was pointed out that, once extrusion had been completed, a crown lengthening procedure or a surgical flap was still required to treat the lesion [23, 46, 47].

Intentional replantation was considered an extreme choice when access to the lesion was not feasible from a direct approach [23]. However, this option poses the same problem as orthodontics because of the trauma generated to the periodontal ligament by extraction [5].

External non-surgical repair, reported only for those lesions confined to the cervical region, has the advantage of being conservative in nature, not requiring surgical flaps or root canal treatment if the pulp is vital [18, 49–51].

Lesions with small portals of entry and large internal extension, were deemed to represent the best indication for using an internal access, and it was mostly adopted in advanced-stage H4 lesions [23, 52] thus limiting the unnecessary removal of intact tooth tissue [23] and alveolar bone [3, 53].

Root canal treatment was considered necessary within the internal access to ECR [21], either when the pulp was involved, or simply because it made it easier to reach the resorptive tissue from inside the tooth [54]. Considering that in many cases of ECR, there is no communication between the resorption and the root canal, and the pulp is healthy, several of the most recent reports successfully used a conservative treatment based on partial internal excavation of the invasive tissue [53, 55], combined with different types of vital pulp therapy, when needed [56] thus linking the intervention to the most recent protocols of pulp preservation [57]. Noticeably, with respect to this aspect, Irinakakis et al. [26], in a recently published retrospective cohort study, indicated that the treatment of ECR had lower failure rates when the cases presented a root canal treatment alone or in conjunction with the repair of the lesion.

Finally, ECR was often treated using both internal and external accesses (Table 1) when clinicians felt the lesion could be addressed better surgically, but the tooth also required root canal treatment, and the pulp chamber did not communicate with the invasive tissue [54, 58, 59].

The additional external intervention could represent, in these situations, an alternative to incorporating the lesion within the endodontic space, with the aim to prevent tissue removal inside the tooth, as seen in some reports [52]. Combined access was also used when, while performing external cleaning of the lacunae [60], further extension to the root canal became necessary, or when, following RCT, there was the need to better control the margins of the restoration [32]. In other circumstances, surgical treatment following RCT was associated with the aesthetic contour of the gingiva in anterior teeth [61] (Table 1).

Among the methods used to remove/inactivate the resorptive tissue, which one has shown the better outcome, in relation to the approach chosen, and the Heithersay classification?

Based on this review, no methods used to remove the resorptive tissue were associated with a superior performance when treating ECR.

In his original protocol, Heithersay showed excellent and consistent clinical results using TCA in a 90% aqueous solution as inactivating agent, to complement the mechanical removal of the invading tissue [27]. Actually, in most of the cases examined in this review, tissue removal was performed with a slow-speed bur alone, especially when the lesions were treated externally or with both approaches (Table 1). Ultrasound [32, 40, 52] and sonic instruments [52, 54] with continuous water irrigation were also described as optimal options for removing bleeding or hard invasive tissue. Thus, based on the many reports examined, mechanical debridement alone seemed to lead to adequate field control and good prognosis, even without the use of

an inactivating agent in most H classes. Moreover, while some authors considered the fibro-osseous ingrowth of tissue within the lacunae as a repair process, others deemed it necessary to remove mechanically this tissue entirely [1, 38], under magnification and good illumination, without damaging the adjacent hard tissues [20, 52].

The preference of burs, ultrasonic tips or sharp excavators as seen in this review was confirmed in a recent publication [25].

Conversely, in non-surgical internal treatment, since it is almost impossible to eliminate all contents of the penetrating channels mechanically [23], it becomes crucial to rely on a chemical agent to remove the remaining pathological tissue, which, if partially left, may continue the resorptive process [27, 53, 55, 56].

When a chemical agent was chosen (Table 1), TCA in a 90% aqueous solution was the preferred agent to promote coagulation necrosis of the hyperplastic, invasive tissue, with the recognised additional action that it can penetrate the least accessible recesses within the affected teeth to cauterise the residual tissue communicating with the periodontal ligament [27]. The possible limitations of its use were attributed to the fact that it may accidentally damage the surrounding soft tissues [27] whenever predictable rubber dam isolation is not feasible [3]. Moreover, it was observed that dentine conditioned with TCA undergoes deep demineralisation that affects adhesion, it was thus recommended that the exposed tooth surface is refreshed with a bur before final restoration [3].

Calcium hydroxide was the second most popular material described (Table 1), applied as a dressing, or slowly released from bioactive materials, it supposedly inactivated the invasive tissue within the lacunae even after partial excavation [23, 53, 62]. In cases of difficult isolation, 1% [63] to 6% [63, 64] sodium hypochlorite was used similarly to TCA, sometimes activated with ultrasound [52], or refreshed frequently at the site to dissolve the tissue remnants [64]. An effective combination was obtained using calcium hydroxide compounds and sodium hypochlorite during treatment [53] (Table 1).

Among the materials used to restore the access and repair the defect, which one has shown the better outcome, in the context of the clinical approach and on the Heithersay classification?

Based on the outcome of this review, none of the materials used in the reports exhibited a superior performance when treating ECR.

Bioactive endodontic cements were mentioned more often to restore ECR defects [65] (Table 1). In particular, mineral trioxide aggregate, MTA™ and Biodentine™ were popular for restoring H2, H3 and H4 cavities, when communicating with the periodontium and were chosen because of their physical properties such as good adaptation

to moisture conditions, biocompatibility, sealing ability and hard tissue conductivity [66–69] (Table 1).

Their drawbacks, including slight tooth discoloration and low resistance to abrasion [70], were addressed by avoiding placing the materials above the crestal bone or by covering the supragingival part of the restoration with composite resin for a durable and more aesthetic result [51, 71]. Glass ionomers (pure or resin-modified) were also chosen for their advantages of adhering to tooth structures, releasing fluorides, good seal and being sufficiently hard [3, 72].

Composite resins were normally used upon the completion of ECR treatment to recreate the tooth anatomy and restore the access cavities (Table 1). More recently, it was suggested that accurately polished nano-hybrid composites, extended within the biological width, may present a successful clinical outcome conferring a well-sealed restoration with a significant reduction in plaque formation and the ‘minor’ consequence of a virtual periodontal pocket [23, 73]. Gutta-percha and sealer represented a good alternative to fill H4 defects (Table 1).

The overall favourable outcome of the cases examined, (Table 1) is surely partly affected by the short follow-up time (36.38 months average) and by the intrinsic bias of the case reports as the source of information, as it is unclear whether the motivation for reporting a successful case is the same as that for publishing a problematic one. However, in the current review, most reports were classified between ‘moderate’ and ‘high’ quality, and when no higher level of evidence is available, case reports could still bring a contribute to our knowledge [74].

Another limitation of this review turned out to be that several important articles could not be included in the review because they did not comply with the inclusion criteria which required the therapeutic management of each lesion would be singularly described in detail [19, 25–27].

Fortunately, these reports could be used at their best to discuss our findings. As seen in the introduction, according to Heithersay the treatment of ECR shows results ranging from very successful in H1 and H2, to reasonably successful in H3, and generally unsuccessful in H4 cases [27]. These lower expectations on ECR are surely in part related to the minimum follow-up period of 3 years reported by the author. Jebril et al., [19] estimated that the prognosis in surgical ECR cases, not including any H4, to be 79%, and that the failures related to the progression of the resorption and lack of restorative integrity were attributed to the extension of the lesion. Less favourable treatment results, occurring 8 years after the diagnosis of ECR, were also discussed by Irinakakis et al., in a retrospective clinical study [26]. They also observed that there was no significant difference in the success of managing ECR whether the repair was external or internal, in line

with this study, as was the selection of the materials used for repairing the defects [26]. Finally, they described the posterior tooth location and higher H classes as the local determinants, significantly associated with the worst treatment outcomes [26].

Following a clinical approach designed strategy, Mavridou et al. [25] concluded that pain, probing feasibility and presence of bone-like tissue were also important predictor factors for clinical success. They further assessed the preference of using burs, ultrasonic tips or sharp excavators, for the removal of the invasive tissue, as seen in this systematic review [25].

The consequences of choosing to not intervene in a specific clinical situation of ECR were not evaluated in this review. Nevertheless, the option of not repairing some lesions is encouraged by the result from Irinakakis et al., [26] who found that there was a no significantly higher risk between treatment versus tooth monitoring in ECR.

According to the present study there is no single best approach to manage ECR lesions, including the choice of the access, the method to remove the pathologic tissue and the material used to repair the damage. These results are similar to what has emerged from a classic prospective and recent retrospective clinical reports [19, 25–27].

CONCLUSIONS

Within the limitation of including only case reports/case series to extract data, no single method or material used to treat ECR defects was more effective in achieving predictable, positive results.

The choice of treatment for class H2, H3 and H4 lesions, depends on the extent of the lesion, its size and consequently its accessibility. However, as no randomised clinical trials are yet available, there is a strong need for specifically designed clinical studies, which will move the process of decision-making on ECR treatment closer to establishing a shared protocol. Furthermore, it is important to develop a standardised definition of the goal of treatment for this rare condition which should be standardised internationally.

AUTHOR CONTRIBUTIONS

All authors have contributed significantly and are in agreement with the manuscript.

ACKNOWLEDGEMENTS

The authors did not receive any financial grant or other funding in relation to this study.

CONFLICT OF INTEREST STATEMENT

The authors deny any conflicts of interest related to this study.

ORCID

Giulia Bardini  <https://orcid.org/0000-0003-1073-8597>

Paul Dummer  <https://orcid.org/0000-0002-0726-7467>

REFERENCES

1. Heithersay GS. Clinical, radiologic, and histopathologic features of invasive cervical resorption. *Quintessence Int.* 1999;30(1):27–37.
2. Heithersay GS. Invasive cervical resorption. *Endod Top.* 2004; 7(1):73–92. <https://doi.org/10.1111/j.1601-1546.2004.00060.x>
3. Schwartz RS, Robbins JW, Rindler E. Management of invasive cervical resorption: observations from three private practices and a report of three cases. *J Endod.* 2010;36(10):1721–30. Available from: <https://linkinghub.elsevier.com/retrieve/pii/S0099239910005145>
4. Heithersay GS. Invasive cervical resorption: an analysis of potential predisposing factors. *Quintessence Int.* 1999;30(2):83–95.
5. Mavridou AM, Bergmans L, Barendregt D, Lambrechts P. Descriptive analysis of factors associated with external cervical resorption. *J Endod.* 2017;43(10):1602–10. Available from: <https://linkinghub.elsevier.com/retrieve/pii/S0099239917307045>
6. Patel S, Foschi F, Mannocci F, Patel K. External cervical resorption: a three-dimensional classification. *Int Endod J.* 2018;51(2):206–14. <https://doi.org/10.1111/iej.12824>
7. Patel S, Lambrechts P, Shemesh H, Mavridou A. European Society of Endodontology position statement: external cervical resorption. *Int Endod J.* 2018;51(12):1323–6.
8. Kikuta J, Yamaguchi M, Shimizu M, Yoshino T, Kasai K. Notch signaling induces root resorption via RANKL and IL-6 from hPDL cells. *J Dent Res.* 2015;94(1):140–7. <https://doi.org/10.1177/0022034514555364>
9. Tronstad L. Root resorption—etiology, terminology and clinical manifestations. *Dent Traumatol.* 1988 Dec;4(6):241–52. <https://doi.org/10.1111/j.1600-9657.1988.tb00642.x>
10. Trope M. Root resorption of dental and traumatic origin: classification based on etiology. *Pract Periodontics Aesthet Dent.* 1998;10(4):515–22. Available from: <http://europepmc.org/abstract/MED/9655059>
11. Mavridou AM, Hauben E, Wevers M, Schepers E, Bergmans L, Lambrechts P. Understanding external cervical resorption in vital teeth. *J Endod.* 2016;42(12):1737–51. <https://doi.org/10.1016/j.joen.2016.06.007>
12. Gunst V, Mavridou A, Huybrechts B, Van Gorp G, Bergmans L, Lambrechts P. External cervical resorption: an analysis using cone beam and microfocus computed tomography and scanning electron microscopy. *Int Endod J.* 2013;46(9):877–87. <https://doi.org/10.1111/iej.12073>
13. Patel S, Lambrechts P, Shemesh H, Mavridou A. European Society of Endodontology position statement: external cervical resorption. *Int Endod J.* 2018;51(12):1323–6. <https://doi.org/10.1111/iej.13008>
14. Mavridou AM, Pyka G, Kerckhofs G, Wevers M, Bergmans L, Gunst V, et al. A novel multimodular methodology to investigate external cervical tooth resorption. *Int Endod J.* 2016;49(3):287–300. <https://doi.org/10.1111/iej.12450>
15. Fuss Z, Tsesis I, Lin S. Root resorption - diagnosis, classification and treatment choices based on stimulation factors. *Dent Traumatol.* 2003;19(4):175–82. <https://doi.org/10.1034/j.1600-9657.2003.00192.x>

16. Kandalgaonkar SD, Gharat LA, Tupsakhare SD, Gabhane MH. Invasive cervical resorption: a review. *J Int Oral Heal*. 2013;5(6):124–30.
17. Patel S, Durack C, Abella F, Shemesh H, Roig M, Lemberg K. Cone beam computed tomography in endodontics - a review. *Int Endod J*. 2015;48(1):3–15. <https://doi.org/10.1111/iej.12270>
18. Heithersay G. Management of tooth resorption. *Aust Dent J*. 2007;52(1 Suppl):S105–21. <https://doi.org/10.1111/j.1834-7819.2007.tb00519.x>
19. Jebiril A, Aljamani S, Jarad F. The Surgical Management of External Cervical Resorption: a retrospective observational study of treatment outcomes and classifications. *J Endod*. 2020;46(6):778–85. <https://doi.org/10.1016/j.joen.2020.03.006>
20. Patel S, Kanagasingam S, Pitt FT. External cervical resorption: a review. *J Endod*. 2009;35(5):616–25. Available from: <https://linkinghub.elsevier.com/retrieve/pii/S0099239909000909>
21. Patel S, Foschi F, Condon R, Pimentel T, Bhuvva B. External cervical resorption: part 2 - management. *Int Endod J*. 2018;51(11):1224–38. <https://doi.org/10.1111/iej.12946>
22. Chen Y, Huang Y, Deng X. A Review of External Cervical Resorption. *J Endod [Internet]*. 2021;47(6):883–94. Available from: <https://linkinghub.elsevier.com/retrieve/pii/S0099239921001564>
23. Espona J, Roig E, Durán-Sindreu F, Abella F, Machado M, Roig M. Invasive cervical resorption: clinical Management in the Anterior Zone. *J Endod*. 2018;44(11):1749–54. Available from: <https://linkinghub.elsevier.com/retrieve/pii/S0099239918305168>
24. Haapasalo M, Parhar M, Huang X, Wei X, Lin J, Shen Y. Clinical use of bioceramic materials. *Endod Top*. 2015;32(1):97–117. <https://doi.org/10.1111/etp.12078>
25. Mavridou A, Rubbers E, Schryvers A, Maes A, Linsen M, Barendregt DS, et al. A clinical approach strategy for the diagnosis, treatment and evaluation of external cervical resorption. *Int Endod J*. 2022;55(4):347–73. <https://doi.org/10.1111/iej.13680>
26. Irinakis E, Haapasalo M, Shen Y, Aleksejuniene J. External cervical resorption – treatment outcomes and determinants: a retrospective cohort study with up to 10years of follow-up. *Int Endod J*. 2022;55(5):441–52. <https://doi.org/10.1111/iej.13717>
27. Heithersay GS. Treatment of invasive cervical resorption: an analysis of results using topical application of trichloroacetic acid, curettage, and restoration. *Quintessence int*. 1999;30(2):96–110.
28. Page MJ, McKenzie JE, Bossuyt PM, Boutron I, Hoffmann TC, Mulrow CD, et al. The PRISMA 2020 statement: an updated guideline for reporting systematic reviews. *BMJ*. 2021;29:n71. <https://doi.org/10.1136/bmj.n71>
29. Aromataris E, Munn Z. *JBI Manual for Evidence Synthesis [Internet]*. Aromataris E, Munn Z, editors. JBI; 2020. Available from: <https://wiki.jbi.global/display/MANUAL>
30. Munn Z, Barker TH, Moola S, Tufanaru C, Stern C, McArthur A, et al. Methodological quality of case series studies: an introduction to the JBI critical appraisal tool. *JBI Evidence Synthesis*. 2020;18(10):2127–33. <https://doi.org/10.1112/JBISRIR-D-19-00099>
31. Patel S, Mavridou AM, Lambrechts P, Saberi N. External cervical resorption-part 1: histopathology, distribution and presentation. *Int Endod J*. 2018;51(11):1205–23. <https://doi.org/10.1111/iej.12942>
32. Ehlinger C, Ginies E, Bornert F, Bahi-Gross S, Schmittbuhl M, Minoux M. Decision criteria influencing the therapeutic approach to invasive cervical resorption: a case series. *Quintessence int*. 2019;50(6):494–502.
33. Makkes PC, Thoden van Velzen SK. Cervical external root resorption. *J Dent*. 1975;3(5):217–22. Available from: <https://linkinghub.elsevier.com/retrieve/pii/0300571275901268>
34. Frank AL. External-internal progressive resorption and its nonsurgical correction. *J Endod*. 1981;7(10):473–6. Available from: <https://linkinghub.elsevier.com/retrieve/pii/S009923998180310X>
35. Frank AL, Bakland LK. Nonendodontic therapy for supracrestal extracanal invasive resorption. *J Endod*. 1987;13(7):348–55. Available from: <https://linkinghub.elsevier.com/retrieve/pii/S0099239987801176>
36. Montgomery S. External cervical resorption after bleaching a pulpless tooth. *Oral Surg Oral Med Oral Pathol*. 1984;57(2):203–6. Available from: <https://linkinghub.elsevier.com/retrieve/pii/0030422084902135>
37. Hokett SD, Hoen MM. Inflammatory cervical root resorption following segmental orthognathic surgery. A case report. *J Periodontol*. 1998;69(2):219–26. <https://doi.org/10.1902/jop.1998.69.2.219>
38. Beertsen W, Piscaer M, Van Winkelhoff AJ, Everts V. Generalized cervical root resorption associated with periodontal disease. *J Clin Periodontol*. 2008;28(11):1067–73. <https://doi.org/10.1111/j.1600-051X.2001.281112.x>
39. Nagahara T, Takeda K, Aida Y, Iwata T, Yagi R, Kurihara H, et al. Combined endodontic and periodontal management of a class 3 invasive cervical resorption in a mandibular first molar. *Clin Case Rep*. 2018;6:2005–10.
40. Tonini R, Boschi G, Salgarello SA. Management of seven external cervical resorptions. *G Ital Endod*. 2020;34(2):13–29.
41. Howait M, Shaker M, Aljuhani H, AlMohnna M. External cervical resorption: a case report and brief review of the literature, and treatment algorithms. *J Contemp Dent Pract*. 2021;22(3):298–303. <https://doi.org/10.5005/jp-journals-10024-3013>
42. Krug R, Soliman S, Krastl G. Intentional replantation with an atraumatic extraction system in teeth with extensive cervical resorption. *J Endod*. 2019;45(11):1390–6. Available from: <https://linkinghub.elsevier.com/retrieve/pii/S0099239919305461>
43. Neto F, Pires MD, Ferreira M, Pereira B, Martins JNR, Vasconcelos I, et al. 3D diagnosis and management of external cervical resorption. *G Ital Endod*. 2020;34(2):44–52.
44. Cotti E, Schirru E. Present status and future directions: imaging techniques for the detection of periapical lesions. *Int Endod J*. 2022;55:1085–99. <https://doi.org/10.1111/iej.13828>
45. Nagendrababu V, Chong BS, McCabe P, Shah PK, Priya E, Jayaraman J, et al. Guidelines for reporting the quality of clinical case reports in endodontics: a development protocol. *Int Endod J*. 2019;52(6):775–8. <https://doi.org/10.1111/iej.13067>
46. Michelotto ALC, Koubik ACGA, Andrightto AR, Bueno ALN, Pupo YM. Multidisciplinary approach for the treatment of external cervical resorption: case report. *Dent Press Endod*. 2017;7(3):34–42. [10.14436/2F2358-2545.7.3.034-042.oar&partnerID=40&md5=587d8afbd6f87c68b0b46f5f284b6c57](https://doi.org/10.14436/2F2358-2545.7.3.034-042.oar&partnerID=40&md5=587d8afbd6f87c68b0b46f5f284b6c57)
47. Reston E, Bueno R, Closs L, Zettermann J. Fifteen-year clinical follow-up of restoration of extensive cervical resorption

- in a maxillary central incisor. *Oper Dent.* 2017;42(2):E55–8. Available from: <https://meridian.allenpress.com/operative-dentistry/article/42/2/E55/107742/Fifteenyear-Clinical-Follow-up-of-Restoration-of>
48. Smidt A, Nuni E, Keinan D. Invasive cervical root resorption: treatment rationale with an interdisciplinary approach. *J Endod.* 2007;33(11):1383–7. Available from: <https://linkinghub.elsevier.com/retrieve/pii/S009923990700711X>
 49. Heithersay G, Musu D, Cotti E. External tooth resorption associated with a peripheral odontogenic fibroma: review and case report. *Aust Dent J.* 2017;62(4):516–22. <https://doi.org/10.1111/adj.12544>
 50. Hata H, Abe M, Mayanagi H. Multiple lesions of intracoronal resorption of permanent teeth in the developing dentition: a case report. *Pediatr Dent.* 2007;29(5):420–5.
 51. Karypidou A, Chatziniolaou I-D, Kourou P, Koulaouzidou E, Economides N. Management of bilateral invasive cervical resorption lesions in maxillary incisors using a novel calcium silicate-based cement: a case report. *Quintessence Int.* 2016;47(8):637–42.
 52. Salzano S, Tirone F. Conservative nonsurgical treatment of class 4 invasive cervical resorption: a case series. *J Endod.* 2015;41(11):1907–12. Available from: <https://linkinghub.elsevier.com/retrieve/pii/S0099239915006913>
 53. Shemesh A, Ben Itzhak J, Solomonov M. Minimally invasive treatment of class 4 invasive cervical resorption with internal approach: a case series. *J Endod.* 2017;43(11):1901–8. Available from: <https://linkinghub.elsevier.com/retrieve/pii/S0099239917305587>
 54. Bharti R, Chandra A, Tikku AP, Prasad V, Shakya VK, Singhal R. Management of mucosal fenestration with external root resorption by multidisciplinary approach. *Case Rep.* 2014;2014:bcr2014206259–bcr2014206259;bcr2014206259. <https://doi.org/10.1136/bcr-2014-206259>
 55. Asgary S, Nosrat A. Conservative management of class 4 invasive cervical root resorption using calcium-enriched mixture cement. *J Endod.* 2016;42(8):1291–4. Available from: <https://linkinghub.elsevier.com/retrieve/pii/S0099239916302254>
 56. Asgary S, Nourzadeh M, Verma P, Hicks ML, Nosrat A. Vital pulp therapy as a conservative approach for management of invasive cervical root resorption: a case series. *J Endod.* 2019;45(9):1161–7. Available from: <https://linkinghub.elsevier.com/retrieve/pii/S0099239919304303>
 57. Duncan HF. Present status and future directions—vital pulp treatment and pulp preservation strategies. *Int Endod J.* 2022;55(S3):497–511. <https://doi.org/10.1111/iej.13688>
 58. Agrawal V, Kapoor S. Management of root canal stenosis and external inflammatory resorption by surgical root reconstruction using biodentine. *J Conserv Dent.* 2020;23(1):102 Available from: <http://www.jcd.org.in/text.asp?2020/23/1/102/297665>
 59. Tavares WLF, Oliveira RR, Ferreira MVL, Sobrinho APR, Braga T, Amaral RR. The use of antimicrobial photodynamic therapy in the successful management of an invasive cervical resorption class 4: a case report with five years follow-up. *Photodiagnosis Photodyn Ther.* 2021;33:102126 Available from: <https://linkinghub.elsevier.com/retrieve/pii/S1572100020304804>
 60. Roig M, Morelló S, Mercadé M, Durán-Sindreu F. Invasive cervical resorption: report on two cases. *Oral Surg Oral Med Oral Pathol Oral Radiol Endodontology.* 2010;110(4):e64–9. Available from: <https://linkinghub.elsevier.com/retrieve/pii/S1079210410001605>
 61. Gonzales JR, Rodekirchen H. Endodontic and periodontal treatment of an external cervical resorption. *Oral Surg Oral Med Oral Pathol Oral Radiol Endodontology.* 2007;104(1):e70–7. Available from: <https://linkinghub.elsevier.com/retrieve/pii/S1079210407000820>
 62. Sarmiento EB, Tavares SJ, Thuller KA, Falcao NP, de Paula KM, Antunes LA, et al. Minimally invasive intervention in external cervical resorption: a case report with six-year follow-up. *Int J Burns Trauma.* 2020;10(6):324–30.
 63. Ikhar A, Thakur N, Patel A, Bhede R, Patil P, Gupta S. Management of external invasive cervical resorption tooth with mineral trioxide aggregate: a case rep. *Case Rep Med.* 2013;2013:1–5. Available from: <http://www.hindawi.com/journals/crim/2013/139801/>
 64. Halboub E, Chourasia HR, Roges RA, Mashyakhly M, Chourasia HR, Halboub E, et al. Nonsurgical management and 2-year follow-up by means of cone beam computed tomography of an invasive cervical resorption in a molar. *J Contemp Dent Pract.* 2018;19(9):1152–6. <https://doi.org/10.5005/jp-journals-10024-2397>
 65. Parirokh M, Torabinejad M, Dummer PMH. Mineral trioxide aggregate and other bioactive endodontic cements: an updated overview – part I: vital pulp therapy. *Int Endod J.* 2018;51(2):177–205.
 66. Bonson S, Jeansonne BG, Lallier TE. Root-end filling materials Alter fibroblast differentiation. *J Dent res.* 2004;83(5):408–13. Available from: <http://www.ijpronline.com/ViewSpecialArticleDetail.aspx?ID=264>
 67. Chen C-L, Huang T-H, Ding S-J, Shie M-Y, Kao C-T. Comparison of calcium and silicate cement and mineral trioxide aggregate biologic effects and bone markers expression in MG63 cells. *J Endod.* 2009;35(5):682–5. <https://doi.org/10.1016/j.joen.2009.02.002>
 68. Fayad MI, Hawkinson R, Daniel J, Hao J. The effect of CO₂ laser irradiation on PDL cell attachment to resected root surfaces. *Oral Surg Oral Med Oral Pathol Oral Radiol Endod.* 2004;97(4):518–23.
 69. Hakki SS, Bozkurt SB, Hakki EE, Belli S. Effects of mineral trioxide aggregate on cell survival, gene expression associated with mineralized tissues, and biomineralization of cementoblasts. *J Endod.* 2009;35(4):513–9. <https://doi.org/10.1016/j.joen.2008.12.016>
 70. Torabinejad M, Parirokh M, Dummer PMH. Mineral trioxide aggregate and other bioactive endodontic cements: an updated overview - part II: other clinical applications and complications. *Int Endod J.* 2018;51(3):284–317. <https://doi.org/10.1111/iej.12843>
 71. Malkondu Ö, Kazandağ MK, Kazazoğlu E. A review on biodentine, a contemporary dentine replacement and repair material. *Biomed Res Int.* 2014;2014:1–10. Available from: <http://www.hindawi.com/journals/bmri/2014/160951/>
 72. Estafan D, Pines MS, Erakin C, Fuerst PF. Microleakage of class V restorations using two different compomer systems: an in vitro study. *J Clin Dent.* 1999;10(4):124–6. Available from: <http://www.ncbi.nlm.nih.gov/pubmed/10825860>
 73. Martins TM, Bosco AF, Nóbrega FJO, Nagata MJH, Garcia VG, Fucini SE. Periodontal tissue response to coverage of root cavities restored with resin materials: a histomorphometric

- study in dogs. *J Periodontol.* 2007;78(6):1075–82. <https://doi.org/10.1902/jop.2007.060457>
74. Murad MH, Sultan S, Haffar S, Bazerbachi F. Methodological quality and synthesis of case series and case reports. *BMJ Evid Based Med.* 2018;23(2):60–3. <https://doi.org/10.1136/bmjebm-2017-110853>
 75. Asgary S. Surgical management of large-perforated class 4 invasive cervical root resorption: a case report. *J Dent Sci.* 2022;18:484–5. <https://doi.org/10.1016/j.jds.2022.07.012>
 76. Bachesk AB, Queiroz AF, Bin L, Bachesk AB, Pavan AJ. Clinical approach to external cervical resorption in the anterior teeth: a case report study. *Iran Endod J.* 2021;16(2):118–22.
 77. Gión-Guerra B, Pérez-Lanza P, Almiñana-Pastor P, Micó-Martínez P, Alpiste-Illueca F, López-Roldán A. Performance of the dentogingival junction with mta and biodentine on the treatment of invasive cervical resorptions. A literature review and case report. *J Clin Exp Dent.* 2021;13(1):e95–8. Available from: <http://www.medicinaoral.com/medoralfree01/aop/57410.pdf>
 78. Aljarbou FA. Five-year recall after treatment of external cervical resorption. *Case Rep Dent.* 2019;20:1–5. Available from: <https://www.hindawi.com/journals/crid/2019/4957408/>
 79. Alqedairi A. Non-invasive management of invasive cervical resorption associated with periodontal pocket: a case report. *World J Clin Cases.* 2019;7(7):863–71. Available from: <https://www.wjgnet.com/2307-8960/full/v7/i7/863.htm>
 80. Mehra N, Yadav M, Kaushik M, Roshni R. Clinical management of root resorption: a report of three cases. *Cureus.* 2018;10:e3215.
 81. Patni PM, Jain P, Jain S, Hiremath H, Agarwal R, Patni MJ. Internal tunneling resorption associated with invasive cervical resorption. *J Conserv Dent.* 2018;21(1):105–8.
 82. Eftekhari L, Ashraf H, Jabbari S. Management of invasive cervical root resorption in a mandibular canine using biodentine as a restorative material: a case report. *Iran Endod J.* 2017;12(3):386–9.
 83. Fernandes M, Menezes L, De Ataíde I. Management of invasive cervical resorption using a surgical approach followed by an internal approach after 2 months due to pulpal involvement. *J Conserv Dent.* 2017;20(3):214 Available from: <http://www.jcd.org.in/text.asp?2017/20/3/214/218312>
 84. Lima TFR, Neto JV, Soares A d J. Diagnosis and management of root resorption in traumatized teeth: report of two cases. *Eur J Gen Dent.* 2017;6(3):127–30. https://www.scopus.com/inward/record.uri?eid=2-s2.0-85032881836&doi=10.4103%2Fejgd.ejgd_138_16&partnerID=40&md5=8e3f0dc67fd1988152e6b3a9e3666f06
 85. Tsaousoglou P, Markou E, Efthimiades N, Vouros I. Characteristics and treatment of invasive cervical resorption in vital teeth. A narrative review and a report of two cases. *Br Dent J.* 2017;222(6):423–8. Available from: <http://www.nature.com/articles/sj.bdj.2017.263>
 86. Lo Giudice G, Matarese G, Lizio A, Lo Giudice R, Tumedei M, Zizzari V, et al. Invasive cervical resorption: a case series with 3-year follow-up. *Int J Periodontics Restorative Dent.* 2016;36(1):103–9. Available from: <https://www.scopus.com/inward/record.uri?eid=2-s2.0-84984924959&doi=10.11607%2Fprd.2066&partnerID=40&md5=e11905d9251b63a93bb9de3084025cff>
 87. Patel B. Root resorption. Endodontic treatment, retreatment, and surgery. Cham: Springer International Publishing; Springer. 2016. p. 389–413 Available from: https://www.scopus.com/inward/record.uri?eid=2-s2.0-85019771633&doi=10.1007%2F978-3-319-19476-9_16&partnerID=40&md5=25ecd62b9188975cd886ad86b394215
 88. Yoshpe M, Kaufman A, Lin S, Gabay E, Einy S. Invasive cervical resorption following orthodontic treatment: two cases involving the same patient. *Quintessence Int.* 2016;47(10):877–84.
 89. Asgary S, Fazlyab M. Surgical repair of invasive cervical root resorption with calcium-enriched mixture cement: a case report. *Gen Dent.* 2015;63(1):37–40.
 90. Bal M, Yıldırım Ş, Saygun I. A case report of gingival enlargement associated with invasive cervical resorption. *Oper Dent.* 2015;40(2):117–22. Available from: <https://meridian.allenpress.com/operative-dentistry/article/40/2/117/206354/A-Case-Report-of-Gingival-Enlargement-Associated>
 91. Bhagabati N, Pruthi V, Nawal RR, Talwar S. Salvaging a tooth with extensive invasive cervical resorption. *Med J Armed Forces India.* 2015;71:S594–7. Available from: <https://www.scopus.com/inward/record.uri?eid=2-s2.0-84952629638&doi=10.1016%2Fj.mjafi.2014.04.008&partnerID=40&md5=0ddea87a596fd47bb34875aee4b88c50>
 92. Costa S, Oliveira J, Pinheiro S, Bueno CE, Ferrari P. Use of a tricalcium silicate cement in invasive cervical resorption. *Endo-Endodontic Pract Today.* 2015;9(3):193–200.
 93. Krishnan U, Moule AJ, Alawadhi A. Cone beam CT assisted re-treatment of class 3 invasive cervical resorption. *Case Rep.* 2015;2015:bcr2014204615. <https://doi.org/10.1136/bcr-2014-204615>
 94. Gürsoy H, Tanalp J, Yurdagüven H, Kayahan MB. Treatment of a cervical resorptive defect in a mandibular first premolar: an 18-month follow-up. *J Dent Sci.* 2014;9(4):412–6.
 95. Harris BT, Caicedo R, Lin W-S, Morton D. Treatment of a maxillary central incisor with class III invasive cervical resorption and compromised ferrule: a clinical report. *J Prosthet Dent.* 2014;111(5):356–61. Available from: <https://linkinghub.elsevier.com/retrieve/pii/S0022391313003211>
 96. Alves T, Soares T, Barreto S, Fried H, Pereira G, Maia L, et al. Multidisciplinary approach for the treatment of extensive external cervical resorption after dental trauma. *Oper Dent.* 2013;38(4):349–57. Available from: <https://meridian.allenpress.com/operative-dentistry/article/38/4/349/206107/Multi-disciplinary-Approach-for-the-Treatment-of>
 97. Gandhi P, Disha S. Treatment of maxillary central incisor with external root resorption using mineral trioxide aggregate: 18 months follow-up. *Case Rep.* 2013;2013(jul08 2):bcr2013200241. <https://doi.org/10.1136/bcr-2013-200241>
 98. Johns D, Shivashankar V, Maroli R, Joseph R. Invasive cervical root resorption: engineering the lost tissue by regeneration. *Contemp Clin Dent.* 2013;4(4):536 Available from: <http://www.contempclindent.org/text.asp?2013/4/4/536/123067>
 99. Tavares WLF, Lopes RCP, Oliveira RR, de Souza RG, Henriques LCF, Ribeiro-Sobrinho AP. Surgical management of invasive cervical resorption using resin-modified glass ionomer cement. *Gen Dent.* 2013;61(7):e16–8.
 100. Umer F, Adnan S, Raza KF. Conservative management of invasive cervical resorption: a case report. *J Dent (Tehran).* 2013;10(3):289–95.
 101. Kqiku L, Ebeleseder K, Glockner K. Treatment of invasive cervical resorption with Sandwich technique using mineral

- trioxide aggregate: a case report. *Oper Dent*. 2012;37(1):98–106. Available from: <https://meridian.allenpress.com/operative-dentistry/article/37/1/98/194147/Treatment-of-Invasive-Cervical-Resorption-With>
102. Fernández R, Rincón JG. Surgical endodontic management of an invasive cervical resorption class 4 with mineral trioxide aggregate: a 6-year follow-up. *Oral Surg Oral Med Oral Pathol Oral Radiol Endodontology*. 2011;112(5):e18–22. Available from: <https://www.scopus.com/inward/record.uri?eid=2-s2.0-80055097447&doi=10.1016%2Fj.tripleo.2011.04.028&partn erID=40&md5=d7b814628a0c68dbec890a9c57d66f49>
 103. Martos J, César Neto J, Silveira LF, Silveira C, Piovesan E. Clinical technique for invasive cervical root resorption. *J Conserv Dent*. 2011;14(4):440 Available from: <http://www.jcd.org.in/text.asp?2011/14/4/440/87225>
 104. Vinothkumar TS, Tamilselvi R, Kandaswamy D. Reverse sandwich restoration for the management of invasive cervical resorption: a case report. *J Endod*. 2011;37(5):706–10. Available from: <https://linkinghub.elsevier.com/retrieve/pii/S0099239911001105>
 105. Estevez R, Aranguren J, Escorial A, de Gregorio C, De La Torre F, Vera J, et al. Invasive cervical resorption class III in a maxillary central incisor: diagnosis and follow-up by means of cone-beam computed tomography. *J Endod*. 2010;36(12):2012–4.
 106. Yilmaz HG, Kalender A, Cengiz E. Use of mineral trioxide aggregate in the treatment of invasive cervical resorption: a case report. *J Endod*. 2010;36(1):160–3. Available from: <https://linkinghub.elsevier.com/retrieve/pii/S0099239909006190>
 107. Nikolidakis D, Nikou G, Meijer GJ, Jansen JA. Cervical external root resorption: 3-year follow-up of a case. *J Oral Sci*. 2008;50(4):487–91. Available from: http://www.jstage.jst.go.jp/article/josnusd/50/4/50_4_487/_article
 108. Park J-B, Lee J-H. Use of mineral trioxide aggregate in the non-surgical repair of perforating invasive cervical resorption. *Med Oral Patol Oral Cir Bucal*. 2008;13(10):E678–80.
 109. Patel S, Dawood A. The use of cone beam computed tomography in the management of external cervical resorption lesions. *Int Endod J*. 2007;40(9):730–7. Available from: <https://linkinghub.elsevier.com/retrieve/pii/S0099239907001744>
 110. Jensen A-L. External invasive resorption in a three-rooted lower first molar. *Aust Endod J*. 2006;32(2):70–4. Available from: <https://www.scopus.com/inward/record.uri?eid=2-s2.0-33749062789&doi=10.1111%2Fj.1747-4477.2006.00007.x&partn erID=40&md5=c993c6ca5b407025c8d784de54adf460>
 111. Baratto-Filho F, Limongi O, Araújo C d JR, Neto MDS, Maia SMAS, Albuquerque DS. Treatment of invasive cervical resorption with MTA: case report. *Aust Endod J*. 2005;31(2):76–80. <https://doi.org/10.1111/j.1747-4477.2005.tb00232.x>
 112. Patel K, Darbar UR, Gulabivala K. External cervical resorption associated with localized gingival overgrowth. *Int Endod J*. 2002;35(4):395–402. <https://doi.org/10.1046/j.0143-2885.2001.00509.x>
 113. Fernández R, Rincón JG. Surgical endodontic management of an invasive cervical resorption class 4 with mineral trioxide aggregate: a 6-year follow-up. *Oral Surg Oral Med Oral Pathol Oral Radiol Endodontology*. 2011;112(5):e18–22. Available from: <https://www.scopus.com/inward/record.uri?eid=2-s2.0-80055097447&doi=10.1016%2Fj.tripleo.2011.04.028&partn erID=40&md5=d7b814628a0c68dbec890a9c57d66f49>
 114. Nikolidakis D, Nikou G, Meijer GJ, Jansen JA. Cervical external root resorption: 3-year follow-up of a case. *J Oral Sci*. 2008;50(4):487–91. Available from: http://www.jstage.jst.go.jp/article/josnusd/50/4/50_4_487/_article

SUPPORTING INFORMATION

Additional supporting information can be found online in the Supporting Information section at the end of this article.

How to cite this article: Bardini G, Orrù C, Ideo F, Nagendrababu V, Dummer P, Cotti E. Clinical management of external cervical resorption: A systematic review. *Aust Endod J*. 2023;00:1–19. <https://doi.org/10.1111/aej.12794>