

Idiopathic Pyoderma Gangrenosum: Successful Resolution with Infliximab Therapy and Pro-inflammatory Cytokines Assessment

Stefano R. Del Giacco*, Davide Firinu*, Maria Maddalena Lorrari, Loredana Serusi, Raffaella Meleddu, Maria Pina Barca, Monica Peralta and Paolo Emilio Manconi

Allergy & Clinical Immunology Unit, University of Cagliari, University Hospital, Asse Didattico E1, IT-09042 Monserrato Cagliari, Italy. E-mail: stedg@medicina.unica.it

Accepted October 3, 2011.

*Both authors contributed equally to this work and should be considered as first authors.

Pyoderma gangrenosum (PG) is a rare neutrophilic dermatosis of unknown aetiology, characterized by primarily sterile, painful ulcers with typical violaceous undermined borders and mucopurulent or haemorrhagic exudate. PG is commonly associated with other systemic disorders. Diagnosis of primary idiopathic forms is reached following the exclusion of inflammatory bowel disease (IBD), rheumatic disorders, monoclonal gammopathy and solid tumours (1, 2). Treatment is generally based on corticosteroid and immunosuppressive therapy; however, the recent use of biological drugs has shown their effectiveness.

CASE REPORT

A 51-year-old man affected by non-healing ulcers on both legs was referred to our outpatients' clinic in February 2010. The patient reported the presence of multiple cutaneous pustule-like lesions on both lower limbs and the left arm since September 2009 and that they had increased in size and evolved into spontaneous ulceration, accompanied by fever (38°C) and nocturnal sweating. Following hospitalization, a clinical diagnosis of PG was first suspected and later confirmed by cutaneous biopsy. Investigations for underlying pathologies causing PG were negative.

Oral steroid therapy with prednisone (1 mg/kg/day) was commenced, but no response was observed over the following 2 months; cyclosporin A (5 mg/kg/day) was also introduced with no improvement. The patient was admitted to our unit in March 2010, presenting malaise, fever (up to 38°C) and multiple painful oval-shaped ulcerative lesions on both legs with bleeding and fibrinoid bed, necrotic areas, irregular and undermined margins with violaceous borders. The lesions were localized to the right antero-lateral tibial area (9 × 6 cm), right lower posterior tibial area (9 × 6 cm), right postero-superior tibial area (1.5 × 1 cm), and lateral area of the right foot (2.5 × 2.5 cm); there was an ulcer on the left knee (3.5 × 3.5 cm), another in the dorso-lateral region of the left foot (3.5 cm main diameter) and a granulomatoid lesion on the lateral supramalleolar surface.

Histopathological review revealed extensive necrosis with infiltration by mixed inflammatory cells, extending to the subcutaneous fat. This infiltrate, composed predominantly of neutrophils with formation of micro-abscesses, confirmed the diagnosis of ulcerative PG.

Laboratory investigations showed neutrophilic leukocytosis (up to 30,000/mm³), erythrocyte sedimentation rate (ESR) 62 mm/h and C-reactive protein (CRP) 12.18 mg/dl. Screening for autoantibodies and thrombophilia were negative.

Serum cytokines tumour necrosis factor- α (TNF- α) and interleukin (IL)-6 were elevated; 14.6 pg/ml (normal < 5 pg/ml) and 66.41 pg/ml (< 4 pg/ml), respectively. Comprehensive gastrointestinal and haematological evaluation showed no associated disease. The patient did not report any prior overt tuberculosis, but purified protein derivative and interferon- γ release assay tests were both

positive, indicating a latent tuberculosis infection (LTBI). Tests for mycobacteria and fungi in lesions were negative.

Ultrasound and computed tomography revealed one splenic abscess (18 mm); magnetic resonance imaging showed a liquid-filled lesion with peripheral contrast enhancement, suggesting an abscess of the left calf. Contrast-enhanced ultrasound confirmed a hypoechoic dishomogeneous oval formation (maximum diameter 8 × 3 cm) with perilesional vascular flows. Two courses of high-dose intravenous methylprednisolone, 1 g/day for 5 days, in conjunction with cyclosporin A, failed to stabilize or block ulcer enlargement. Due to lack of response to conventional therapy, an "off-label" treatment with intravenous infliximab (Remicade®, Schering-Plough Italia SpA, Segrate-Milano, Italy) was commenced at 5 mg/kg. This resulted in the prompt normalization of leukocytosis and inflammatory markers. An initial trend towards lesion regression was observed one week after the first infusion, with reduction of the exudation and of ulcer inflammation and appearance of granulation tissue.

Active tuberculosis was ruled out and treatment for LTBI with rifampicin and isoniazid was commenced concurrently with the TNF- α antagonist. Infusion was repeated at 2 and 6 weeks and then at 8-week intervals together with methotrexate (20 mg/week). Prednisone (50 mg/day) was tapered to 10 mg/day over 2 months. Three months after the commencement of treatment, a single lesion on the right calf remained, while all the other lesions were markedly improved. After 12 months the patient is doing well without disease exacerbation or relapse. Photographs of the cutaneous ulcers on admission (Fig. 1A, B), after 3 months (Fig. 1C), 5 months (Fig. 1D), and 12 months (Fig. 1E) are shown. Infliximab is currently administered at 8-week intervals, together with methotrexate (15 mg/week) and prednisone (5 mg/day).

DISCUSSION

Standard treatment for PG includes local wound management and topical or systemic immunosuppression. High-dose oral or intravenous corticosteroids are the mainstay of therapy, most often in association with immunomodulators (3). In this study, the efficacy of infliximab-based treatment of idiopathic ulcerative variant of PG with widespread and progressive course is reported; in fact TNF- α inhibiting agents have led to excellent therapeutic responses in severe forms of PG refractory to the above-mentioned therapies (4), mostly associated with IBD or with other underlying conditions (3, 5, 6), although a few clinical experiences in idiopathic PG have been reported (4, 7–11).

Though rarely described, splenic and muscle involvement were also present (9, 12, 13). Neutrophilic abscesses in spleen and muscles were present. These rarely reported findings (9, 12, 13) resolved completely with therapy.

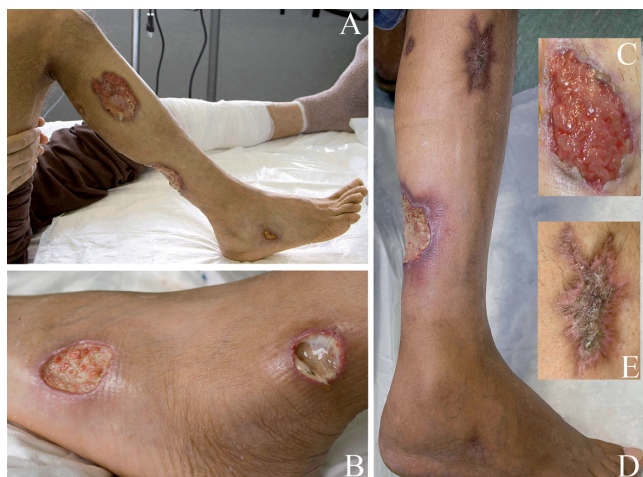

Fig. 1. (A) Typical lesions of pyoderma gangrenosum over the right leg and calf on admission prior to infliximab treatment. (B) Lesions on admission: left ankle and foot. (C) Left knee lesion after 3 months. (D) Lesions after 5 months: right limb. (E) Antero-lateral tibial area: after 12 months.

As reported recently, the overproduction of TNF- α plays an important role in neutrophilic dermatoses (14). TNF- α is a pro-inflammatory cytokine that acts as a pivotal regulator of other cytokines, including IL-1 β , IL-6 and IL-8, which are involved in inflammation, acute-phase response induction and chemotaxis. In accordance with other authors (7, 15), we demonstrate here that increased serum levels of TNF- α and IL-6 can also be found in the idiopathic form of PG and were normalized after starting treatment with infliximab (Fig. 2). We chose to initiate infliximab therapy with an induction course (5 mg/kg at weeks 0, 2 and 6), taking into account the observations of Adisen et al. (10).

A reduction in ulcer inflammation was seen within the first week and all of the ulcers, except the right calf lesion, completely healed after 6 months.

Tapering of the prednisone dose to 5 mg/day after clinical remission was not associated with a relapse of the disease.

Our data further support the pivotal role of TNF- α in the pathogenesis of this disease, and that cytokine

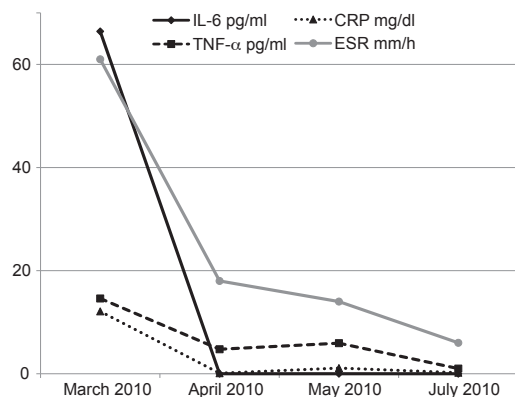


Fig. 2. Evolution of levels of cytokines and inflammatory markers over the first 4 months of infliximab treatment. IL-6: interleukin-6; CRP: C-reactive protein; TNF- α : tumour necrosis factor-alpha; ESR: erythrocyte sedimentation rate.

monitoring may represent an accurate marker of disease activity and response to therapy.

ACKNOWLEDGEMENTS

The authors would like to thank Barry Mark Wheaton for his invaluable linguistic assistance and Dr Cristina Pedditzi, Dr Antonio Floris and Dr Raffaele Deidda for their advice.

REFERENCES

1. Ruocco E, Sangiuliano S, Gravina AG, Miranda A, Nicoletti G. Pyoderma gangrenosum: an updated review. *J Eur Acad Dermatol Venereol* 2009; 23: 1008–1017.
2. Cohen PR. Neutrophilic dermatoses: a review of current treatment options. *Am J Clin Dermatol* 2009; 10: 301–312.
3. Reichrath J, Bens G, Bonowitz A, Tilgen W. Treatment recommendations for pyoderma gangrenosum: an evidence-based review of the literature based on more than 350 patients. *J Am Acad Dermatol* 2005; 53: 273–283.
4. Brooklyn TN, Dunnill MG, Shetty A, Bowden JJ, Williams JD, Griffiths CE, et al. Infliximab for the treatment of pyoderma gangrenosum: a randomised, double blind, placebo controlled trial. *Gut* 2006; 55: 505–509.
5. Regueiro M, Valentine J, Plevy S, Fleisher MR, Lichtenstein GR. Infliximab for treatment of pyoderma gangrenosum associated with inflammatory bowel disease. *Am J Gastroenterol* 2003; 98: 1821–1826.
6. Swale VJ, Saha M, Kapur N, Hoffbrand AV, Rustin MH. Pyoderma gangrenosum outside the context of inflammatory bowel disease treated successfully with infliximab. *Clin Exp Dermatol* 2005; 30: 134–136.
7. Jenne L, Sauter B, Thumann P, Hertl M, Schuler G. Successful treatment of therapy-resistant chronic vegetating pyoderma gangrenosum with infliximab (chimeric antitumour necrosis factor antibody). *Br J Dermatol* 2004; 150: 380–382.
8. Kaur MR, Lewis HM. Severe recalcitrant pyoderma gangrenosum treated with infliximab. *Br J Dermatol* 2005; 153: 689–691.
9. Hubbard VG, Friedmann AC, Goldsmith P. Systemic pyoderma gangrenosum responding to infliximab and adalimumab. *Br J Dermatol* 2005; 152: 1059–1061.
10. Adışen E, Öztaş M, Güre MA. Treatment of idiopathic pyoderma gangrenosum with Infliximab: induction dosing regimen or on-demand therapy? *Dermatology* 2008; 216: 163–165.
11. Marzano AV, Turlaki A, Alessi E, Caputo R. Widespread idiopathic pyoderma gangrenosum evolved from ulcerative to vegetative type: a 10-year history with a recent response to infliximab. *Clinical Exp Dermatol* 2008; 33: 156–159.
12. Marie I, Levesque H, Joly P, Reumont G, Courville P, Baudrimont M, et al. Neutrophilic myositis as an extra-cutaneous manifestation of neutrophilic dermatosis. *J Am Acad Dermatol* 2001; 44: 137–139.
13. Vadillo M, Jucgla A, Podzamczar D, Rufi G, Domingo A. Pyoderma gangrenosum with liver, spleen and bone involvement in a patient with chronic myelomonocytic leukaemia. *Br J Dermatol* 1999; 141: 541–543.
14. Marzano AV, Cugno M, Trevisan V, Fanoni D, Venegoni L, Berti E, et al. Role of inflammatory cells, cytokines and matrix metalloproteinases in neutrophil-mediated skin diseases. *Clin Exp Immunol* 2010; 162: 100–107.
15. Kawakami T, Yamazaki M, Soma Y. Reduction of interleukin-6, interleukin-8, and anti-phosphatidylserine-prothrombin complex antibody by granulocyte and monocyte adsorption apheresis in a patient with pyoderma gangrenosum and ulcerative colitis. *Am J Gastroenterol* 2009; 104: 2363–2364.