

Immunoreactivity for thymosin beta 4 and thymosin beta 10 in the adult rat oro-gastro-intestinal tract

S. Nemolato,¹ J. Ekstrom,² T. Cabras,³
C. Gerosa,¹ D. Fanni,¹ E. Di Felice,¹
A. Locci,¹ I. Messana,³ M. Castagnola,⁴
G. Faa¹

¹Istituto di Anatomia Patologica, Dipartimento di Scienze Chirurgiche, PO S. Giovanni di Dio, Università di Cagliari, Italy;

²Division of Pharmacology, Institute of Neuroscience and Physiology, Sahlgrenska Academy, University of Gothenburg, Sweden;

³Dipartimento di Scienze della Vita e dell'Ambiente, Università di Cagliari, Italy;

⁴Istituto di Biochimica e Biochimica Clinica, Facoltà di Medicina, Università Cattolica di Roma, Italy

Abstract

Thymosin beta 4 (Tβ4) and thymosin beta 10 (Tβ10) are two members of the β-thymosin family, involved in multiple cellular activities in different organs in multiple animal species. Here we report the expression pattern of Tβ4 and Tβ10 in rat tissues, in the gut and in annexed glands. The two peptide were differently expressed: Tβ4 was absent in salivary glands whereas Tβ10 was expressed in parotid and in submandibular glands. Tβ4 was mildly expressed in the tongue and in the oesophagus, where Tβ10 was absent. A similar expression was found in the stomach, ileum and colon mucosa. In pancreas Tβ4 reactivity was restricted to the Langerhans islet cells; Tβ4 was also detected in the exocrine cells. Both peptide were not expressed in liver cells. When the rat expression pattern in rat organs was compared to reactivity for Tβ4 and Tβ10 in humans, marked differences were found. Our data clearly indicate a species-specific expression of Tβ4 and Tβ10, characterized by the actual unpredictability of the expression of these peptides in different cells and tissues. The common high expression of Tβ4 in mast cells, both in humans and in rats, represents one of the few similarities between these two species.

Introduction

Beta thymosins are a versatile family of small peptides expressed in multiple tissues in mammals, that show many intracellular and extracellular activities.^{1,2} These peptides are named *thymosins* after their first isolation in the calf thymus.³ Fifteen highly homologous beta thymosin variants, containing 40 to 44 amino acid residues, have been described.⁴ Among beta thymosins, thymosin beta 4 (Tβ4)^{5,6} and thymosin beta 10 (Tβ10)⁷ are the most abundant in human cells and rat tissues.⁸ During the years, beta thymosins have been detected inside of cells of different organs,⁹⁻¹⁴ as well as in human blood,¹⁵ in human saliva,¹⁶ in tears¹⁷ and in wound fluid after abdominal surgery.¹⁸ Many physiological properties and cellular functions are connected to Tβ4: G-actin-sequestering,¹ promotion of cell migration,⁸ angiogenesis,^{9,19} stem cell differentiation,¹¹ modulation of cytokines and chemokines.²⁰ This peptide is also involved in lesion-induced neuroplasticity through microglia upregulation and it participates in the growth of neuronal processes.²¹ Therefore, the mRNA encoding for Tβ4 is expressed in mouse embryonic stem cells and in mesodermal-like cells (cardiac and skeletal muscle).²² Moreover, recent studies demonstrated a role of Tβ4 in inducing the expression of the vascular endothelial growth factor (VEGF) in colon cancer cells in experimental models.¹⁹ Tβ4 also participates to the modulation of human colonic immune system²³ probably through degranulation of mucosal mast cells.²⁴ Contrasting results have been published on the role of Tβ10 in tumour progression. On one hand, Tβ10 diminishes tumor growth, angiogenesis and proliferation²⁵ and Tβ10 over-expression has been related to the increase of apoptosis in human ovarian cancer cells.²⁵ On the other hand, Tβ10 has been associated to the progression of papillary thyroid carcinoma²⁶ and over-expression of the peptide has been observed in non-small cell lung cancer²⁷ and in pancreatic cancer.²⁸ The recent report by our group of a strong expression for Tβ10 in the human salivary glands during development,²⁹ induced us to better analyse the protein expression pattern for Tβ10 in the oro-gastro-intestinal tract in adult rats, in order to show if Tβ10 is expressed in the gastrointestinal tract in adulthood, and to compare the expression of this peptide with that reported in the human digestive tract and in annexed glands.^{24,30,31} Moreover, rat tissues were immunostained for Tβ4, with the aim of verifying the reciprocal interactions of Tβ4 and Tβ10 in the oro-gastrointestinal tract.

Correspondence: Sonia Nemolato, Istituto di Anatomia Patologica, Dipartimento di Scienze Chirurgiche, PO S. Giovanni di Dio, Università di Cagliari, via Università 60, 09124 Cagliari, Italy. Tel. +39.070.6092370 - Fax: +39.070.657882. E-mail: sonianemolato@libero.it

Key words: rats, thymosin beta 4, thymosin beta 10, immunohistochemistry, gastrointestinal tract.

Contributions: SN, GF, research design and manuscript writing; JE, CM, IM, critical review; TC, CG, DF, EDF, AL, data analysis and research performing.

Conflicts of interest: the authors declare no conflicts of interest.

Acknowledgments: this work has been supported by "Fondazione Banco di Sardegna". The authors would like to thank Mr. Ignazio Ferru for the secretarial assistance. The authors also gratefully acknowledge the Sardinia Regional Government for the financial support (P.O.R. Sardegna F.S.E. Operational Programme of the Autonomous Region of Sardinia, European Social Fund 2007-2013 - Axis IV Human Resources, Objective 1.3, Line of Activity 1.3.1 *Avviso di chiamata per il finanziamento di Assegni di Ricerca*).

Received for publication: 21 January 2013.

Accepted for publication: 5 April 2013.

This work is licensed under a Creative Commons Attribution NonCommercial 3.0 License (CC BY-NC 3.0).

©Copyright S. Nemolato et al., 2013
Licensee PAGEPress, Italy
European Journal of Histochemistry 2013; 57:e17
doi:10.4081/ejh.2013.e17

Materials and Methods

In order to test Tβ4 and Tβ10 immunoreactivity in animals, 20 male wistar rats were the object of our study, divided into 10 male and 10 female. Tissues were obtained from each animal including samples from tongue, oesophagus, stomach, ileum, colon, parotid gland, submandibular gland, sublingual gland, liver and pancreas. All samples were fixed in 10% formalin, paraffin-embedded and routinely processed. Paraffin sections were immunostained with anti-Tβ4 and anti-Tβ10 antibodies, using the labeled streptavidin-biotin complex system (LSAB2, Dako) in a Dako Autostainer (Dako Cytomation, Carpinteria, CA, USA). Briefly, samples were deparaffinized, rehydrated, and endogenous peroxidase activity was quenched (30 min) by 0.3% hydrogen peroxide in

methanol. Slides were then subjected to heat-induced antigen retrieval by steaming unstained sections in a Target Retrieval Solution (Dako TRS pH 6.1) for 30 min. Slides were then incubated with 10% normal goat serum in phosphate-buffered saline (PBS) for 60 min to block non-specific binding, followed by incubation (60 min at room temperature) with a monoclonal anti-Thymosin Beta 4 antibody (Bachem-Peninsula Lab, San Carlos, CA, USA) and with a monoclonal anti-Thymosin Beta 10, respectively diluted 1:600 and 1:500 in the blocking solution. Slides were extensively washed with PBS containing 0.01% Triton X-100 and incubated with a secondary reagent

Table 1. Immunoreactivity for thymosin beta 4 (T β 4) and thymosin beta 10 (T β 10) in rat tissues and humans.

| Organ | T β 4 Rat | T β 10 Rat | T β 4 Human | T β 10 Human |
|---------------------|-----------------|------------------|-------------------|--------------------|
| Parotid | - | +++ | + | + |
| Submandibular gland | - | +++ | + | + |
| Sublingual gland | - | - | + | + |
| Tongue | + | - | + | ++ |
| Oesofagus | - | - | + | - |
| Stomach | + | + | + | - |
| Ileum | + | + | + | - |
| Colon | + | + | ++ | - |
| Pancreas | + | ++ | ++ | + |
| Liver | - | - | +++ | +++ |

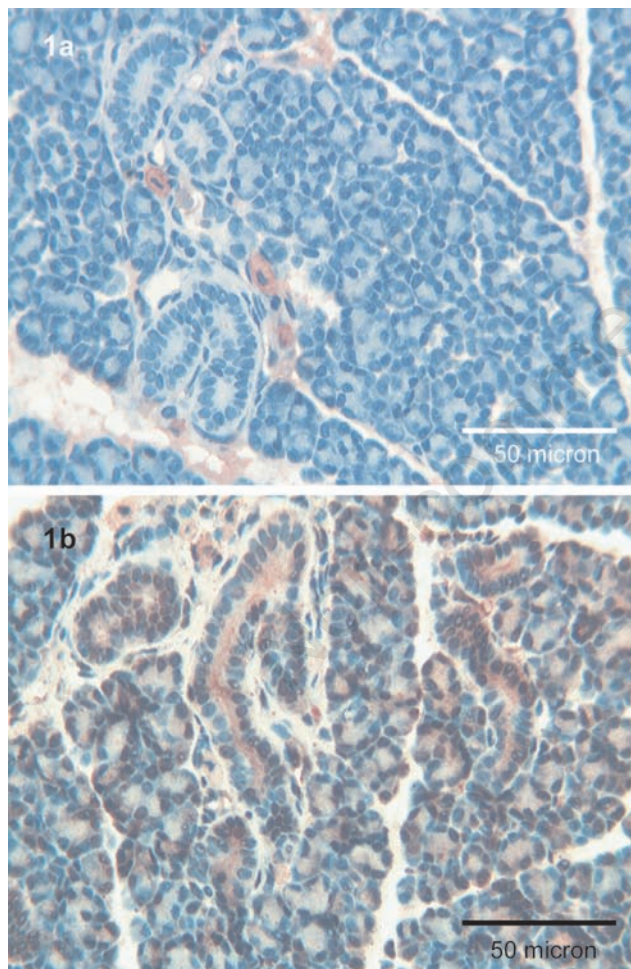


Figure 1. Parotid. a) No immunoreactivity for T β 4 is detected in the parotid gland; scattered mast cells are strongly immunoreactive for the peptide; OM 250x. **b)** A granular and diffuse positivity for T β 10 is observed in all the acinar structures; ductal cells show an apical and homogeneous reactivity for the peptide; OM 400x.

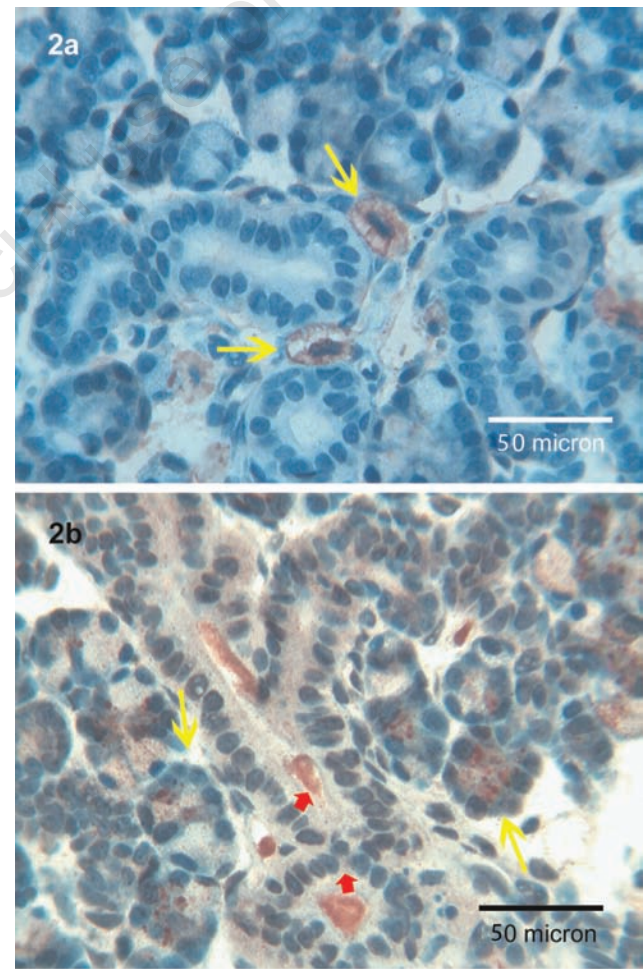


Figure 2. Submandibular glands. a) T β 4 is not expressed in the structures of the submandibular glands; only a fine positivity could be detectable in the surrounding stroma; mast cells show a strong granular cytoplasmic positivity (yellow arrows); OM 400x. **b)** Coarse granules of T β 10 are observed in the acini of the submandibular gland (yellow arrows); ductal cells present a fine cytoplasmic immunoreactivity for the peptide mainly localized in the lumen (red arrows); OM 400x.

(En Vision kit) according with the manufacturer instructions (Dako, Glostrup, Denmark). Diaminobenzidine (DAB) was used as chromogen. After additional washes, colour was developed using the AEC reagent (Dako), sections were counterstained with Mayer's hematoxylin and mounted. Sections of reactive lymph nodes with T β 4-immunoreactive histiocytes were utilized as a positive control. As a negative control, the same procedure was applied omitting the primary antibody.

Results

Parotid

T β 4 immunoreactivity was completely absent both in acini and in ducts (Figure 1a). T β 10 was expressed both in acinar serous

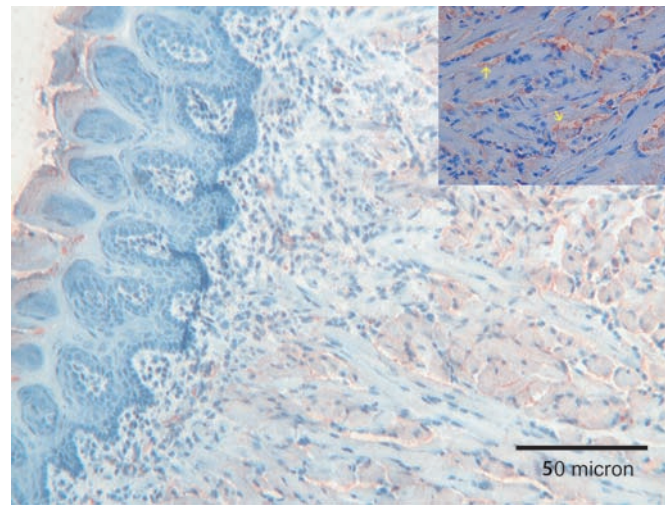


Figure 3. Tongue. A weak immunoreactivity for T β 4 is observed only in the superficial layers of the tongue's epithelium; a weak immunostaining for the peptide was observed in cell membranes of muscle cells (see inset, yellow arrows); OM 250x.

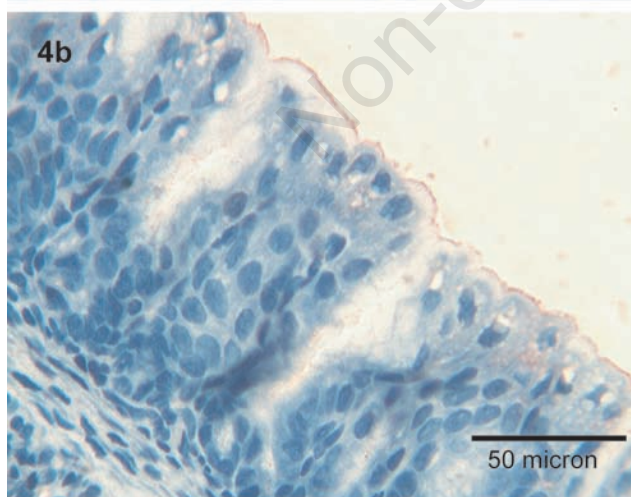
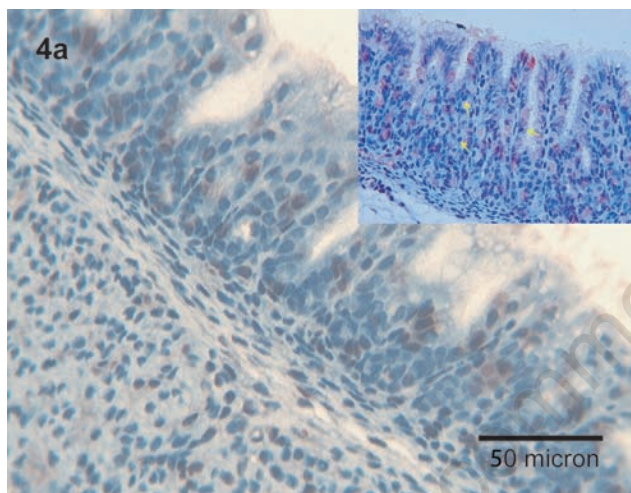


Figure 4. Stomach. a) Immunoreactivity for T β 4 is expressed in scattered foveolar cells (see inset, yellow arrows) and in the luminal surface of the stomach; OM 400x. b) T β 10 is mainly localized in the luminal border of the foveolar cells of the stomach; OM 250x.

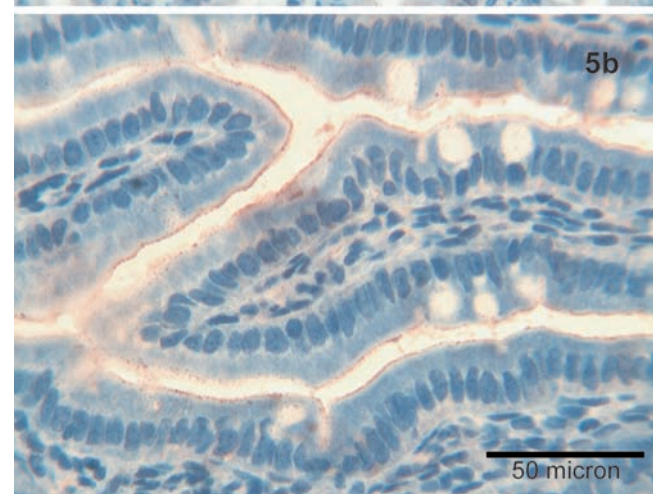
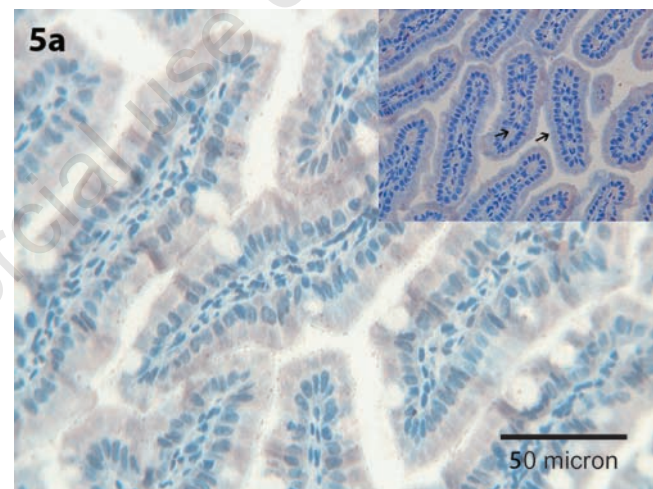


Figure 5. Ileum. a,b) T β 4 and T β 10 are detected in the surface epithelium of enterocytes covering the villi of the ileum (see inset, black arrows); OM 400x.

cells, showing a granular pattern, as well as in ductal cells, in which a homogeneous cytoplasmic staining was detected (Figure 1b).

Submandibular gland

Fine T β 4-immunoreactive granules were observed in the periglandular stroma and in scattered mast cells, in the absence of any reactivity inside the salivary gland cells (Figure 2a). A strong reactivity for T β 10 was observed in acinar serous cells, appearing as coarse granules and in mucous cells appearing as fine granules. The ducts show a homogeneous cytoplasmic staining and intraluminal granular deposits (Figure 2b).

Sublingual glands

No reactivity was detected for T β 4 and for T β 10.

Tongue

A mild immunoreactivity for T β 4 was detected in the superficial layers of the stratified epithelium. Moreover, a weak immunostaining for the peptide was observed in muscle cells, mainly localized at the cell membrane (Figure 3). No reactivity for T β 10 was found.

Oesophagus

Scattered T β 4-immunoreactive granules were detected inside the oesophageal lumen. No reactivity for T β 10 was observed.

Stomach

Immunoreactivity for T β 4 was restricted to scattered foveolar cells and to intraluminal granular deposits (Figure 4a). A similar expression pattern was observed for T β 10 (Figure 4b).

Ileum

T β 4 was mainly expressed in the cytoplasm of enterocytes covering ileal villi (Figure 5a). A similar pattern characterized immunoreactivity for T β 10 (Figure 5b).

Colon

T β 4 was mainly expressed at the apical pole of enterocytes, and in fine granular deposits inside the intestinal lumen (Figure 6a), paralleling the expression pattern observed for T β 10 (Figure 6b).

Pancreas

T β 4 immunoreactivity was restricted to Langerhans islets, in the absence of any significant immunostaining in the exocrine pancreas (Figure 7a). On the contrary, T β 10 was

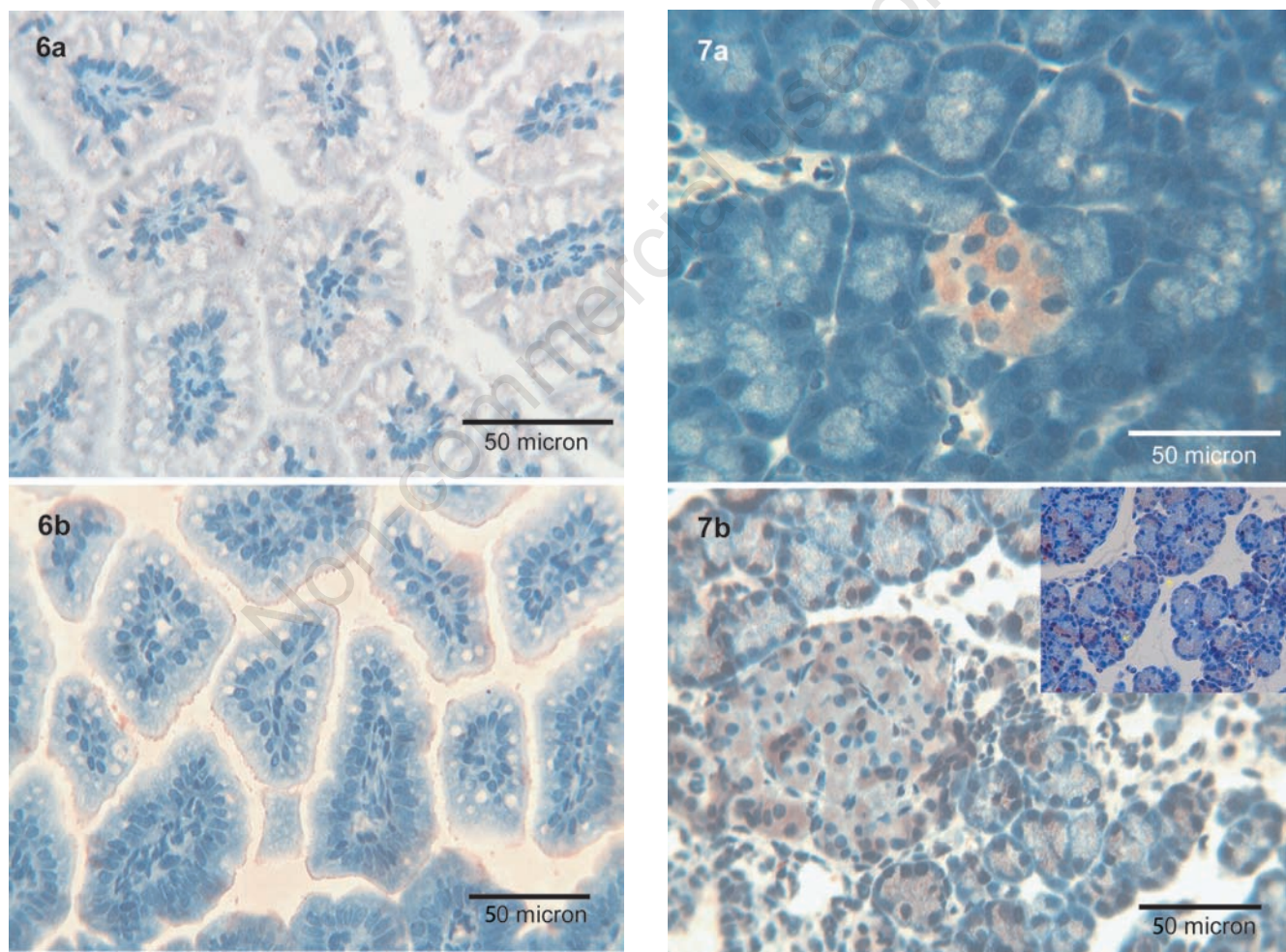


Figure 6. Colon. a,b) A fine granular positivity for T β 4 is observed in the brush border of the enterocytes in the surface epithelium of the colon and in the intestinal lumen; T β 10 parallels the immunoreactivity of T β 4; OM 400x.

Figure 7. Pancreas. a) T β 4 is diffusely immunexpressed in the islets of Langerhans; no immunoreactivity is observed in the rest of pancreatic parenchyma; OM 400x. b) Immunoreactivity for T β 10 is localized both in islets of Langerhans and in the acini (see inset); the latest show a fine granular positivity in the absence of ductal reactivity; OM 400x.

detected both in the exocrine and in the endocrine pancreas. Endocrine cells of the Langerhans islets showed a strong cytoplasmic reactivity, whereas in acinar cells T β 10 was mainly detected in granular deposits. No immunostaining was found in ductal cells nor inside the tubular lumen (Figure 7b).

Liver

No reactivity for T β 4 and T β 10 was observed in the liver samples. Data regarding immunoreactivity for both thymosins in the different rat organs are summarized in Table 1.

Discussion

The role of T β 4 and T β 10, the beta-thymosins expressed virtually in all mammalian tissues and cells, has not been completely clarified yet. Previous studies on their expression in the rat central nervous system evidenced that temporal and cellular patterns of their expression are different, suggesting that each beta-thymosin could play a specific physiological function during development and in adulthood.³² Our study confirms the existence of marked differences in the distribution of T β 4 and T β 10 in the oro-gastro-intestinal tract of the adult rat. The most striking differences were found in the parotid and submandibular glands, in which T β 4 was absent whereas immunostaining for T β 10 was strong and diffuse. On the contrary, no reactivity for both beta-thymosins was detected in sublingual glands. These differences in beta-thymosin expression between different salivary glands confirm that each beta-thymosin probably plays a specific role in each salivary gland, irrespectively of their common embryogenesis.

No significant difference in T β 4 and T β 10 expression was present in the gastrointestinal tract: the absence of reactivity for both beta-thymosins in the oesofagus contrasts with the presence of both peptides in the enterocytes of the remaining gastrointestinal tract, confirming that a patchy distribution of these peptides should be expected, even in different parts of the same system.

The peculiar pattern for beta thymosins detected in pancreas deserves some considerations: T β 10 was strongly expressed both in the exocrine and in the endocrine cells, whereas T β 4 reactivity was restricted to the Langerhans islet cells. These findings taken together clearly indicate the presence of a complex modulation in the expression of beta-thymosins inside the same organ, each thymosin playing different functions in different cell types, confirming the *β -thymosin enigma*.³³

When data obtained in rat tissues were com-

pared with immunoreactivity for T β 4 and T β 10 in human tissues, significant differences were evidenced, supporting the hypothesis that beta-thymosin expression in cells and tissues is species-specific. The most striking differences were found in liver specimens, characterized by the complete absence of both thymosins in rat, contrasting with the strong and diffuse reactivity for T β 4 and T β 10 previously reported in humans.³⁴ However, which is the role of T β 4 and T β 10 in adult rat tissues? The detailed mechanisms of the action of T β 4 and T β 10 in different mammalian cells and tissues are not fully understood, as well as the similarities and differences between these isoforms.³⁵ Previous studies evidenced that activities of these two beta-thymosins are paradoxically different, T β 4 promoting cell migration and angiogenesis, and T β 10 inhibiting angiogenesis.³⁵ Opposing effects on angiogenesis are likely to be mediated via T β 4 stimulation and T β 10 inhibition of VEGF production.³⁶

Moreover, in contrast to T β 4, T β 10 has been shown to be a negative regulator of tumor development and progression.³⁷ In short, T β 4 might promote cell survival by blocking apoptosis,³⁸ whereas T β 10 might exert a proapoptotic activity, by accelerating apoptotic cell death.³⁹ According with these data, we may speculate that the complex and pleiotropic expression of T β 4 and T β 10 here reported in different tissues and cell types might reflect different direct and indirect effects on the actin cytoskeleton, as well as modulation of signaling pathways that impact on different cellular functions. In particular, over-expression of T β 4 could be related to prevention of apoptosis by blocking early apoptotic signals,⁴⁰ whereas overexpression of T β 10 might be related to its pro-apoptotic activity and to a down-regulation of cell growth³⁵ and of angiogenesis.³⁶

Finally, this study, one of the few in which the immunohistochemical expression pattern of T β 4 and T β 10 has been paralleled in the same tissues, evidenced that detailed mechanisms of the action of beta-thymosins in different cells and tissues are not fully understood, and show that our lack of knowledge is particularly evident regarding mature adult tissues, the vast majority of studies on the role of beta-thymosins having been carried out in fetal or tumoral tissues. Further studies exploring the molecular events that are associated with T β 4 and T β 10 overexpression or down-regulation are required, in order to give a solution to the thymosin enigma.

References

1. Hannappel E. β -Thymosins. *Ann NY Acad Sci* 2007;1112:21-37.

2. Mannherz HG, Hannappel E. The β -thymosins: intracellular and extracellular activities of a versatile actin binding protein family. *Cell Motil Cytoskeleton* 2009;66:839-51.
3. Klein JJ, Goldstein AL, White A. Enhancement of in vivo incorporation of labeled precursors into DNA and total protein of mouse lymph nodes after administration of thymic extracts. *Proc Natl Acad Sci USA* 1965;53:812-7.
4. Hannappel E, Davoust S, Horecker BL. Isolation of peptides from calf thymus. *Biochem Biophys Res Commun.* 1982;104:266-71.
5. Low TL, Goldstein AL. Chemical characterization of thymosin β_4 . *J Biol Chem* 1982;257:1000-6.
6. Hannappel E, Xu GJ, Morgan J, Hemstead J, Horecker BL. Thymosin β_4 : a ubiquitous peptide in rat and mouse tissues. *Proc Natl Acad Sci USA* 1982;79:2172-5.
7. Ericksson-Viitanen S, Ruggieri S, Natalini P, Horecker BL. Thymosin Beta 10, a new analogue of thymosin beta 4 in mammalian tissues. *Arch Biochem Biophys* 1983;225:407-13.
8. Yu FX, Lin SC, Morrison-Bogoard M, Atkinson MA, Yin HL. Thymosin beta 10 and thymosin beta 4 both actin sequestering proteins. *J Biol Chem* 1993;268:502-9.
9. Philp D, Goldstein AL, Kleinman HK. Thymosin T β 4 promotes angiogenesis, wound healing, and hair follicle development. *Mech Ageing Dev* 2004;125:113-5.
10. Bock-Marquette I, Saxena A, White MD, Dimaio JM, Srivastava D. Thymosin T β 4 activates integrin-linked kinase and promotes cardiac cell migration, survival and cardiac repair. *Nature* 2004;432:466-72.
11. Smart N, Risebro CA, Melville AA, Moses K, Schwartz RJ, Chien KR, et al. Thymosin T β 4 induces adult epicardial progenitor mobilization and neovascularization. *Nature* 2007;445:177-82.
12. Hall AK. Differential expression of thymosin genes in human tumors and in developing human kidney. *Int J Cancer* 1991;48:672-7.
13. Sun W, Kim H. Neurotrophic roles of the beta-thymosins in the development and regeneration of the nervous system. *Ann NY Acad Sci* 2007;1112:210-8.
14. Nemolato S, Cabras T, Fanari MU, Cau F, Fanni D, Gerosa C, et al. Immunoreactivity of Thymosin beta 4 in human foetal and adult genitourinary tract. *Eur J Histochem* 2010;54:e43.
15. Naylor PH, McClure JE, Spangelo BL, Low TL, Goldstein AL. Immunochemical studies on thymosin: radioimmunoassay of thymosin beta 4. *Immunopharmacology* 1984; 7:9-16.

16. Inzitari R, Cabras T, Pisano E, Fanali C, Manconi B, Scarano E, et al. HPLC-ESI-MS analysis of oral human fluid reveals that gingival crevicular fluids are the main source of oral thymosin T β 4 and β 10. *J Sep Sci* 2009;32:57-63.
17. Badamchian M, Fagarasan MO, Danner RL, Suffredini AF, Damavandy H, Goldstein AL. Thymosin beta(4) reduces lethality and down regulates inflammatory mediators in endotoxin-induced septic shock. *Int Immunopharmacol* 2003;3:1225-33.
18. Bodendorf S, Born G, Hannappel E. Determination of thymosin beta4 and protein in human wound fluid after abdominal surgery. *Ann NY Acad Sci* 2007;1112: 418-24.
19. Jo JO, Kim SR, Bae MK, Kang YJ, Ock MS, Kleinman HK, et al. Thymosin β 4 induces the expression of vascular endothelial growth factor (VEGF) in a hypoxia-inducible factor (HIF)-1-dependent manner. *Biochim Biophys Acta* 2010;1803: 1244-51.
20. Crockford D, Turjman N, Allan C, Angel J. Thymosin beta4: structure, function, and biological properties supporting current and future clinical applications. *Ann NY Acad Sci* 2010;1194:179-89.
21. Paulussen M, Landuyt B, Schoofs L, Luyten W, Arckens L. Thymosin beta 4 mRNA and peptide expression in phagocytic cells of different mouse tissues. *Peptides* 2009;30: 1822-32.
22. Gómez-Márquez J, Franco del Amo F, Carpintero P, Anadón R. High levels of mouse thymosin beta4 mRNA in differentiating P19 embryonic cells and during development of cardiovascular tissues. *Biochim Biophys Acta* 1996;1306:187-93.
23. Elitsur Y, Mutchnick MG, Sakr WA, Luk GD. Thymosin alpha 1 and thymosin beta 4 modulate human colonic lamina propria lymphocyte function. *Immunopharmacology* 1990;20:89-96.
24. Nemolato S, Cabras T, Fanari MU, Cau F, Frascini M, Manconi B, et al. Thymosin beta 4 expression in normal skin, colon mucosa and in tumor infiltrating mast cells. *Eur J Histochem* 2010;54:e3.
25. Kim YC, Kim BG, Lee JH. Thymosin β 10 expression driven by the human TERT promoter induces ovarian cancer-specific apoptosis through ROS production. *PLoS One* 2012;7:e35399.
26. Fehér LZ, Pocsay G, Krenács L, Zvara A, Bagdi E, Pocsay R, et al. Amplification of thymosin beta 10 and AKAP13 genes in metastatic and aggressive papillary thyroid carcinomas. *Pathol Oncol Res* 2012; 18:449-58.
27. Lee SM, Na YK, Hong HS, Jang EJ, Yoon GS, Park JY, et al. Hypomethylation of the thymosin β (10) gene is not associated with its overexpression in non-small cell lung cancer. *Mol Cells* 2011;32:343-8.
28. Li M, Zhang Y, Zhai Q, Feurino LW, Fisher WE, Chen C, et al. Thymosin beta-10 is aberrantly expressed in pancreatic cancer and induces JNK activation. *Cancer Invest* 2009; 27:251-6.
29. Fanni D, Gerosa C, Nemolato S, Locci A, Marinelli V, Cabras T, et al. Thymosin beta 10 expression in developing human salivary glands. *Early Hum Dev* 2011;87:779-83.
30. Nemolato S, Messana I, Cabras T, Manconi B, Inzitari R, Fanali C, et al. Thymosin beta(4) and beta(10) levels in pre-term newborn oral cavity and foetal salivary glands evidence a switch of secretion during foetal development. *PLoS One* 2009; 4:e5109.
31. Nemolato S, Cabras T, Cau F, Fanari MU, Fanni D, Manconi B, et al. Different thymosin Beta 4 immunoreactivity in foetal and adult gastrointestinal tract. *PLoS One* 2010;5:e9111.
32. Gomez-Marquez J, Anadon R. The beta-thymosins, small actin-binding peptides widely expressed in the developing and adult cerebellum. *Cerebellum* 2002;1:95-102.
33. Sun HQ, Yin HL. The β -thymosin enigma. *Ann NY Acad Sci* 2007;1112:45-55.
34. Nemolato S, Van Eyken P, Cabras T, Cau F, Fanari MU, Locci A, et al. Expression pattern of thymosin beta 4 in the adult human liver. *Eur J Histochem* 2011;55:e25.
35. Sribenja S, Li M, Wongkham S, Wongkham C, Yao Q, Chen C. Advances in thymosin beta 10 research: differential expression, molecular mechanisms, and clinical implications in cancer and other conditions. *Cancer Invest* 2009; 27:1016-22.
36. Lee SH, Son MJ, Oh SH, Rho SB, Park K, Kim YJ, et al. Thymosin beta 10 inhibits angiogenesis and tumor growth by interfering with Ras function. *Cancer Res* 2005;65:137-48.
37. Freeman KW, Banyard J. Beta-thymosin in cancer: implications for the clinic. *Future Oncol* 2009;5:755-8.
38. Sosne G, Qui P, Goldstein AL, Wheeler M. Biological activities of thymosin beta4 defined by active sites in short peptide sequences. *FASEB J* 2010;24:2144-51.
39. Hall AK. Thymosin beta-10 accelerates apoptosis. *Cell Mol Biol Res* 1995;41:167-80.
40. Choi SY, Kim DK, Eun B, Kim K, Sun W, Kim H. Anti-apoptotic function of thymosin-beta in developing chick spinal motoneurons. *Biochem Biophys Res Commun* 2006;346:872-8.