



Review

External hernia of the supramesical fossa: Rare or simply misidentified?



G. Amato ^{a,*}, G. Romano ^b, E. Erdas ^c, F. Medas ^c, L. Gordini ^c, F. Podda ^c, P. Calò ^c

^a Postgraduate School of General Surgery, University of Cagliari, Italy

^b Department of General Surgery and Urgency University of Palermo, Italy

^c Department of General Surgery, University of Cagliari, Italy

HIGHLIGHTS

- The study aims to provide the surgical community with clinical data concerning hernias of the supramesical fossa.
- Demonstrate that the frequency seems to be underestimated.
- Deepening this topic may result useful in adequately managing this hernia type.

ARTICLE INFO

Article history:

Received 11 January 2017

Received in revised form

24 March 2017

Accepted 27 March 2017

Available online 29 March 2017

Keywords:

Keywords: hernia

Inguinal hernia

Supramesical fossa hernia

Combined hernia

Incarceration

Hernia classification

ABSTRACT

Background: External hernias of the supramesical fossa are considered rare, perhaps wrongly. Highlighting clinical and anatomical features could be useful for correct, preoperative diagnosis, thus avoiding the risk of complications such as incarceration. The study aims to demonstrate that the incidence of external protrusions of the supramesical fossa is higher than supposed. Probably, being mistaken for direct hernias, these hernia types are misidentified and not included in current classifications. This issue deserves attention due to the elevated risk of incarceration related to its distinctive structure.

Material and methods: 249 consecutive open anterior inguinal hernia procedures were analyzed. Hernias were categorized according to the Nyhus classification. A subgroup of direct hernias involved true hernias of the supramesical fossa. Multiple ipsilateral, as well as combined hernias having a multi-component structure, were also considered.

Results: 13 true hernias of the supramesical fossa and 19 multiple ipsilateral or combined hernias composed of direct and/or indirect hernia, together with one hernia of the supramesical fossa were identified. 4 true hernias of the supramesical fossa presented signs of incarceration. In three other combined protrusions, the herniated component of the supramesical fossa also showed incarceration of the visceral content.

Conclusions: Hernias of the supramesical fossa would appear to be more frequent than imagined. These protrusions show a diverticular shape and the base is often tightened by the stiffer medial umbilical fold. This explains the apparently higher tendency to incarceration that distinguishes this hernia type. Pre-operative signs of inguinal pain and irreducibility are pathognomonic for correct diagnosis. In these cases, surgical treatment in the short term is recommended.

© 2017 IJS Publishing Group Ltd. Published by Elsevier Ltd. All rights reserved.

1. Introduction

Hernia of the supramesical fossa is considered rare. In literature, two types of supramesical hernias are described: internal and external [1]. A bulge may protrude through the supramesical fossa,

which may develop in different directions. The protrusions that emerge through the cranial aspect of the fossa usually generate external hernias, while those expanding into the inferior area generally penetrate the prevesical space of Retzius originating an internal hernia [2]. In brief, these two kinds of hernias simply differ in the path of the protrusion: an internal hernia does not cross the abdominal wall and remains restricted in the preperitoneal space, presenting with the prevesical, paravesical, lateral or intravesical

* Corresponding author. Via Rapisardi 66, I – 90144 Palermo, Italy.

E-mail address: amatomed@gmail.com (G. Amato).

variant [2,3]. An external hernia passes through the abdominal wall expanding into the inguinal canal medially of the medial inguinal fossa. Internal supravesical hernias are infrequently diagnosed, being reported almost exclusively when an intestinal obstruction occurs [4–6]. Little scientific literature refers to external supravesical inguinal hernias. To date, very few studies exist regarding the gross anatomical differences between supravesical and direct protrusions detected during inguinal hernia repair. The reason would seem to be that, being essentially neglected, supravesical hernias are probably mistaken for direct hernias and, consequently, not correctly acknowledged. Intraoperative evidence in the frame of open anterior hernia repair shows that hernias of the supravesical fossa can protrude alone, in combination with a direct hernia, in the form of a dual component combined hernia, or in the tricomponent version, when the protrusion involves all three inguinal fossae [7]. In some patients, this hernia type can also protrude as a separate component of multiple ipsilateral hernias. In the light of this, one can assume that these protrusions are more frequent than imagined. The present report is focused on describing the anatomical aspects of external hernias of the supravesical fossa. Highlighting and further studying its features could probably help surgeons in adequately identifying this protrusion type, thus adopting an appropriate strategy for accurate preoperative diagnosis and surgical treatment.

2. Material and methods

Incidence and features of external hernias of the supravesical fossa observed in patients who underwent anterior open inguinal hernia repair represent the subject of the report. These protrusions, listed in a single operator case series, include 249 consecutive open inguinal hernia procedures. All operated subjects were male. Hernias were categorized using the Nyhus classification, except for hernias arising from the supravesical fossa as these hernia types are not considered in any classification in literature. Protrusions were registered as indirect (Nyhus 1 and Nyhus 2), direct (Nyhus 3a), combined hernias (Nyhus 3b) and multiple ipsilateral hernias. Direct hernias were further divided into 2 subgroups: the former included hernias protruding from just the medial inguinal fossa, while the latter subgroup involved true hernias of the supravesical fossa. Combined hernias were divided into three subcategories: bi-component combined protrusions having indirect + direct components, bi-component hernias composed of a direct hernia + supravesical fossa protrusion, as well as combined protrusions with a tri-component structure: direct, indirect + supravesical fossa hernias merging into one single protrusion. Multiple ipsilateral hernias were also included in the assessment. Due to scanty reports on the subject, and with the intent to exhaustively detail its features, particular care was

Table 1

Total patients enrolled, demographics and hernia types. Main hernia types and related amount are evidenced in blue, subgroups in white.

Total patients enrolled		Nr. 249	100%
Age (median)	52,71 years (range 20 – 81)		
BMI (median)	28,1 (range 21 – 36)		
Hernia types			
Indirect		111	44,5
Direct (total)		60	24,0
Direct hernia– subgroup 1: Hernia of the fossa inguinalis media		47	18,8
Direct hernia – subgroup 2: Hernia of the fossa supravesicalis		13 (4 incarcerated)	5,2
Combined (total)		47	18,8
Combined – subgroup 1: bi-component protrusion composed by direct + indirect hernia		8	3,2
Combined – subgroup 2: bi-component protrusion composed by direct + fossa vesicalis hernia		16 (3 incarcerated)	6,4
Combined – subgroup 3: tri-component protrusion (direct + indirect + fossa vesicalis components)		23	9,2
Multiple ipsilateral (separated direct and/or indirect and/or supravesical hernias)		32	11,6
Bi- or Tri-component ipsilateral hernias (separate protrusions composed by direct and/or indirect + supravesical hernia)		3	1,1

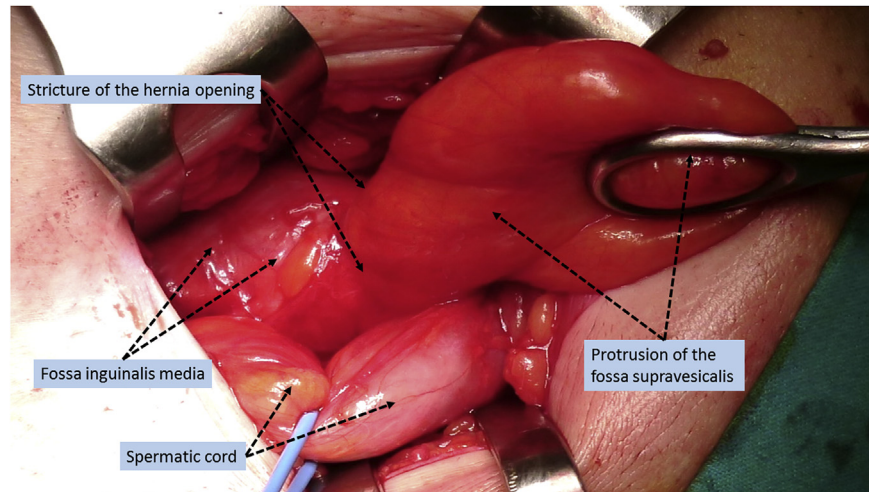


Fig. 1. Sacculation in the right groin protruding from the supravescalis fossa. A stricture at the level of the medial umbilical fold tightens the base of the hernia. Protrusion expands distally of the stricture, developing a diverticular outline.

devoted to highlighting the anatomical characteristics of hernias of the supravescalis fossa and its variants while drafting the study design. Careful description of the hernia components contributed significantly to finalizing this commitment, with the support of image data. Surgical technique carried out for the treatment of the protrusions was not an objective of the study and, therefore, not discussed in the report.

3. Results

In the total of 249 patients that form the body of the investigation, the median age was 52.71 years (range 20–81), median BMI 28.1 (range 21–36). Among these patients, there were 111 indirect hernias (5 Nyhus 1 and 106 Nyhus 2, of which 6 congenital) and 60 direct hernias (Nyhus 3a). In the direct hernias, the subgroup 1 showed 47 protrusions arising from just the medial inguinal fossa and 13 true hernias of the supravescalis fossa. Combined hernias (Nyhus 3b), 47 in total, were further subcategorized into 8 bi-component combined protrusions having indirect + direct

components, 16 bi-component protrusions composed of one direct + supravescalis fossa protrusion, 23 units having a tri-component structure (direct + indirect + supravescalis fossa hernias merging together). Additionally, 32 multiple ipsilateral hernias were detected. Among these multiple hernias there were three double Nyhus 1, one Nyhus 2 + supravescalis hernia, 26 Nyhus 2 + 26 Nyhus 3a, one Nyhus 3a + one supravescalis hernia and one triple ipsilateral hernia composed of 3 separate protrusions: one direct + one indirect + one hernia of the supravescalis fossa (Table 1).

The 13 true external hernias of the supravescalis fossa detected in the frame of the study, showed identical distinctive elements: all had a diverticular shape. The hernia sac showed a narrowing at the level of the medial umbilical fold that tightened the protrusion at origin. Distally from the hernia opening, the sac clearly expanded taking on a diverticular aspect (Fig. 1). In 4 of the 13 patients who had preoperative irreducible protrusion and pain, intraoperatively the stricture of the hernia opening was so tight as to cause incarceration of the herniated content, sometimes showing ischemic

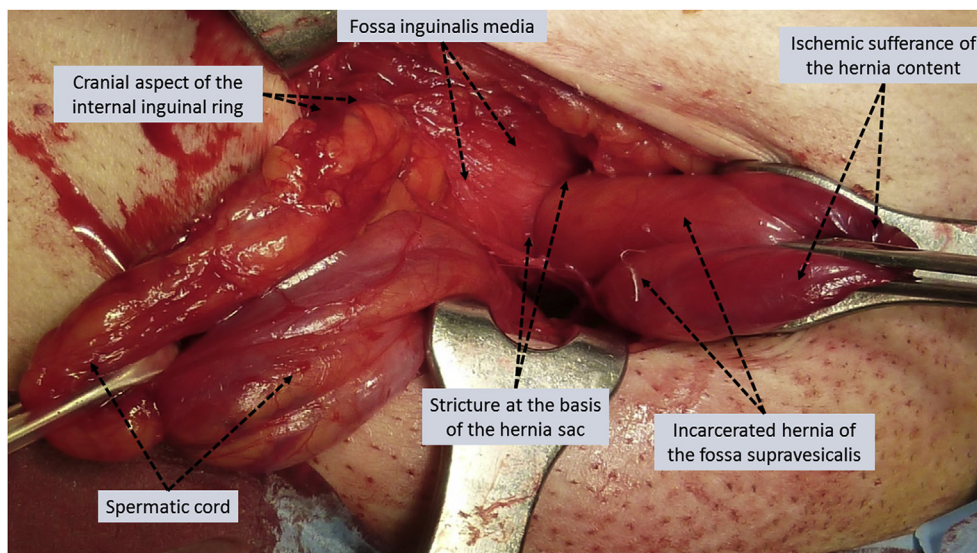


Fig. 2. In the right groin, medially of the medial inguinal fossa, an incarcerated hernia of the supravescalis fossa protrudes. The hernia opening, at the level of the medial umbilical fold is very tight and forms a stricture that compresses the content, causing ischemic sufferance.

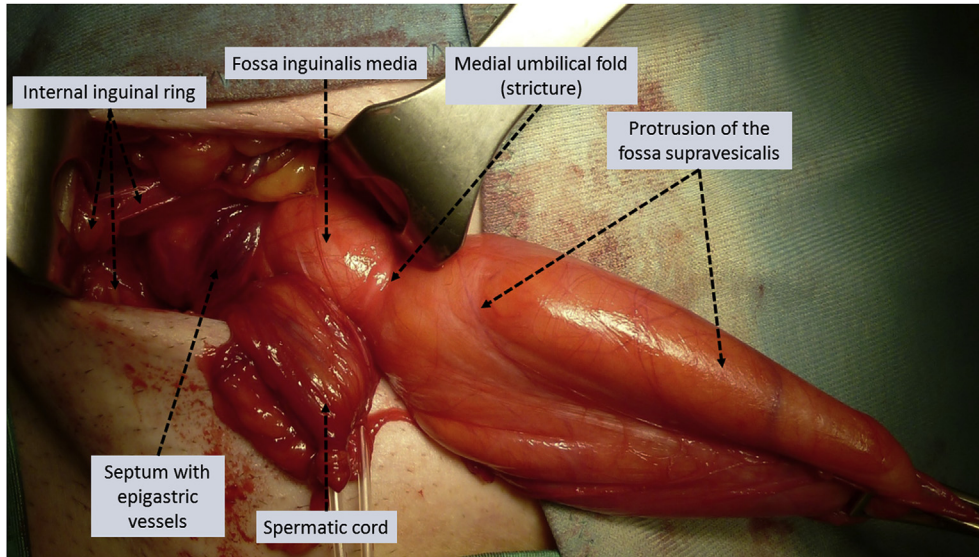


Fig. 3. Diverticular protrusion of the supravescal fossa in the right inguinal floor. The medial umbilical fold tightens the protrusion at the base. The medial fossa is simply covered by the trasversalis fascia. Of note, the septal arrangement composed of epigastric vessels and sheath limiting the deep ring.

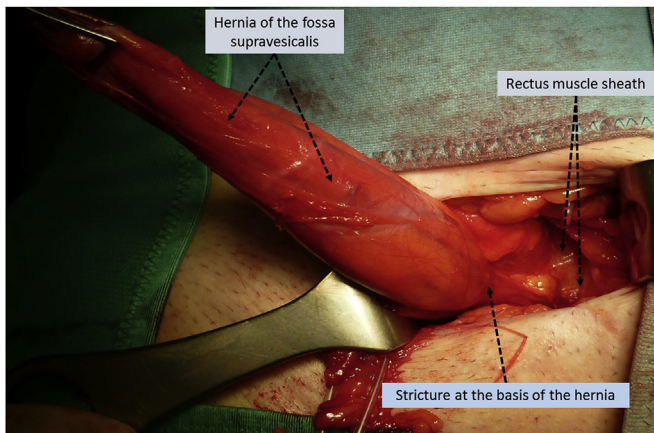


Fig. 4. Same patient as Fig. 3. Medial aspect of the supravescal hernia close to the lateral margin of the rectus sheath.

sufferance of the content (Fig. 2). In this case, releasing the stricture with scissors allowed for recovery of blood perfusion and no resection of the visceral content was needed.

Concerning the boundaries, the supravescal hernia was delimited laterally by the remnant of the umbilical vessels and the medial inguinal fossa (Fig. 3) and medially, by the lateral margin of the rectus sheath (Figs. 4 and 5A).

Among the reported 47 combined hernias, 23 combined hernias showed the typical aspect of large protrusions ranging from the supravescal fossa through the medial inguinal fossa to the lateral aspect of the internal ring where, occasionally, the supravescal component was dominant because of the larger dimension. (Fig. 5B). This is what we define as a tri-component combined hernia, with all three sections of the inguinal floor being involved in

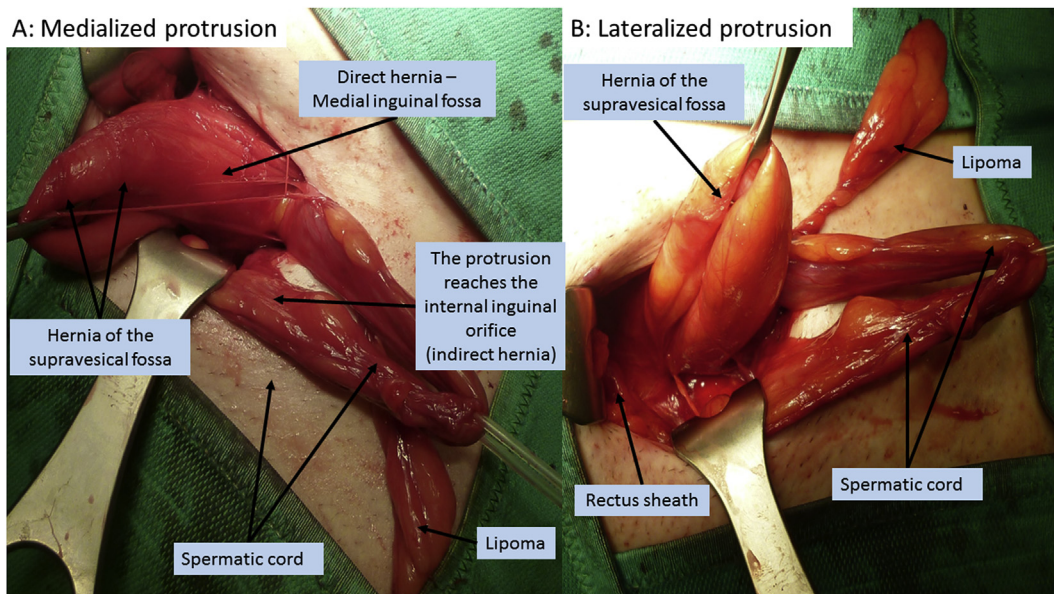


Fig. 5. Tricomponent combined hernia composed of three confluent protrusions. Additionally, a preperitoneal lipoma arises laterally from the spermatic cord. A) The combined protrusion dislocated medially shows the involvement of all three inguinal fossae, from the supravescal through the medial until the lateral, being the extent of the supravescal component clearly dominant in dimensions. B) In the same patient, the lateralization of the protrusion demonstrates the typical diverticular shape of the supravescal hernia close to the lateral margin of the rectus sheath.

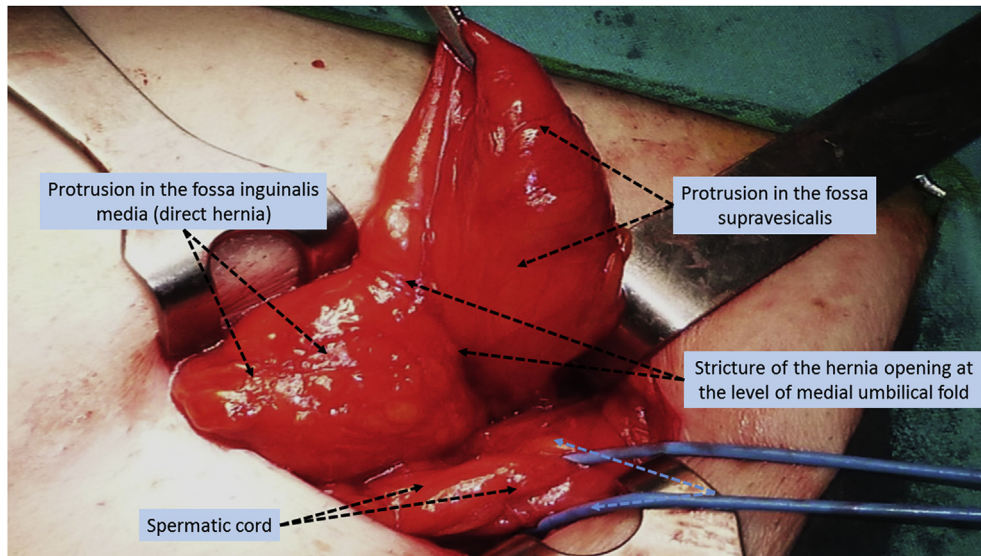


Fig. 6. Bi-component combined hernia of the right groin, composed of an external hernia of the supravesical fossa and a direct hernia. The two protrusions are delimited by the medial umbilical fold, which moderately narrows the hernia opening.

the disbanding of the backwall. In these cases, the medial aspect of the internal ring and the inferior epigastric vessels were missing thus allowing the confluence of the three components of the inguinal floor: the lateral, the medial and the supravesical. The remaining 8 protrusions showed the involvement of the medial inguinal fossa and the internal ring. In 16 patients, a supravesical fossa protrusion was detected in combination with direct hernia in the form of a bi-component combined hernia. In these cases, the medial umbilical fold often delimited the merging of the two protrusions (Fig. 6). In three cases, the imprint of the medial umbilical fold evidently constrained the supravesical component and its visceral content, but without impairment of blood perfusion (Fig. 7). The three incarcerated protrusions of this subgroup, together with the other 4 identified among the true hernias of the supravesical fossa, were the only incarcerated hernias of the entire

patient cohort.

In our patient series, three multiple ipsilateral hernias were also detected with the involvement of a supravesical protrusion. Of these, one was composed of an indirect hernia + supravesical hernia (Fig. 8), one showed a direct hernia separated by a supravesical protrusion (Fig. 9) and a third showed three distinct protrusions arising from the inguinal floor: one supravesical, one direct and one indirect. These protrusions, separated by a small tissue strip, were not confluent [8].

4. Discussion

Supravesical fossa is a triangular area delimited laterally and above by the medial umbilical ligament, which covers the remnants of the umbilical arteries. The fossa is medially bordered by the urachus and below by the peritoneal fold that separates the anterior abdominal wall from the dome of the bladder (Fig. 10). Protrusions originating from the supravesical fossa have been described for more than two centuries [9] and during the ages named as “inner inguinal herniae” [10], “anterior retroperitoneal” [11], “properitoneal” [12], as well as “prevesical” [13]. Nevertheless, the currently used term hernia of the supravesical fossa was first proposed by Waldeyer in 1884 [14].

External hernia of the supravesical fossa is deemed to be rare. Given this, it makes sense to read that there are “fewer than 100 cases reported in literature” [15]. In light of the results displayed in the present report, notwithstanding the relatively limited number of enrolled patients, this statement is quite discrepant. In this regard, it is worth noting what Chandler reported in the mid 1900s. In his observational study, involving 268 body-halves of both sexes, 12 direct hernias were found in Hesselbach’s triangle. Summarizing this evidence, Chandler stated: “Seven of the direct herniae were in the supravesical fossa and five in the middle inguinal fossa.” [16] This should further indicate that external hernia of the supravesical fossa is possibly confused between direct or combined hernias and, therefore, registered among these hernia types. This likely depends on the lack of-knowledge concerning the existence of protrusions of the supravesical fossa. Indeed, no mention of this type of hernia exists in any classification attempts made throughout the past two centuries, even in the latest EHS classification [17–20]. Further

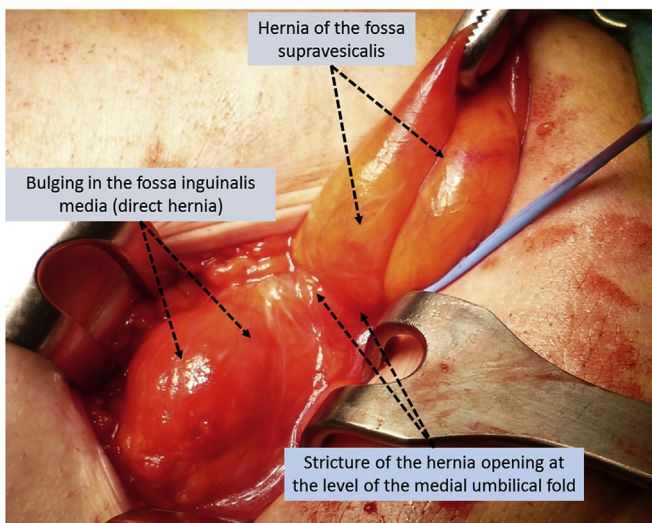


Fig. 7. Right-sided bi-component combined hernia formed by a protrusion of the supravesical fossa and a direct hernia. The two protrusions are separated by the medial umbilical fold, which evidently constrains the content of the protrusion emerging from the supravesical fossa.

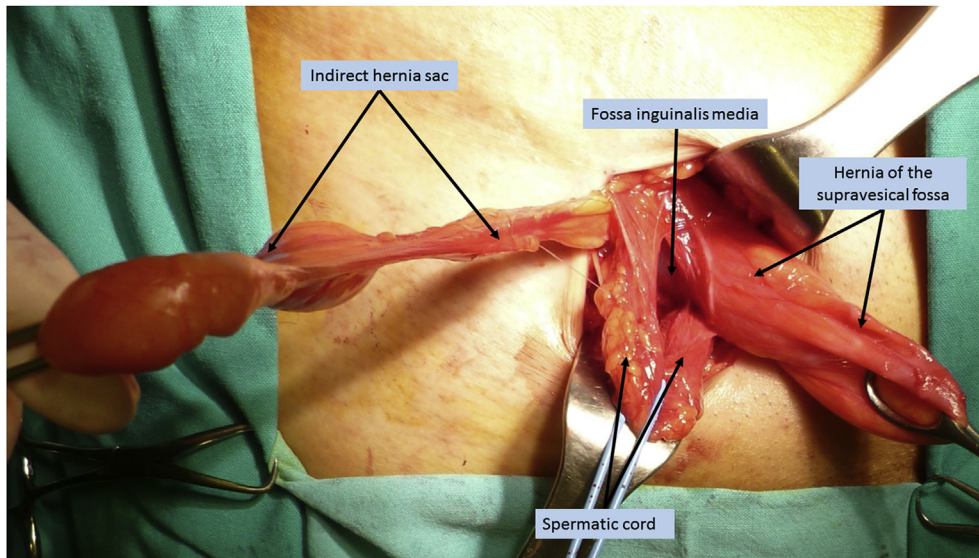


Fig. 8. Double ipsilateral inguinal hernia composed of two separated protrusions: one indirect and a second one, arising through the supravescical fossa, showing a diverticular outline. The medial inguinal fossa is intact.

confirmation on this misperception derives from the description made by Gilbert [21]. In his classification, direct hernias are listed in two subgroups: type IV and V. Gilbert textually describes hernia type IV arising from the medial inguinal fossa and type V as protruding medially to it. The author states: “Types IV and V are direct hernias type V has a diverticular defect which is usually no more than one finger breadth wide in the canal floor”. This description seems to prove that type V of the Gilbert classification fully corresponds, in location and diverticular aspect, to a protrusion of the supravescical fossa, which, not being defined as such, appears evidently misidentified as a subgroup of direct hernias. As an example, the above mistaken interpretation resembles the issue of multiple ipsilateral hernias, which are considered extremely rare but actually more common than imagined [8]. Nevertheless, once the main hernia has been identified during inguinal hernia repair, few surgeons routinely carry out a meticulous search for additional hernias protruding from the groin itself. Despite the fact that

surgeons almost unanimously confirm that no search for further hernias is routinely carried out, skepticism on this unexpected incidence is usually generalized. On the contrary, especially after the advent of laparoscopic surgery, renowned scientists have certified an incidence of multiple ipsilateral hernias ranging from ca. 10%–15% [22–26]. These numbers roughly correspond to those evidenced in our patient cohort concerning additional ipsilateral hernias. The three multiple ipsilateral hernias detected among patients of this investigation also show a separate protrusion of the supravescical fossa and must be associated to the category of multiple ipsilateral inguinal hernia. With regard to the true protrusions of the supravescical fossa, it is worth highlighting the anatomical aspect of this hernia type by means of the relevant image data collected. The pictures, in the case of true uncombined hernia of the supravescical fossa, constantly show a narrowing of the hernia opening that distally expands into a diverticulum-like sacculation. Probably, the stiffer medial umbilical fold at the level of the inguinal

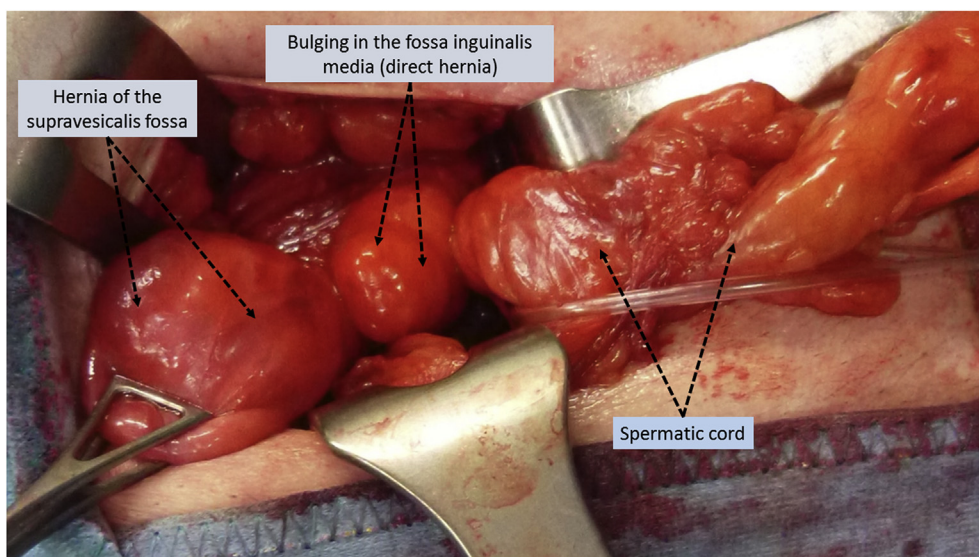


Fig. 9. Double ipsilateral hernia composed of two separated protrusions: a supravescical hernia close to a protrusion emerging through the medial inguinal fossa.

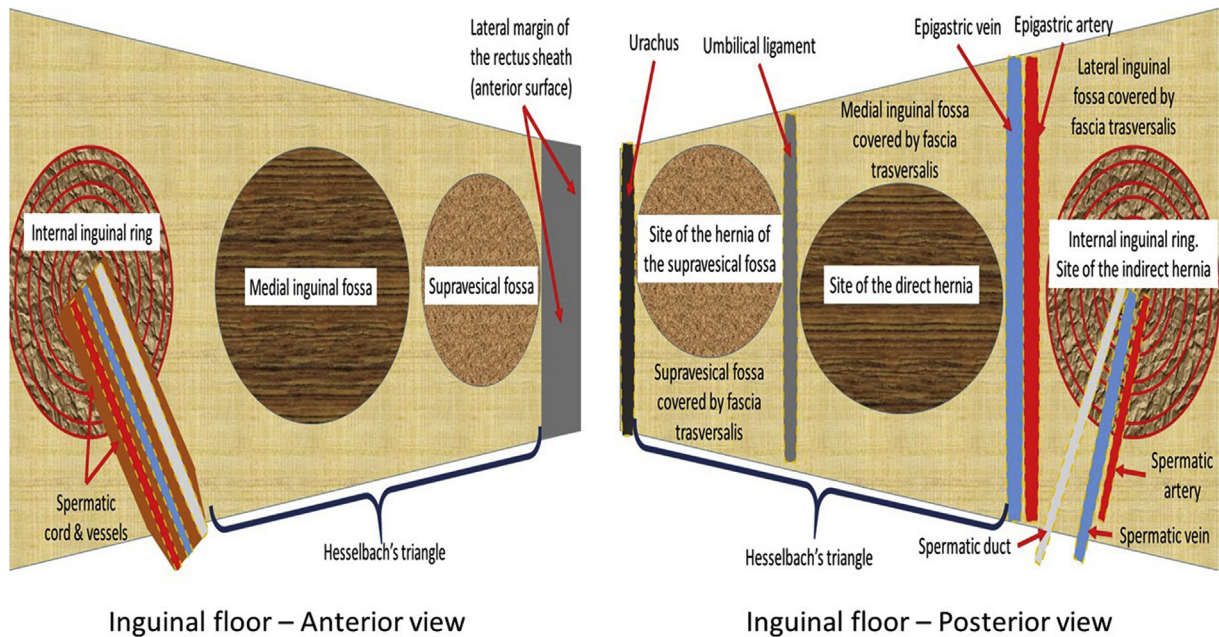


Fig. 10. Schematic representation of the inguinal backwall both, in the anterior as well as in the posterior aspect.

floor and the robust lateral margin of the rectus sheath impedes the enlargement of the hernia opening as it emerges from the abdominal wall, thus tightening the base of the protrusion. This anatomical aspect assumes great significance as it clarifies that this kind of protrusion can incarcerate more frequently than other types of hernia. In the bi-component combined hernia (direct + supravesical fossa), the medial umbilical fold seems to press on the transition zone between the two combined protrusions. In some cases, the stricture was moderate but in other patients the hernia opening looked openly constricted and the content, almost impaired within the sac, also showed signs of ischemic suffering. Such intraoperative evidence was always connected to preoperative reports of intermittent or steady inguinal pain, sometimes associated to painful reposition or irreducibility of the hernia content. We feel this is the distinctive trait of this neglected hernia type, which reveals a high tendency to incarceration, both in the uncombined and in the combined variant. In effect, of the 7 incarcerated hernias identified among the patient series, all involved hernias of the supravesical fossa, independently of the combined or uncombined variant. This may be a coincidence but it is undoubtedly worth noting that, having such a tightened base, this hernia type presents favorable conditions for incarceration of the visceral content.

5. Conclusions

Summarizing, the results of the investigation lead to the following considerations:

- External hernia of the supravesical fossa, both in the uncombined and in the combined version, seems to have an incidence of about 10%. Therefore, it should not be considered as rare as previously imagined.
- If a medium/small protrusion with inguinal pain and/or irreducibility of the sac is present, the existence of a hernia of the supravesical fossa should be considered.
- Due to the tendency to incarceration, if a hernia of the supravesical fossa is suspected, indication for surgical procedure in the short term appears mandatory.

In light of the described outcomes, a final concern regards the need to accordingly amend the current inguinal hernia classifications. Despite there being so many classifications, and the risk that another one might increase confusion, we nonetheless feel that a reflection on this issue is due.

Ethical approval

The investigation is a retrospective study and do not need approval by Ethics Committee. All procedures involving human participants were in accordance with the ethical standards of the institutional and/or national research committee and with the 1964 Helsinki declaration and its later amendments or comparable ethical standards.

Sources of funding

No grants or other kind of financial support has been received for realizing the article.

Author contribution

Giuseppe Amato: study design, data analysis.
 Giorgio Romano: data collection, language editing.
 Enrico Erdas: data collection.
 Fabio Medas: data collection.
 Luca Gordini: writing.
 Francesco Podda: data analysis.
 Piergiorgio Calò: data collection, data analysis.

Conflicts of interest

All authors have no conflict of interest.

Guarantor

Prof. Giuseppe Amato.

Acknowledgement

Sources of funding: this research did not receive any specific grant from funding agencies in the public, commercial, or not-for-profit sectors.

References

- [1] A.P. Cooper, *The anatomy and surgical treatment of inguinal and congenital hernia*, Longman & Co London, 1804, p. 51.
- [2] S. Balakrishnan, M.N.A. Paramu, R. Elanchezian, Supravesical hernia e A rare cause of intestinal obstruction, *Int. J. Surg.* 6 (2008) 471–472.
- [3] D.R. Barnes, B.J. Dreyer, Internal supravesical hernia: report of a case presenting with bladder symptoms, *Br. J. Surg.* 40 (163) (1953 Mar) 508–509.
- [4] L. Schwarz, D. Moszkowicz, F. Peschard, K. Keilani, F. Michot, M. Scotte, Internal supravesical hernia: an unusual cause of small bowel obstruction, *Clin. Anat.* 25 (2012) 663–667.
- [5] M. Bouassida, S. Sassi, H. Touinsi, H. Kallel, M.M. Mighri, F. Chebbi, M. Ben Ali, K. Bouzeidi, S. Sassi, Internal supravesical hernia - a rare cause of intestinal obstruction: report of two cases, *Pan Afr. Med. J.* 11 (2012) 17.
- [6] N. Can Öztürk, Z. Kurtoglu, Internal supravesical hernia accompanied with anomalous fold formations: a cadaveric case report, *Surg. Radiol. Anat.* 36 (2014) 1089–1092.
- [7] G. Amato, A. Agrusa, V. Rodolico, R. Puleio, G. Di Buono, S. Amodeo, E. Gulotta, G. Romano, Combined inguinal hernia in the elderly. Portraying the progression of hernia disease, *Int. J. Surg.* 33 (Suppl 1) (2016 Sep) S20–S29.
- [8] G. Amato, A. Agrusa, G. Romano, Multiple Ipsilateral Inguinal Hernias: more frequent than imagined, if undetected source of discomfort, pain, and re-interventions, *Surg. Technol. Int.* 25 (2014 Nov) 130–135.
- [9] I.J. Walker, Hernia into the prevesical space, *Ann. Surg.* 97 (5) (1933) 706–712.
- [10] W. Linhart, *Vorlesungen über Unterleibs-Hernien*, 1866. Würzburg.
- [11] E. Klebs, *Handbuch der pathologischen Anatomie*. Bd 1: 1–2. Berlin 1869-76.
- [12] R. U. Kronlein. Hernia inguino-properitonealis incarcerata. *Arch. f. klin. Chir.* XIX, pp. 408–420, 1875-1876.
- [13] M. Wilms. *Der Ileus*. Deutsche Chirurgie. Lieferung, 46 g., 1906.
- [14] G. Joessel, W. Waldeyer. *Handbuch der Topographisch-Chirurgischen Anatomie mit Einschluss der Operations-Übungen an der Leiche*. Nach dem Tode des Verfassers fortgesetzt von W. Waldeyer. 1884–1889.
- [15] I. Sozen, J. Nobel, Inguinal mass due to an external supravesical hernia and acute abdomen due to an internal supravesical hernia: a case report and review of the literature, *Hernia* 8 (2004) 389–392.
- [16] S.B. Chandler, Studies on the inguinal region; the anatomy of the inguinal canal, *Anat. Rec.* 94 (1946 Mar) 452.
- [17] D.F. Casten, Functional anatomy of the groin area as related to the classification and treatment of groin hernias, *Am. J. Surg.* 114 (1967) 894–899.
- [18] L.M. Nyhus, M.S. Klein, F.B. Rogers, Inguinal hernia, *Curr. Probl. Surg.* 28 (1991) 403–450.
- [19] V. Schumpelick, K.H. Treutner, G. Arlt, Classification of inguinal hernias, *Chirurg* 65 (1994) 877–879.
- [20] M. Miserez, J.H. Alexandre, G. Campanelli, F. Corcione, D. Cuccurullo, M.H. Pascual, A. Hoferlin, A.N. Kingsnorth, V. Mandala, J.P. Palot, V. Schumpelick, R.K. Simmermacher, R. Stoppa, J.B. Flament, The European Hernia Society groin hernia classification: simple and easy to remember, *Hernia* 11 (2) (2007) 113–116.
- [21] A.I. Gilbert, An anatomic and functional classification for the diagnosis and treatment of inguinal hernia, *Am. J. Surg.* 157 (1989) 331–333.
- [22] O. Ekberg, A. Lasso, P. Kesek, D. Van Westen, Ipsilateral multiple groin hernias, *Surgery* 115 (1994) 557–562.
- [23] A.M. Woodward, E.U. Choe, L.M. Flint, J.J. Ferrara, The incidence of secondary hernias diagnosed during laparoscopic total extraperitoneal inguinal herniorrhaphy, *J. Laparoendosc. Adv. Surg. Tech. A* 8 (1) (1998) 33–38.
- [24] H. Kehlet, M. Bay-Nielsen, Nationwide quality improvement of groin hernia repair from the Danish Hernia Database of 87,840 patients from 1998 to 2005, *Hernia* 12 (2008) 1–7.
- [25] J. Mayank, K. Shashi, S. Bimalendu, T. Om, Ipsilateral occult hernias during endoscopic groin hernia repair, *J. Minim. Access Surg.* 4 (2) (2008) 44–47.
- [26] G. Subhas, D. Bakston, A. Gupta, M.J. Jacobs, V.K. Mittal, S. Silapaswan, Internal ring occlusion and floor support: a novel technique for inguinal hernia mesh repair, *Am. Surg.* 76 (9) (2010 Sep) 933–937.