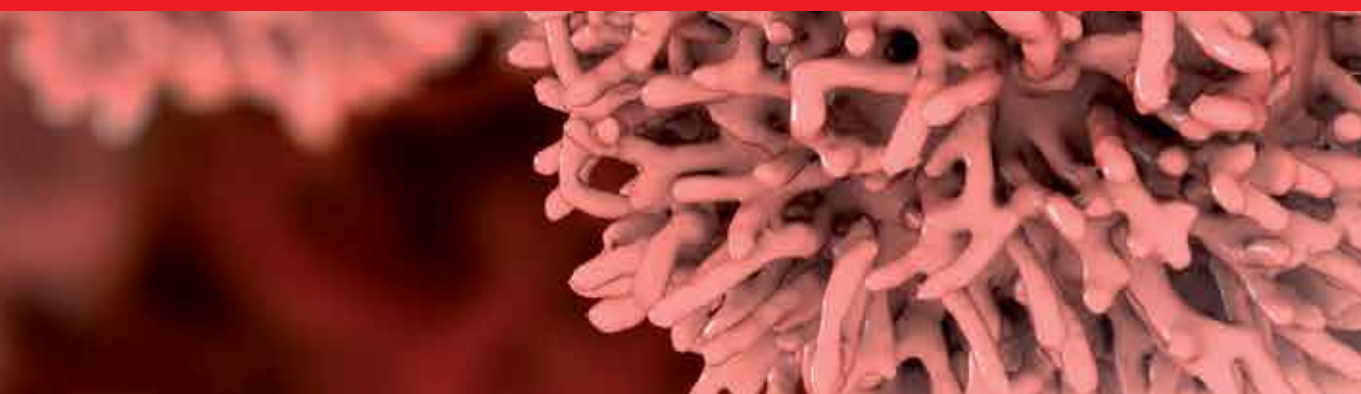




IntechOpen

Knowledges on Thyroid Cancer

Edited by Omer Engin



Knowledges on Thyroid Cancer

Edited by Omer Engin

Published in London, United Kingdom



IntechOpen





Supporting open minds since 2005



Knowledges on Thyroid Cancer
<http://dx.doi.org/10.5772/intechopen.77702>
Edited by Omer Engin

Contributors

Dana I Stoian, Andreea Borlea, Ioana Mozos, Laura Cotoi, Sinan Binboga, Eyup Gemici, Elif Binboga, Syed Mudassar, Mosin S Khan, Shariq R Masoodi, Khurshid I Andrabi, Manuel Faria, Carla Sobral, Marcelo Magalhaes, Pietro Giorgio Calò, Fabio Medas, Gian Luigi Canu, Enrico Erdas, Maria Deligiorgi, Dimitrios Trafalis, Omer Engin

© The Editor(s) and the Author(s) 2019

The rights of the editor(s) and the author(s) have been asserted in accordance with the Copyright, Designs and Patents Act 1988. All rights to the book as a whole are reserved by INTECHOPEN LIMITED. The book as a whole (compilation) cannot be reproduced, distributed or used for commercial or non-commercial purposes without INTECHOPEN LIMITED's written permission. Enquiries concerning the use of the book should be directed to INTECHOPEN LIMITED rights and permissions department (permissions@intechopen.com).

Violations are liable to prosecution under the governing Copyright Law.



Individual chapters of this publication are distributed under the terms of the Creative Commons Attribution 3.0 Unported License which permits commercial use, distribution and reproduction of the individual chapters, provided the original author(s) and source publication are appropriately acknowledged. If so indicated, certain images may not be included under the Creative Commons license. In such cases users will need to obtain permission from the license holder to reproduce the material. More details and guidelines concerning content reuse and adaptation can be found at <http://www.intechopen.com/copyright-policy.html>.

Notice

Statements and opinions expressed in the chapters are these of the individual contributors and not necessarily those of the editors or publisher. No responsibility is accepted for the accuracy of information contained in the published chapters. The publisher assumes no responsibility for any damage or injury to persons or property arising out of the use of any materials, instructions, methods or ideas contained in the book.

First published in London, United Kingdom, 2019 by IntechOpen
IntechOpen is the global imprint of INTECHOPEN LIMITED, registered in England and Wales, registration number: 11086078, The Shard, 25th floor, 32 London Bridge Street
London, SE19SG – United Kingdom
Printed in Croatia

British Library Cataloguing-in-Publication Data
A catalogue record for this book is available from the British Library

Additional hard and PDF copies can be obtained from orders@intechopen.com

Knowledges on Thyroid Cancer
Edited by Omer Engin
p. cm.
Print ISBN 978-1-78923-983-6
Online ISBN 978-1-78923-984-3
eBook (PDF) ISBN 978-1-83881-891-3

We are IntechOpen, the world's leading publisher of Open Access books Built by scientists, for scientists

4,200+

Open access books available

116,000+

International authors and editors

125M+

Downloads

151

Countries delivered to

Our authors are among the
Top 1%

most cited scientists

12.2%

Contributors from top 500 universities



WEB OF SCIENCE™

Selection of our books indexed in the Book Citation Index
in Web of Science™ Core Collection (BKCI)

Interested in publishing with us?
Contact book.department@intechopen.com

Numbers displayed above are based on latest data collected.
For more information visit www.intechopen.com



Meet the editor



Dr. Omer Engin is an associate professor of general surgery at Health Sciences University, Tepecik Training and Research Hospital, Surgery Department, Turkey. He has published a number of international articles, chapters, and congress papers, and has served as book editor for international published books and as an organizing committee member in a number of international conferences. He is an organization scientific committee member in the International Medical Society Scientific Committee and Athens Institute for Education and Research. He serves as an editorial board member and as a reviewer for many international medical and surgical scientific journals. His specializations are: endocrine surgery, hepatobiliary surgery, bariatric surgery, gastrointestinal surgery, and oncologic surgery.

Contents

Preface	XIII
Chapter 1 Introductory Chapter: Knowledges on Thyroid Cancer <i>by Omer Engin</i>	1
Chapter 2 Thyroid Anatomy <i>by Sinan Binboga, Eyup Gemici and Elif Binboga</i>	5
Chapter 3 Advanced Ultrasound Techniques in Preoperative Diagnostic of Thyroid Cancers <i>by Andreea Borlea, Laura Cotoi, Ioana Mozos and Dana Stoian</i>	17
Chapter 4 Papillary Thyroid Carcinoma Intertwined with Hashimoto's Thyroiditis: An Intriguing Correlation <i>by Maria V. Deligiorgi and Dimitrios T. Trafalis</i>	37
Chapter 5 Thyroid Cancer and Acromegaly <i>by Carla Souza Pereira Sobral, Marcelo Magalhães and Manuel dos Santos Faria</i>	59
Chapter 6 Intraoperative Neuromonitoring in Thyroid Surgery <i>by Fabio Medas, Gian Luigi Canu, Enrico Erdas and Pietro Giorgio</i>	69
Chapter 7 Genetic Alterations of RET: Possible Implications and Clinical Correlations in Thyroid Carcinogenesis <i>by Syed Mudassar, Mosin S. Khan, Shariq R. Masoodi, Mahboob Ul Hussain and Khurshid I. Andrabi</i>	83

Intraoperative Neuromonitoring in Thyroid Surgery

*Fabio Medas, Gian Luigi Canu, Enrico Erdas
and Pietro Giorgio*

Abstract

Recurrent laryngeal nerve (RLN) injury is the most feared complication in thyroid surgery, resulting in a worse patients' quality of life, and is the most common cause of medical claim. Visualization of RLN before proceeding with dissection of the gland is considered the gold standard. In the last decade, intraoperative neuromonitoring (IONM) of RLN has progressively gained acceptance; nowadays, this method is widely spread, being routinely used in large workflow centers. IONM is helpful in the identification of RLN and allows to assess nerve functionality during and at the end of surgical procedure. In this chapter, IONM features, its advantages and limits, and its usefulness will be discussed.

Keywords: thyroid surgery, thyroid carcinoma, intraoperative neuromonitoring, recurrent laryngeal nerve, nerve injury

1. Introduction

Postoperative recurrent laryngeal nerve (RLN) injury is one of the most feared complications during thyroid surgery. Even in experienced hands, transient RLN palsy occurs in 0.4–12% of cases [1–3], while permanent palsy is reported in up to 5–6% [2, 4]; its frequency is lower (0.2–0.8%) in hospitals with a large workflow [5]. RLN palsy can significantly deteriorate patients' quality of life, causing hoarseness of voice, dysphonia and dysphagia. Bilateral RLN palsy is an uncommon but life-threatening complication, even if transient, since it is associated to airway obstruction, which is potentially lethal for the patient. Intraoperative RLN injuries are due to transection and traction of the nerve, electrical and thermal injuries, suture entrapment and excessive skeletization. The risk of nerve palsy increases during surgery for thyroid cancer, especially in case of large or locally advanced tumors that can dislocate or infiltrate the nerve, during central compartment lymph node dissection (CLND) or in case of revision surgery. Over the years, surgical approach to RLN has consistently changed: the first approach, consisting in non-visualization and avoidance of the nerve, has been replaced with routine identification of RLN, which has been reported to be associated with a lower incidence of RLN palsy [6–10].

Intraoperative neuromonitoring (IONM) of RNL during thyroid surgery has widely spread during the last decade as an adjunct to the gold standard of direct visualization of the nerve; nowadays, it has become standard practice in thyroid surgery for many surgeons [11]. The most common method currently in use for

RLN monitoring is an endotracheal tube containing electrodes embedded on it, placed in close proximity to vocal cords, that register effects of stimulation of RLN. IONM is able to detect anatomic variations of the nerve and to clarify the mechanism and the site of the injury, and to predict vocal cord function after surgery. During surgical procedure, repeated tissue stimulation is helpful to correctly identify the nerve. Furthermore, IONM can detect non-function nerves that appear anatomically intact.

2. Intraoperative neuromonitoring in thyroid surgery

Intraoperative neuromonitoring has been introduced in thyroid surgery as an adjunct to standard visual identification of the recurrent laryngeal nerve (RLN) to prevent nerve lesion. The use of IONM, besides helping to identify the RLN, gives an objective evaluation of its function during the whole dissection [12–15]. IONM was introduced about 50 years ago, and various neuromonitoring methods (glottic pressure method, glottic monitoring method, insertion of needle electrodes in vocal cords endoscopically or through cricothyroid membrane, laryngeal palpation method, and monitoring via endotracheal tube with surface electrodes) have been utilized [16]. For several reasons, such as simplicity, non-invasiveness, and safety, IONM via endotracheal (ET) tube with surface electrodes has become the standard method [12]. It consists in an electromyography (EMG) that evaluates the vocal cord adductor function by using surface electrodes on the ET tube. NIM-Response 3.0 System (Medtronic Xomed, Jacksonville, Florida, USA) is the most widely used device for RLN monitoring (**Figure 1**). It transforms laryngeal muscle activity into audible and visual EMG signals whenever the RLN or vagus nerve is stimulated intraoperatively. This system basically consists of the combination of two electrical circuits: stimulation and recording sides. The stimulation side consists of a stimulator probe (nerve stimulator probe, continuous vagus nerve stimulator probe), which transmits electric current to the nerve, and a grounding electrode. The nerve stimulation probe can be monopolar or bipolar, while the continuous monitoring probes applied to the vagus nerve can be monopolar, bipolar, or tripolar. The

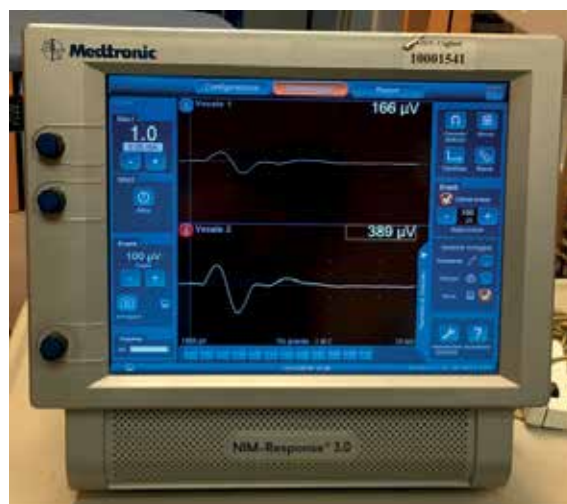


Figure 1. NIM-Response 3.0 System (Medtronic Xomed, Jacksonville, Florida, USA) (Italian configuration). In thyroid surgery, two channels for the right and left vocal cords are sufficient and 2 EMG screens appear on the monitor.



Figure 2.
ET tube with surface electrodes and grounding electrodes (white: stimulation side, green: recording side).



Figure 3.
Stimulation and recording sides are combined on the interconnect box, through which they connect to the monitor.

recording side, instead, consists of the ET tube with surface electrodes, which are placed at the level of the vocal cord, and their ground electrode (**Figure 2**). These two main systems combine on the interconnection box (**Figure 3**), through which

they connect to the monitor. The monitoring systems can be with 2, 4, 8, or 16 channels. The number of channels indicates the number of nerves that can be monitored. A separate EMG screen appears for each nerve on the monitor. In thyroid surgery, two channels for the right and left vocal cords are sufficient and two EMG screens appear on the monitor (**Figure 1**). In case of continuous vagus nerve stimulation, instead, two EMG screens for intermittent monitoring appear on the left side of the monitor, and another EMG screen for continuous vagus nerve stimulation appears on the right side.

3. Standardization of intraoperative neuromonitoring

Adequate knowledge of the neuromonitoring system and standardization of the procedure are required for proper use of IONM [12–17]. In this context, both surgeons and anaesthesiologists are involved. In order to reach an adequate experience, it has been stated that the learning curve is approximately of 50–100 cases [18–20].

The anesthetist plays a key role in IONM procedure, particularly with regard to the type of drugs used to induce anaesthesia and to the positioning of the ET tube. After these steps, anaesthesia can be obtained by inhaler or intravenous anaesthetics: these agents do not have significant effects on EMG signal, providing an adequate depth of anaesthesia. Differently, neuromuscular blocking agents (NMBAs) interfere with monitoring, reducing EMG amplitude and the optimal laryngeal response, thus making neuromonitoring less effective. For this reason, after induction, NMBA should be avoided for the rest of the operation. Small doses of a non-depolarizing muscle relaxant (usually rocuronium and atracurium) are used at intubation, as these agents allow the restoration of basic physiological functions, such as spontaneous respiration and normal muscle twitch activity, within a few minutes.

Endotracheal tubes are available in sizes 6.0, 6.5, 7.0, 7.5, and 8.0. The largest tube that can be passed between the patient's vocal cords has to be used. The ET tube is placed under direct laryngoscopy with the middle of the blue marked region (the exposed electrodes) in contact with the true vocal cords. The tube has to be placed in the right position to obtain adequate functioning of the system. Endotracheal tube positioning errors include not only depth errors but also rotational errors. The malposition of the ET can lead to misleading information and is a potential cause of loss of signal during surgery. After the tube is inserted, the patient is given the right operation position, with hyperextended neck, by applying a pillow under the shoulders. During positioning, the anesthetist must protect the ET tube to keep its position unchanged. If the tube is fixed to the rim of the patient's mouth before the patient is correctly positioned, the position of the tube in the airway can change. This can lead to a disruption of the relationship between the surface electrodes of the ET tube and the vocal cords. Thus, the tube has to be secured to the rim of the lip after the patient is correctly positioned.

Once the patient is positioned, the grounding electrode of the recording side and the grounding electrode of the stimulation side are subdermally applied to the presternal region or to the shoulder at the side of the monitor. The second one should be placed 1–2 cm below the first one.

After all connections are made, the correct positioning of the ET tube must be checked. This can be done from the monitor by verifying the impedance value of the electrodes (**Figure 4**). For each electrode, it has to be less than 5 k Ω . Moreover, the impedance difference between positive and negative electrodes of each channel should be less than 1 k Ω . Values above these thresholds indicate that the contact between the patient's vocal cords and the ET tube electrodes is not adequate. Other

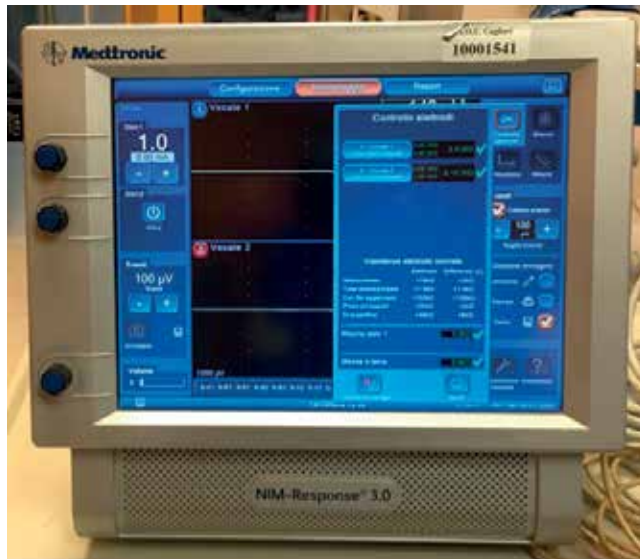

Figure 4.
Check of the impedance value of the electrodes from the monitor.

tests to verify the correct location of the ET tube include the evaluation of respiratory changes or a further laryngoscopy. About the first method, in the short-term window period between the loss of the effect of short-acting NMBA and the deepening of anesthesia following intubation, spontaneous respiratory movements should result in waveforms with an amplitude of 30–70 μV on the monitor. These respiratory changes should be detected for both vocal cords.

At this point, the monitor should be set as follows: a threshold value of 100 μV , an excitation electrode stimulation level of 0.5–2 mA (mean: 1 mA), a stimulation period of 100 μs , and a stimulation frequency of 4 stimuli per second.

At the beginning of the operation, the stimulator probe should be tested directly on the infrahyoid or sternocleidomastoid muscle to confirm the presence of an appropriate muscle twitching. This confirms that the nerve stimulation probe is working properly and the absence of ongoing paralytic agent. Moreover, to confirm the overall system function, before the identification of RLN, an EMG signal should initially be obtained from the vagus nerve. This step is crucial to assess that IONM system is functioning correctly and that the normal pathway of RLN signal is elicited. The vagus nerve can be directly stimulated after dissection of the carotid sheath, or its stimulation can be performed simply by increasing the stimulation level up to 2–3 mA with the probe on the carotid sheath without dissecting it. The RLN is situated at the tracheoesophageal groove in proximity to the inferior thyroid artery. It can be initially searched with a stimulation level of 2 mA and fully mapped out; then, it can be isolated and visually confirmed. Once the nerve is visualized, the stimulation level can be turned down to 1 mA. It is important to keep in mind that RLN extralaryngeal branching can be found in about 30–40% of patients, particularly at the level of Berry's ligament. Thus, it is necessary to dissect the RLN from the lower neck up to the nerve entrance into the larynx. In case of branched RLN, each branch should be stimulated separately by using a stimulation current of 0.4–0.5 mA. EMG signal of these individual branches should be assessed to allow a reliable evaluation of the distribution of the motor and sensory fibers. After removing the surgical specimen and ensuring a complete hemostasis, the final testing of RLN and vagus nerve is performed.

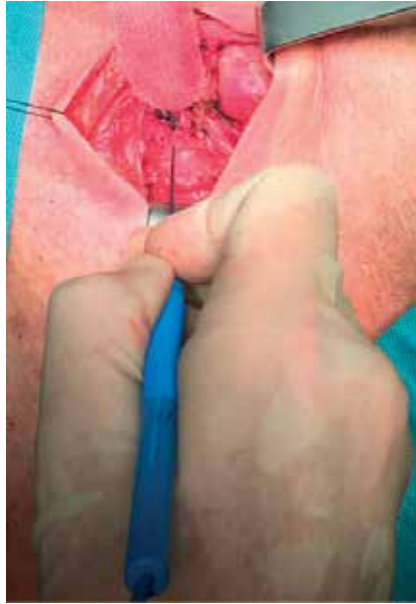

Figure 5.
RLN stimulation at the end of thyroid dissection and complete hemostasis (R2).

In 2011, the International Neural Monitoring Study Group (INMSG) defined the standard stages of intraoperative neuromonitoring in thyroid surgery by adding preoperative and postoperative vocal cord examinations to the four-step method previously proposed by Chiang et al. [12, 21]. The six stages can be summarized as follows:

- a. preoperative laryngoscopy (L1);
- b. vagus nerve stimulation before thyroidectomy (V1);
- c. RLN stimulation upon initial identification (R1);
- d. RLN stimulation at the end of thyroid dissection and complete hemostasis (R2) (**Figure 5**);
- e. vagus nerve stimulation after complete thyroidectomy and hemostasis (V2);
- f. postoperative laryngoscopy (L2).

As well as being useful during traditional open thyroidectomy, IONM can be very useful for RLN preservation also in case of endoscopic thyroid surgery [22, 23]. The fundamental steps of IONM during video-assisted thyroidectomy (VAT) are the same as those used during traditional thyroidectomy (L1, V1, R1, R2, V2, L2) [22]. IONM has proven to be very helpful also in the case of other endoscopic techniques, such as transaxillary or transoral thyroidectomy [23], even if a standardized technique is still lacking with these approaches.

4. Types of intraoperative neuromonitoring (I-IONM and C-IONM)

Currently, two types of IONM are available: the intermittent IONM (I-IONM) and the continuous IONM (C-IONM). With I-IONM, the functional integrity of the

RLN is limited to the site of direct nerve stimulation. For this reason, in proximal lesions of the RLN, distal stimulation near the larynx may produce a false negative IONM signal. Moreover, with this system, the RLN is at risk for damage during the time gap between two nerve stimulations. Ultimately, I-IONM allows the evaluation of the RLN only at the time of stimulation, and detects RLN lesion merely after it occurs [24].

To overcome these limits, a C-IONM technology has been introduced [25–28]. C-IONM consists in a probe that is applied directly to the vagus nerve, allowing the surgeon to constantly test the RLN function while dissecting the thyroid gland. However, the intermittent method is not a separate process from the continuous IONM technique. The intermittent IONM probe, in fact, is an integral and complementary part of the C-IONM [15]. The goal of continuous vagus nerve probing is to inform the surgeon immediately of any critical insult of the RLN, like traction, thus avoiding signal loss and vocal cord paralysis. A 50% decrease in amplitude and a 10% increase in latency time have been defined as critical changes [25, 28]. The device alarms when these thresholds are exceeded. According to recent observation, the most common cause of RLN lesion is tractional trauma [25–29]; C-IONM has proved to be useful in preventing traction injury by promptly detecting progressive decreases in EMG amplitude combined with progressive increases in latency. The surgeon can so avoid eventual RLN injury by changing his strategy. However, this system is not effective in case of acute injury of the nerve (section or thermal injury) [25–28].

5. Loss of signal

5.1 Definition of loss of signal

Loss of signal (LOS) occurs when the original EMG signal obtained from the vagus nerve and/or RLN nerve can no longer be elicited [12]. It is classified as true positive if vocal cord palsy is confirmed on postoperative laryngoscopy and false positive if no vocal cord palsy is present on postoperative laryngoscopy.

There are two types of LOS: the segmental type (Type 1) and the global type (Type 2).

Type 1 LOS consists in the loss of signal at a certain point in the nerve; signal is obtained distally to the point where the nerve is injured, but no signal is detected proximally to this site.

In case of Type 2 LOS, instead, no specific damage point is recognizable, and no signal is acquired stimulating the RLN all along its course or stimulating the vagus nerve.

About this argument, it is important to introduce another concept: the intra-operative signal recovery. Especially with the introduction of the C-IONM with continuous vagus nerve stimulation, it has been noted that, in some patients with signal loss, the signal can improve in the course of the operation.

5.2 Troubleshooting algorithm for loss of signal

When LOS occurs, a troubleshooting protocol should be followed to check the IONM system for technical problems [13, 30, 31].

In this case, the first procedure to be performed is to palpate the larynx with a finger behind the posterior plate of the cricoid to feel the posterior cricoarytenoid muscle contraction in response to RLN stimulation.

If digital detection of the laryngeal twitch is present in response to nerve stimulation, the stimulation side of the system is working properly, and a malfunction of the recording side should be considered. The most frequent causes of malfunction

of the recording side are ET tube malposition, displacement of grounding electrodes, or malfunction of the ET tube electrodes.

In addition to laryngeal palpation, contralateral vagal assessment also represents a useful option for troubleshooting. If contralateral vagus nerve stimulation does not elicit an adequate EMG signal, a malfunction of the recording side should be investigated as first option. Differently, if the contralateral vagus nerve is properly functioning, a possible nerve lesion must be considered.

If laryngeal twitch is absent when the nerve is stimulated, a malfunction of the stimulation side should be considered, thus the nerve stimulator probe and monitor have to be checked. Nerve stimulator probe function should be checked by applying its tip directly on a muscle to confirm a muscle twitching. Moreover, the whole system, with special attention focused on the monitor screen, must be fully reviewed. Again, with regard to stimulation side error, if C-IONM is used, LOS may be due to a dislocation of the vagal nerve electrode.

Finally, in case of LOS, it is of fundamental importance to rule any administration of NMBA during the operation.

6. Advantages and limits of IONM

6.1 Advantages of IONM

Visualization of RLNs is considered the gold standard in thyroid surgery to reduce the incidence of nerve palsy. Nevertheless, visualization of the nerve can only suggest an anatomic integrity, which does not ensure functionality. In fact, some studies have demonstrated that the most common mechanism of nerve injury is traction [29, 32], resulting in a palsy with complete anatomic integrity. Furthermore, direct visualization of the nerve can be difficult, especially in case of revision neck surgery, because of the scar tissue [1, 32–34], in case of anatomic variations of the nerve, during central compartment lymph node dissection, or in course of surgery for advanced thyroid cancer. For these reasons, in the last decades, the use of IONM has widely spread among endocrine surgeons, in order to facilitate identification and dissection of the nerve and to evaluate its functionality, predicting vocal cord function outcome.

However, to date, studies have failed to demonstrate a statistically significant reduction of incidence of nerve injury using IONM [2, 3]; this lack of data may be related to the very low rate of nerve palsy. It has been estimated that in prospective, randomized trials, the calculated sample size needed to demonstrate that incidence of palsy is lower with IONM use is about 9000 nerves at risk [1, 7]. Other authors have reported that at least 39,000 nerves at risk per arm should be necessary to achieve statistical power that could demonstrate a significant difference in RLN palsy rate [3]. To date, only one randomized controlled trial [35] has demonstrated a significant reduction of transient RLN palsy from 5 to 2.7% ($p = 0.007$).

Furthermore, it is important to underline that voice impairment isn't always due to RLN palsy; other causes can be vocal cord damage due to orotracheal intubation and damage of the strap muscles. In these cases, the good surgical practice and the integrity and functionality of the nerve are assessed by IONM, preserving from medical claim.

Advantages of IONM of RLNs in thyroid surgery are:

- Early identification of RLN and aid in dissection: Stimulation of paratracheal area allows to identify the course of the nerve before it is visualized; the identified area is then carefully dissected until the nerve is satisfactorily exposed.

Once the nerve is identified, stimulation of the adjacent structures can help to distinguish the nerve from other non-neural elements, like vessels. IONM is also helpful in identifying neural branches and to clarify nerve course in case of anatomic variants.

- **Intraoperative diagnosis of RLN injury and postoperative prognosis:** The most common causes of RLN injuries are transection of the nerve, suture entrapment, traction, compression, contusion, pressure, ischemia by excessive skeletization, thermal trauma caused by dissection or hemostatic instruments used too close to the nerve. In most of the cases of nerve injury, the nerve is anatomically intact, thus visualization only is not predictive of a vocal cord palsy; on the contrary, IONM allows to predict most of the nerve injuries, improving the accuracy of prognostic evaluation of nerve functionality. Once a loss of signal is detected, IONM allows to identify with high accuracy the site of the lesion by stimulating the nerve all long its course and the vagus nerve.
- **Reduction of bilateral RLN palsy:** Once RLN palsy has been diagnosed with IONM on the first side of resection, the surgeon can decide to modify the initially scheduled bilateral surgery and to perform a delayed completion thyroidectomy (two-staged thyroidectomy), in order to avoid a bilateral RLN palsy.
- **Difficult cases:** IONM has beneficial effects especially in difficult cases, like reoperative surgery, locally advanced thyroid cancer and cervico-mediastinal goiter, or in case of lymphadenectomy of central neck compartment, facilitating identification and dissection of the nerve.
- **Improvement of radicality in total thyroidectomy:** Most of RLN injuries are produced during dissection of thyroid tissue from Berry ligament, within the last 2 cm of the nerve. The two main reasons of lesion are a ramification of RLN, which occurs usually less than 5 mm of its entry in larynx, or an intracapsular course of RLN, which is reported in 15–38% of cases. Thus, in the absence of IONM, surgeons often tend to leave a small amount of thyroid tissue to avoid lesion of RLN in the last part of its course. On the contrary, IONM allows to completely resect the thyroid gland, reducing the risk of nerve palsy. Furthermore, hemostatic maneuvers can be safely conducted with IONM, ensuring that surgical sutures do not exert a traction on the nerve and that cauterization is far enough from the nerve.

6.2 Limits of IONM

The first evidence is that, despite IONM usage, RLN injury still remains one of the most common complications in thyroid surgery. Multiple studies have failed to demonstrate a reduction of incidence of RLN injury when IONM is used in thyroid surgery; as already discussed, this may be due to the very low incidence of RLN palsy. Surgeon should be conscious that IONM does not prevent at all RLN injury. In fact, stimulation of the nerve can assure integrity of the nerve only after dissection, while nerve palsy can be identified only after the injury has been produced. Thus, IONM should be considered an adjunct, but direct visualization of the nerve and careful dissection of the tissues are needed.

Although the specificity of IONM in detecting nerve injury is very high (94–99%), a small number of patients will have a vocal cord dysfunction despite

regular neuromonitoring signal (false-negative IONM). By the other side, a loss of signal (LOS) at the end of procedure is predictive of a postoperative vocal cord paralysis, but positive predictive value ranges widely from 33 to 90%.; this is probably related to the poor uniformity in application of IONM across different centers. It has been reported that preoperative and postoperative laryngoscopy is performed routinely only in 15% of centers who use IONM [36], and that vagal stimulation is not routinely performed in most of the centers [37]. Furthermore, usage of IONM needs a learning curve, a precise knowledge of the components and of the issues that may occur: insufficient experience in managing IONM may result in misleading information that can increase the risk of RLN injury.

The most frequent causes of false negative results are malposition of endotracheal tube, technical problems related to stimulation or registration devices, neuromuscular blocking due to anaesthetic drugs; another cause of false positive result is thought to be transient neuropraxia with rapid recovery before end of surgery.

Thus, low positive predictive value is the main limit of IONM. A low positive predictive value means that, in the worst-case scenario, two out of three patients with LOS will not suffer any alteration of vocal cord motility after surgery. In this regard, a standardization of IONM methods and reporting has been undertaken to provide uniformity and to minimize variations in application of IONM. As already discussed, standardization of IONM should include pre- and postoperative laryngoscopy, stimulation of vagus nerve before dissection and at the end of surgery, and stimulation of RLN when identified and at the end of lobectomy.

7. Two-staged thyroidectomy

Routine use of IONM in thyroid surgery has led to two-stage operations to prevent bilateral RLN palsy. This approach is defined as removal of the thyroid gland in two different procedures: in the first one, surgery is limited to the main lobe, while the remnant gland is excised in a second intervention. In fact, in case of LOS after excision of the first lobe, the surgeon can evaluate the opportunity to delay removal of the second lobe. Thus, a LOS during first lobectomy should induce to consider timing for contralateral lobectomy. This decision should take into account several elements, including especially thyroid pathology. Over the years, oncologic radicality in case of two-staged thyroidectomy has been a matter of debate; in this regard, we should consider that differentiated thyroid tumors have a good prognosis even in case of local or distant metastases, and that radioablative therapy with iodine-131 can be delayed safely. Thus two-staged thyroidectomy seems to be adequate also in case of thyroid carcinoma [38]; in this case, the endocrinologist can prescribe a TSH-suppressive therapy to reduce the risk of tumor progression of eventually unresected foci of tumor. Alternatively, a near-total lobectomy could be performed on the second side to preserve contralateral RLN. In this scenario, it is necessary to underline once again the importance of a correct standardization of IONM to reduce false positive results; that may lead to an unnecessary two-staged thyroidectomy. In case of thyroid cancer, thyroidectomy should always begin from tumoral side, or, in case of bilateral carcinoma, from the side where the nodule has more aggressive features. In case of two-staged thyroidectomy, contralateral lobectomy should be carefully planned after recovery of vocal cord motility, typically 6–8 weeks after surgery, or, in case of permanent palsy, after demonstration of enough respiratory space.

8. Conclusions

IONM is a valuable instrument in thyroid surgery. A correct standardization of the method is necessary to reduce the number of false positive results. In case of loss of signal, two-staged thyroidectomy can be safely performed even in case of malignancy.

Conflict of interest

The authors declare that there is no conflict of interest.

Author details

Fabio Medas*, Gian Luigi Canu, Enrico Erdas and Pietro Giorgio
Department of Surgical Sciences, University of Cagliari, Italy

*Address all correspondence to: fabiomedas@gmail.com

IntechOpen

© 2019 The Author(s). Licensee IntechOpen. This chapter is distributed under the terms of the Creative Commons Attribution License (<http://creativecommons.org/licenses/by/3.0>), which permits unrestricted use, distribution, and reproduction in any medium, provided the original work is properly cited. 

References

- [1] Deniwar A, Kandil E, Randolph G. Electrophysiological neural monitoring of the laryngeal nerves in thyroid surgery: Review of the current literature. *Gland Surgery*. 2015;**4**:368-375. DOI: 10.3978/j.issn.2227-684X.2015.04.04
- [2] Pisanu A, Porceddu G, Podda M, Cois A, Uccheddu A. Systematic review with metaanalysis of studies comparing intraoperative neuromonitoring of recurrent laryngeal nerves versus visualization alone during thyroidectomy. *The Journal of Surgical Research*. 2014;**188**:152-161. DOI: 10.1016/j.jss.2013.12.022
- [3] Deniwar A, Bhatia P, Kandil E. Electrophysiological neuromonitoring of the laryngeal nerves in thyroid and parathyroid surgery: A review. *World Journal of Experimental Medicine*. 2015;**5**:120-123. DOI: 10.5493/wjem.v5.i2.120
- [4] Gurrado A, Bellantone R, Cavallaro G, Citton M, Constantinides V, Conzo G, et al. Can total thyroidectomy be safely performed by residents?: A comparative retrospective multicenter study. *Medicine (Baltimore)*. 2016;**95**:e3241. DOI: 10.1097/MD.0000000000003241
- [5] Goretzki PE, Schwarz K, Brinkmann J, Wirowski D, Lammers BJ. The impact of intraoperative neuromonitoring (IONM) on surgical strategy in bilateral thyroid diseases: Is it worth the effort? *World Journal of Surgery*. 2010;**34**:1274-1284. DOI: 10.1007/s00268-009-0353-3
- [6] Jeannon JP, Orabi AA, Bruch GA, Abdalsalm HA, Simo R. Diagnosis of recurrent laryngeal nerve palsy after thyroidectomy: A systematic review. *International Journal of Clinical Practice*. 2009;**63**:624-629. DOI: 10.1111/j.1742-1241.2008.01875.x
- [7] Dralle H, Lorenz K, Machens A. Verdicts on malpractice claims after thyroid surgery: Emerging trends and future directions. *Head & Neck*. 2012;**34**:1591-1596. DOI: 10.1002/hed.21970
- [8] Rosato L, Avenia N, Bernante P, De Palma M, Gulino G, Nasi PG, et al. Complications of thyroid surgery: Analysis of a multicentric study on 14,934 patients operated on in Italy over 5 years. *World Journal of Surgery*. 2004;**28**:271-276. DOI: 10.1007/s00268-003-6903-1
- [9] Bergenfelz A, Jansson S, Kristoffersson A, Mårtensson H, Reihner E, Wallin G, et al. Complications to thyroid surgery: Results as reported in a database from a multicentre audit comprising 3660 patients. *Langenbeck's Archives of Surgery*. 2008;**393**:667-673. DOI: 10.1007/s00423-008-0366-7
- [10] Snyder SK, Lairmore TC, Hendricks JC, Roberts JW. Elucidating mechanisms of recurrent laryngeal nerve injury during thyroidectomy and parathyroidectomy. *Journal of the American College of Surgeons*. 2008;**206**:123130. DOI: 10.1016/j.jamcollsurg.2007.07.017
- [11] Melin M, Schwarz K, Pearson MD, Lammers BJ, Goretzki PE. Postoperative vocal cord dysfunction despite normal intraoperative neuromonitoring: An unexpected complication with the risk of bilateral palsy. *World Journal of Surgery*. 2014;**38**:2597-2602. DOI: 10.1007/s00268-014-2591-2
- [12] Randolph GW, Dralle H, International Intraoperative Monitoring Study Group, Abdullah H, Barczynski M, Bellantone R, et al. Electrophysiologic recurrent laryngeal nerve monitoring during thyroid and parathyroid surgery: International

standards guideline statement. *The Laryngoscope*. 2011;**121**(S1):Suppl 1-Suppl16. DOI: 10.1002/lary.21119

[13] Durán Poveda M, Dionigi G, Sitges-Serra A, Barczynski M, Angelos P, Dralle H, et al. Intraoperative monitoring of the recurrent laryngeal nerve during thyroidectomy: A standardized approach part 2. *World Journal of Endocrine Surgery*. 2012;**4**:33-40. DOI: 10.5005/jp-journals-10002-1091

[14] Uludag M, Aygun N, Kaya C, Tanal M, Oba S, Isgor A. Basic principles and standardization of intraoperative nerve monitoring in thyroid surgery. *The Medical Bulletin of Sisli Etfal Hospital*. 2017;**51**:13-25. DOI: 10.5350/SEMB.20170216084444

[15] Dionigi G, Wu CW, Lombardi D, Accorona R, Bozzola A, Kim HY, et al. The current state of recurrent laryngeal nerve monitoring for thyroid surgery. *Current Otorhinolaryngology Reports*. 2014;**2**:44-54. DOI: 10.1007/s40136-013-0033-6

[16] Shedd DP, Durham C. Electrical identification of the recurrent laryngeal nerve. I. Response of the canine larynx to electrical stimulation of the recurrent laryngeal nerve. *Annals of Surgery*. 1966;**163**:47-50

[17] Calò PG, Medas F, Gordini L, Podda F, Erdas E, Pisano G, et al. Interpretation of intraoperative recurrent laryngeal nerve monitoring signals: The importance of a correct standardization. *International Journal of Surgery*. 2016;**28**(Suppl 1):S54-S58. DOI:10.1016/j.ijisu.2015.12.039

[18] Dionigi G, Bacuzzi A, Boni L, Rovera F, Dionigi R. What is the learning curve for intraoperative neuromonitoring in thyroid surgery? *International Journal of Surgery*. 2008;**6**(Suppl 1):S7-S12. DOI: 10.1016/j.ijisu.2008.12.023

[19] Jonas J, Bähr R. Intraoperative neuromonitoring of the recurrent laryngeal nerve—Results and learning curve. *Zentralblatt für Chirurgie*. 2006;**131**:443-448. DOI: 10.1055/s-2006-955453

[20] Pragacz K, Barczyński M. Evaluation of the learning curve for intraoperative neural monitoring of the recurrent laryngeal nerves in thyroid surgery. *Polski Przegląd Chirurgiczny*. 2015;**86**:584-593. DOI: 10.1515/pjs-2015-0005

[21] Chiang FY, Lee KW, Chen HC, Chen HY, Lu IC, Kuo WR, et al. Standardization of intraoperative neuromonitoring of recurrent laryngeal nerve in thyroid operation. *World Journal of Surgery*. 2010;**34**:223-229. DOI: 10.1007/s00268-009-0316-8

[22] Dionigi G, Boni L, Rovera F, Bacuzzi A, Dionigi R. Neuromonitoring and video-assisted thyroidectomy: A prospective, randomized case-control evaluation. *Surgical Endoscopy*. 2009;**23**:996-1003. DOI: 10.1007/s00464-008-0098-3

[23] Lang BH, Wong KP. Feasibility on the use of intraoperative vagal nerve stimulation in gasless, transaxillary endoscopic, and robotic-assisted thyroidectomy. *Journal of Laparoendoscopic & Advanced Surgical Techniques. Part A*. 2011;**21**:911-917. DOI: 10.1089/lap.2011.0204

[24] Dionigi G, Van Slycke S, Boni L, Rauseri S, Mangano A. Limits of neuromonitoring in thyroid surgery. *Annals of Surgery*. 2013;**258**:e1-e2. DOI: 10.1097/SLA.0b013e318294559d

[25] Schneider R, Przybyl J, Pliquett U, Hermann M, Wehner M, Pietsch UC, et al. A new vagal anchor electrode for real-time monitoring of the recurrent laryngeal nerve. *American Journal of Surgery*. 2010;**199**:507514. DOI: 10.1016/j.amjsurg.2009.04.036

- [26] Schneider R, Bures C, Lorenz K, Dralle H, Freissmuth M, Hermann M. Evolution of nerve injury with unexpected EMG signal recovery in thyroid surgery using continuous intraoperative neuromonitoring. *World Journal of Surgery*. 2013;**37**:364-368. DOI: 10.1007/s00268-012-1853-0
- [27] Lamadé W, Ulmer C, Friedrich C, Rieber F, Schymik K, Gemkow HM, et al. Signal stability as key requirement for continuous intraoperative neuromonitoring. *Der Chirurg*. 2011;**82**:913-920. DOI: 10.1007/s00104-011-2080-1
- [28] Schneider R, Randolph GW, Sekulla C, Phelan E, Thanh PN, Bucher M, et al. Continuous intraoperative vagus nerve stimulation for identification of imminent recurrent laryngeal nerve injury. *Head & Neck*. 2013;**35**:1591-1598. DOI: 10.1002/hed.23187
- [29] Dionigi G, Wu CW, Kim HY, Rausei S, Boni L, Chiang FY. Severity of recurrent laryngeal nerve injuries in thyroid surgery. *World Journal of Surgery*. 2016;**40**:1373-1381. DOI: 10.1007/s00268-016-3415-3
- [30] Randolph GW, Kobler JB, Wilkins J. Recurrent laryngeal nerve identification and assessment during thyroid surgery: Laryngeal palpation. *World Journal of Surgery*. 2004;**28**:755-760. DOI: 10.1007/s00268-004-7348-x
- [31] Tomoda C, Hirokawa Y, Uruno T, Takamura Y, Ito Y, Miya A, et al. Sensitivity and specificity of intraoperative recurrent laryngeal nerve stimulation test for predicting vocal cord palsy after thyroid surgery. *World Journal of Surgery*. 2006;**30**:1230-1233. DOI: 10.1007/s00268-005-0351-z
- [32] Calò PG, Pisano G, Medas F, Marcialis J, Gordini L, Erdas E, et al. Total thyroidectomy without prophylactic central neck dissection in clinically node-negative papillary thyroid cancer: Is it an adequate treatment? *World Journal of Surgical Oncology*. 2014;**12**:152. DOI: 10.1186/1477-7819-12-152
- [33] Calò PG, Pisano G, Medas F, Tatti A, Tuveri M, Nicolosi A. Risk factors in reoperative thyroid surgery for recurrent goiter: Our experience. *Il Giornale di Chirurgia*. 2012;**33**:335-338
- [34] Pironi D, Pontone S, Vendettuoli M, Podzemny V, Mascagni D, Arcieri S, et al. Prevention of complications during reoperative thyroid surgery. *La Clinica Terapeutica*. 2014;**165**:e285-e290. DOI: 10.7417/CT.2014.1744
- [35] Barczynski M, Konturek A, Cichon S. Randomized clinical trial of visualization versus neuromonitoring of recurrent laryngeal nerves during thyroidectomy. *The British Journal of Surgery*. 2009;**96**:240-246. DOI: 10.1002/bjs.6417
- [36] Dionigi G, Tanda ML, Piantanida E, Boni L, Rovera F, Dionigi R, et al. Time interval in diagnosis and treatment of papillary thyroid cancer: A descriptive, retrospective study. *American Journal of Surgery*. 2009;**197**:434-438. DOI: 10.1016/j.amjsurg.2008.01.031
- [37] Dionigi G, Bacuzzi A, Barczynski M, Biondi A, Boni L, Chiang FY, et al. Implementation of systematic neuromonitoring training for thyroid surgery. *Updates in Surgery*. 2011;**63**:201-207. DOI: 10.1007/s13304-011-0098-z
- [38] Calò PG, Medas F, Conzo G, Podda F, Canu GL, Gambardella C, et al. Intraoperative neuromonitoring in thyroid surgery: Is the two-staged thyroidectomy justified? *International Journal of Surgery*. 2017;**41**(Suppl 1):S13-S20. DOI: 10.1016/j.ijsu.2017.02.001