

Laser Microsurgery Versus Radiotherapy Versus Open Partial Laryngectomy for T2 Laryngeal Carcinoma: A Systematic Review of Oncological Outcomes

Flaminia Campo, MD¹, Jacopo Zocchi, MD², Massimo Ralli, MD, PhD¹ ,
Daniele De Seta, MD, PhD³, Francesca Yoshie Russo, MD, PhD¹ ,
Diletta Angeletti, MD¹, Antonio Minni, MD¹, Antonio Greco, MD¹,
Raul Pellini, MD², and Marco de Vincentiis, MD⁴

Abstract

Introduction: The aim of the current systematic review is to update the pooled survival outcome of patients with T2 glottic carcinoma treated with either laser surgery (CO₂ transoral laser microsurgery [CO₂ TOLMS]), radiotherapy (RT), or open partial laryngectomy (OPL). **Methods:** A systematic search was performed using the MEDLINE database, Scopus, and Google scholar. The inclusion criteria were studies of patients with T2N0 glottic tumor, treated with either primary CO₂ TOLMS, definitive curative RT, or primary OPL, and with reported oncological outcome at 5 years calculated with a Kaplan-Meier or Cox regression method. **Results:** The results of the current review show that local control (LC) is higher with OPL 94.4%, while there are no differences in LC at 5-year posttreatment for patients treated with RT, compared to those treated with CO₂ TOLMS (respectively, 75.6% and 75.4%). Primary treatment with OPL and CO₂ TOLMS results in higher laryngeal preservation than primary treatment with RT (respectively 95.8%, 86.9%, and 82.4%). **Conclusion:** First-line treatment with OPL and CO₂ TOLMS should be encouraged in selected T2 patients, because it results in higher laryngeal preservation and similar LC compared to primary treatment with RT. The involvement of the anterior commissure in the craniocaudal plane and T2b impaired vocal cord mobility have a poorer prognosis and LC compared to patients with T2a tumors for both CO₂ TOLMS and RT.

Keywords

laser, radiotherapy, open partial laryngectomy, T2 glottic cancer, anterior commissure, oncological outcomes

Introduction

Early glottic cancer (Tis-T2) is a highly treatable disease with excellent survival rates. Many studies examined treatment outcomes for “early stage” laryngeal cancer, grouping those treated for carcinoma in situ (Tis), T1a, T1b, and T2 tumors, but most of the data for early laryngeal cancer are dominated by T1 and Tis cases.^{1,2} However, T1 and T2 glottic cancer are heterogeneous with different growth rates and tendency to infiltrate, and the therapy achieves different results in terms of both oncological and functional outcomes.

Available treatment options include CO₂ transoral laser microsurgery (CO₂ TOLMS), open partial laryngectomy (OPL), or radiotherapy (RT). To date, there is no clear evidence regarding the effectiveness of surgical treatment (CO₂ TOLMS and OPL) over RT, including a recent Cochrane analysis.¹⁻⁶

The aim of the current systematic review is to compare single-modality treatments for patients with T2 glottic

¹ Department of Sense Organs, Sapienza University of Rome, Rome, Italy

² Department of Otolaryngology and Head & Neck Surgery, IRCCS “Regina Elena” National Cancer Institute, Rome, Italy

³ Unit of Otorhinolaryngology, Department of Surgery, Azienda Ospedaliero-Universitaria Di Cagliari, University of Cagliari, Cagliari, Italy

⁴ Department of Oral and Maxillofacial Sciences, Sapienza University of Rome, Rome, Italy

Received: April 23, 2020; accepted: April 26, 2020

Corresponding Author:

Massimo Ralli, Department of Sense Organs, Sapienza University of Rome, Viale del Policlinico 155, Rome 00186, Italy.

Email: massimo.ralli@uniroma1.it



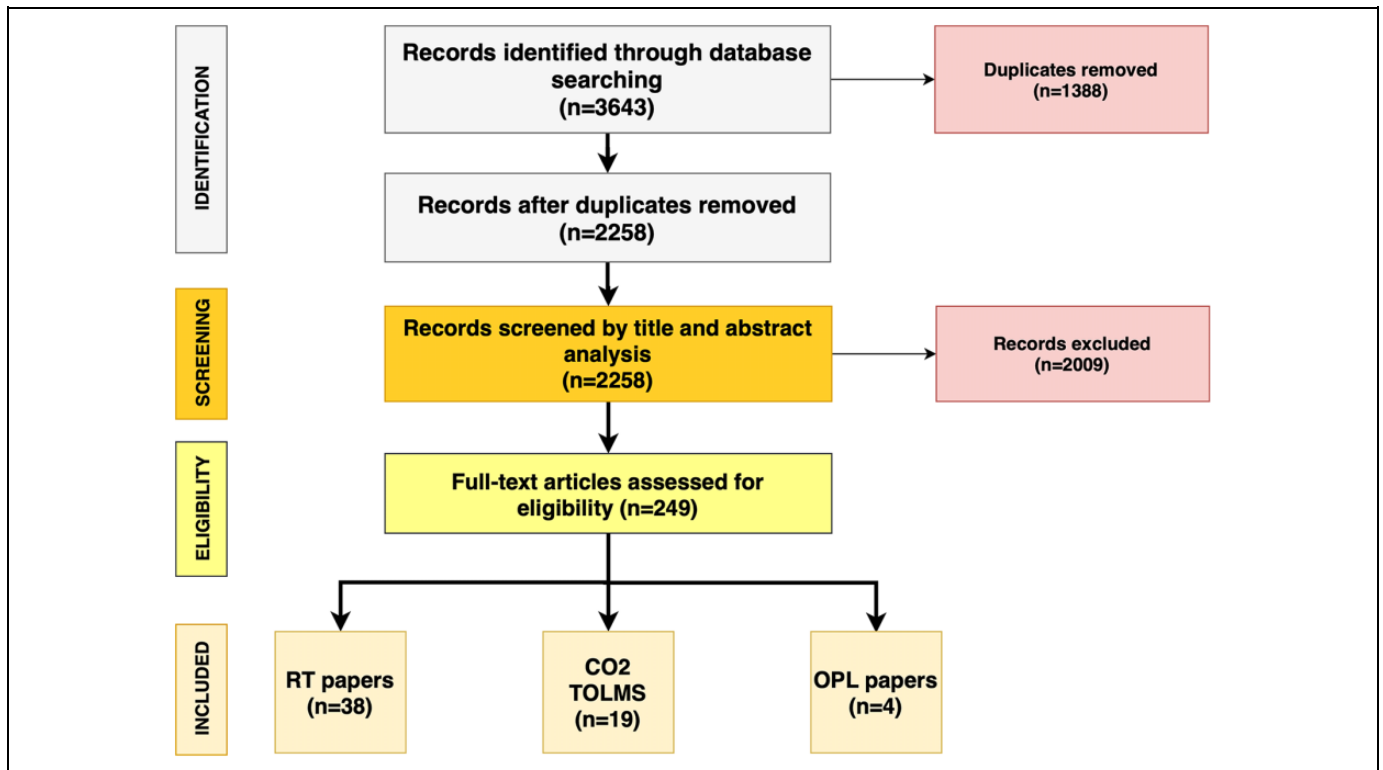


Figure 1. Preferred Reporting Items for Systematic Reviews and Meta-Analyses (PRISMA) diagram followed in this review. The diagram shows the information flow through the different phases of the review and illustrates the number of records that were identified and included.

carcinoma through the analysis of survival outcomes, local control (LC), and laryngeal preservation (LP) in patients treated with either CO₂ TOLMS, RT, or OPL.

Materials and Methods

Search Strategy

Following the Preferred Reporting Items for Systematic Reviews and Meta-Analyses (PRISMA) guidelines, 2 independent researchers conducted a literature search on articles published as of August 2019 using 3 different databases (PubMed, Scopus, and Google Scholar) with combinations of the following terms: laryngeal cancer, early glottic carcinoma/tumor, laryngeal squamous cell carcinoma, CO₂ TOLMS, RT, and OPL on articles published between January 1990 and August 2019.

Eligibility and Inclusion Criteria

The inclusion criteria were clinical studies in patients with glottic squamous cell carcinoma staged as a T2N0 according to the Union for International Cancer Control's (UICC) TNM Classification of Malignant Tumours—8th edition⁷ treated with either primary CO₂ TOLMS, curative RT, or primary OPL, and with reported oncological outcomes at 5 years calculated with a Kaplan-Meier or Cox regression method. Exclusion criteria were articles not written in English, studies with less than 10 patients, with concurrent chemoradiotherapy, those

describing surgery combined with adjuvant therapy, and those describing surgery or RT as salvage therapy.

Data Extraction

Title and abstract of selected papers were carefully read according to the inclusion and exclusion criteria, and duplicates were removed. The full text of the included studies was reviewed with extraction of following data: (1) patient number, (2) average follow-up time (months), (3) treatment, and (4) 5-year oncological outcome in terms of LC and LP.

Study Quality

The levels of evidence of the included articles were scored according to the standards by Wasserman et al⁸ as follows: level I: randomized controlled trials, level II: prospective study with internal control group, level III: retrospective study with internal control group, level IV: case series without an internal control group, and level V: consensus or expert opinion without critical appraisal.

Results

Search Results

The results of the search are summarized in Figure 1. The initial search identified 3464 studies on MEDLINE database, Scopus, and Google scholar. Articles published after the 1990s were selected and imported into a reference management

Table 1. Oncological Outcomes of Patient Treated With Radiotherapy.

Author (year)	Treatment period	Patients	Gray	Follow-up (months)	LC (%) 5 years	LP 5 years
Turesson (1991) ⁹	1963-1983	132	46-83	Minimum 48	68.9	
Fein (1993) ¹⁰	1977-1989	115	63-76	Minimum 24	84	84.3%
Stevens (1994) ¹¹	1979-1989	31	62	Median 49	70	
Klinterberg (1996) ¹²	1969-1991	94	60-72		73	
Burke (1997) ¹³	1983-1993	27	50-74	Median 63	70.6	
Le (1997) ¹⁴	1956-1995	83	52-76	Median 116	70	
Franchin (1998) ¹⁵	1985-1996	46	63-68	Median 72	70	
Sakata (2000) ¹⁶	1984-1996	50	64 vs 55-58 (CFX vs AF)	Median 69	70.8	
Smee (2000) ¹⁷	1967-1994	116	50-70	Mean 146	72	
Haugen (2002) ¹⁸	1990-1998	45	61-65	Mean 40	88	
Garden (2003) ¹⁹	1970-1998	230	70	Median 82	72	
Stoekli (2003) ²⁰	2008-2012	30	68-70.2	Mean 70	67	77
Chen (2003) ²¹	1983-2001	46	63-73	Minimum 12	60	63
Zouhair (2004) ²²	1983-2000	36	60-74	Median 85	77	
Frata (2005) ²³	1970-1999	256	61-65	Mean 90	73	
Murakami (2005) ²⁴	1989-1998	27	64-70	Mean 75	61	92
Short (2006) ²⁵	1986-1998	43	60-66 vs 55 (CFX vs HFX)	Median 59	80.5	
Tateya (2006) ²⁶	1987-1998	48	60-72 (CFX vs HFX)	Mean 80		95.2
Dagan (2007) ²⁷	1983-2002	80	63-77	Median 115	82	82
Chera (2010) ²⁸	1964-2006	260	74	Median 144	76.5	
Jones (2010) ²⁹	1987-2006	41	74	Median 70	97.6	
Smee (2010) ¹⁷	1967-2006	142	50-70	Median 91	71.8	
Khan (2012) ³⁰	1986-2006	54	44-69	Mean 67	75.9	
Tong (2012) ³¹	1983-2005	262	57-70	Median 126	79	
Al-Mamgani (2013) ³²	1985-2011	331	66-70	Median 90	78	
Douglas (2013) ³³	1999-2003	128	50-55	Median 71	82	
Karasawa (2013) ³⁴	2002-2010	24	63	Median 47	67.3	
Hoebbers (2013) ³⁵	2000-2011	120	60	Median 38	78	
Higashino (2014) ³⁶	2004-2011	20	70	Mean 60	80	
Moon (2014) ³⁷	2002-2010	16	70 vs 68 (CFX vs HFX)	Median 67	56.3-77.8	
Rutowski (2014) ³⁸	2002-2009	115	45-70 IMRT	Minimum 36	72	
Motegi (2015) ³⁹	1999-2007	44	65 (AF)	Minimum 24	77	95
Ermis (2015) ⁴⁰	2004-2013	64	55 (HFX)	Median 72	80.9	
Lim (2015) ⁴¹	1981-2010	67	67	Median 85	72	
Harada (2015) ⁴²	1991-2010	35	74.4	Median 61	86	97
Portenza (2015) ⁴³	2000-2010	16	66	Median 75	84	
Zumsteg (2015) ⁴⁴	1981-2011	70	60 (CFX vs IMRT)	Median 59	75.8	
Sert (2019) ⁴⁵	2005-2015	21	65.25 Gy in 29 fractions	Median 64	56	

Abbreviations: AF, accelerated fractionation; CFX, conventional fractionation; DSS, disease-specific survival; Gy, gray; HFX, hypofractionation; IMRT, Intensity-modulated radiation therapy; LC, local control; LP, larynx preservation; OS, overall survival.

software (Endnote, Clarivate Analytics). After the removal of duplicates, 2258 publications were identified. Papers were screened in title and abstract, and 249 manuscripts were reviewed in full text. Sixty-one studies met the inclusion criteria; of these, 38 RT papers, 19 CO₂ TOLMS studies, and 4 OPL article provided 5-year oncological outcome data for 1452 patients treated with CO₂ TOLMS, 3365 patients treated with RT, and 366 patients treated with OPL.

Study Characteristics

All 61 included studies were published in peer-reviewed journals and were case series without an internal control group, a level IV evidence. No randomized controlled trials studies were identified.

Oncological Outcomes

Tables 1, 2, 3, and 4 show the oncological results of patients treated with either CO₂ TOLMS, RT, or OPL in the studies included in this systematic review. The results of the analysis show that weighted averages of LC was higher with OPL (94.4%), while there were no differences in LC at 5 years for patients treated with RT, compared to those treated with CO₂ TOLMS (respectively, 75.6% and 75.4%). Primary treatment with OPL and CO₂ TOLMS resulted in higher LP in the long term compared to primary treatment with RT (respectively, 95.8%, 86.9%, and 82.4%).

Discussion

The main treatment modalities for early glottic carcinomas include CO₂ TOLMS, RT, and OPL; however, there is no clear

Table 2. Oncological Outcomes of Patient Treated With CO₂ Transoral Laser Microsurgery.

Author (year)	Treatment period	Patients	Follow-up (months)	LC 5 Years (%)	LP 5 years (%)
Eckel (2000) ⁴⁶	1987-1996	93	Mean 55	82	93.1
Peretti (2000) ⁴⁷	1987-1994	23	Mean 76	91	
Motta (2005) ⁴⁸	1991-1998	236	Mean 60	66	82.5
Peretti (2005) ⁴⁹	1998-2001	55	Mean 58	77	84.8
Rodel (2009) ⁵⁰	1986-2004	102	Median 65	76	
Mantsopoulos (2010) ⁵¹	1977-2004	143	Mean 139	89.4	
Peretti (2010) ⁵²	1988-2005	109	Mean 84	85.6	95.1
Blanch (2011) ⁵³	1998-2008	81	Mean 45.4	40.7	73.2
Lucioni (2011) ⁵⁴	2000-2007	14	Mean 47.9	78.6	100
Canis (2013) ⁵⁵	1979-2006	269	Mean 96	75.8	88.3
Fang (2013) ⁵⁶	2004-2011	30	Median 33	83.3	
Lee (2013) ⁵⁷	1997-2011	11	Mean 70	81.8	90
Peretti (2013) ⁵⁸	2005-2010	59	Minimum 18		84
Hoffman (2015) ⁵⁹	2001-2013	19	Mean 44	63.6	90.9
Ansarin (2017) ⁶⁰	1999-2013	90	Median 72		91.1
Day (2017) ⁶¹	1995-2011	17	Median 44.6	86	88
Chang (2017) ⁶²	2003-2009	20	Medium 35	84	
Carta (2018) ⁶³	1993-2005, 2010-2016	41	Median 52	79.5	88
Pedregal-Mallo (2018) ⁶⁴	1998-2013	40	Minimum 24	70	

Abbreviations: CO₂ TOLMS, transoral CO₂ laser microsurgery; LC, local control; LP, larynx preservation.

Table 3. Oncological Outcomes of Patient Treated With OPL.

Author (year)	Treatment period	Patients	Follow-up (months)	LC 5 years (%)	LP 5 years
Succo (2016) ⁶⁵	1995-2011	207	63	97.5%	98%
Giovanni (2001) ⁶⁶	1982-1997	65		92%	92%
Camprette (1998) ⁶⁷	1984-1993	23	Minimum 15	83%	
Spector (1999) ⁶⁸	1971-1989	71	Minimum 60s	93%	93%

Abbreviations: LC, local control; LP, laryngeal preservation; OPL, open partial laryngectomy.

Table 4. Weighted Averages of the Oncological Outcomes for CO₂ TOLMS, RT, or OPL.

Treatment	Patients	LC 5 years (%)	Patients	LP 5 years (%)
CO ₂ TOLMS	1362	75.4	1094	87
RT	3365	75.63	346	82.4
OPL	366	94.40	343	95.8

Abbreviations: CO₂ TOLMS, transoral CO₂ laser microsurgery; LC, local control; LP, larynx preservation; OPL, open partial laryngectomy; RT, radiotherapy.

evidence regarding the effectiveness of one treatment over the other.¹⁻⁴ The results of the current review show that weighted averages for LC and LP is higher with OPL (94.4% and 95.8%) compared to CO₂ TOLMS (75.4% and 87%) and RT (75.6% and 82.4).

Our systematic review shows that the number of patients treated with OPL was lower than that of patients treated with CO₂ TOLMS and RT; this suggests that the role of open surgery for management of laryngeal cancer has gradually decreased during the past 20 years probably because of the worse functional outcomes as voice quality and swallowing results. The development of CO₂ TOLMS and improvements

in delivery of RT have replaced the previously standard techniques of OPL for early cancer. In the recent years, CO₂ TOLMS has received a great consensus, as the use of CO₂ TOLMS as a primary treatment is more cost-effective than OPL or RT,⁶⁹⁻⁷¹ and it is usually performed as a day case procedure. Moreover, a number of optical and molecular examining technologies have been developed over the last few years to improve tumor detection and tumor margin identification. One of the most implemented techniques in clinical practice is narrow-band imaging (NBI); a significant reduction of positive superficial margins was found in patients treated with intraoperative use of NBI (52%) compared to patients treated without intraoperative NBI (28.6%; $P < .05$).⁷²

Laryngeal Preservation

The CO₂ transoral laser microsurgery resulted in higher LP compared to RT; this can be explained by the preservation of physiological cartilage barriers. Furthermore, laser surgery can be repeated or followed by other treatment protocols (eg, RT or OPL) in patients with recurrent disease. Contrarily, both RT and OPL in primary glottic carcinoma may lead to treatment limitations in case of recurrence, making organ preservation

more unlikely. In addition, patients undergoing salvage surgery post-RT have a greater number of complications than patients post-CO₂ TOLMS. Overall complication rate in salvage surgery post-RT ranges from 5% to 78% with the most common complication being pharyngocutaneous fistula formation occurring in as many as 73% of cases in the salvage setting.^{73,74}

Local Control

Evidence confirms that patients with T2b and vocal cord mobility have a poorer prognosis and LC compared to patients with T2a tumors for both CO₂ TOLMS^{3,55} and RT^{9,10,13,27,28,30,75,76} while data on OPL are not enough to evaluate the oncological outcomes in these patients. In a recent case series, Succo et al⁶⁵ affirmed that OPL is safer in case of T2b compared to CO₂ TOLMS; however, it led to more dysfunctional sequelae. The authors concluded that OPL should be performed in selected patients affected by glottic cT2 with impaired mobility of vocal cords and suspected extension to the paraglottic space (PGS). Rucci et al⁷⁷ observed that the dorsal compartment of the glottic site is in close proximity to the paraglottic space. The internal cricoarytenoid ligaments oppose for a short length of time to the penetration of early glottic cancer into the paraglottic space toward the cricoarytenoid joints. Lesions invading the paraglottic space should be correctly classified as T3 during the preoperative evaluation with a transnasal flexible videofiberscope and magnetic resonance imaging.⁷⁸ Poorer prognosis seems to be associated mainly with tumor infiltration of the posterior paraglottic space resulting in fixation of the arytenoid joint and not with impaired mobility from vocal fold muscle infiltration or pure tumor bulk.⁶

Involvement of the Anterior Commissure

The treatment of the T2 glottic cancer with involvement of anterior commissure (AC) is also controversial. Laccourreye et al⁷⁹ found that among 416 patients with T1 or T2 laryngeal cancers undergoing vertical partial laryngectomies, the failure rate was 23% if the AC was involved; higher than at other anatomic subsites. Studies on CO₂ TOLMS^{52-54,58,59,63} and studies on RT^{20,21,24,25,76} analyzed the involvement of the AC and concluded that its involvement did not result in a significantly lower overall survival rate. However, Hoffmann et al (96 patients) and Carta et al (105 patients), in large sample-sized studies, revealed a significantly increased risk for local recurrences in patients with extensive infiltration of the AC.^{59,63,80}

The vertical plane of the AC has been identified as a laryngeal subsite at risk for local treatment failures.⁸¹⁻⁸⁴ In the ventral compartment, cancer can easily diffuse superficially along the ventral mucosa containing blood vessels and glands; this diffusion usually follows a cranial-to-caudal direction. Moreover, if cancer reaches in depth the Broyles tendon, it can invade adjacent structures. Therefore, an early-stage carcinoma with involvement of the AC could penetrate the cartilage transforming a T1 tumor into a T4 switch, thus representing a

contraindication for CO₂ TOLMS. The impact of the AC involvement on prognosis in laryngeal cancer remains a topic with inconsistent results in the literature; a detailed stratification of tumors involving the AC needs to be investigated in further studies for all treatment modalities.⁸⁵

Limits of the Study

The main limitation of this review is the vast heterogeneity of selected studies. Radiotherapy studies have a large variety in technique, fraction size, and overall dose, while CO₂ TOLMS studies did not describe which resections were performed during surgery. Furthermore, there are no randomized trials or comparison studies; all the selected studies are retrospective case series. For this reason, formal statistical analysis and meta-analysis are inappropriate. It is very important to underline that in the majority of studies on CO₂ TOLMS, there was some selection of patients. Large T2 tumor or tumor with the involvement of AC may not be suitable for a transoral approach, and treatment must be individualized according to patient anatomy. Finally, there was heterogeneity in treatment details, treatment period, study design, and follow-up for both treatment modalities.

Conclusions

The current first-line treatments for early laryngeal cancer are CO₂ TOLMS and RT, while the role of OPL has greatly diminished in the last 20 years. This review suggests that CO₂ TOLMS should be encouraged in selected T2 patients, because LC is comparable but primary treatment with CO₂ TOLMS results in higher LP compared to primary treatment with RT. In conclusion, data suggest that involvement of the AC in the craniocaudal plane and T2b impaired vocal cord mobility have a poorer prognosis and LC compared to patients with T2a tumors for both CO₂ TOLMS and RT. Open partial laryngectomy should be proposed in selected patients affected by glottic cT2 with impaired mobility of vocal cords and suspected extension to the PGS. Further studies on cancers with the involvement of AC and impaired vocal cord are necessary to clarify their impact on oncological outcomes, and prospective randomized controlled studies for both treatment modality are required to confirm these results.

Authors' Note

The data sets used and/or analyzed during the current study are available from the corresponding author on reasonable request.


Declaration of Conflicting Interests


The author(s) declared no potential conflicts of interest with respect to the research, authorship, and/or publication of this article.

Funding

The author(s) received no financial support for the research, authorship, and/or publication of this article.

ORCID iD

Massimo Ralli  <https://orcid.org/0000-0001-8776-0421>

Francesca Yoshie Russo  <https://orcid.org/0000-0001-5244-2423>

References

- Higgins KM, Shah MD, Ogaick MJ, Enepekides D. Treatment of early-stage glottic cancer: meta-analysis comparison of laser excision versus radiotherapy. *J Otolaryngol Head Neck Surg.* 2009; 38(6):603-612.
- Feng Y, Wang B, Wen S. Laser surgery versus radiotherapy for T1-T2N0 glottic cancer: a meta-analysis. *ORL J Otorhinolaryngol Relat Spec.* 2011;73(6):336-342.
- Sjogren EV. Transoral laser microsurgery in early glottic lesions. *Curr Otorhinolaryngol Rep.* 2017;5(1):56-68.
- Warner L, Chudasama J, Kelly CG, et al. Radiotherapy versus open surgery versus endolaryngeal surgery (with or without laser) for early laryngeal squamous cell cancer. *Cochrane Database Syst Rev.* 2014;(12):CD002027.
- Hendriksma M, Heijnen BJ, Sjogren EV. Oncologic and functional outcomes of patients treated with transoral CO2 laser microsurgery or radiotherapy for T2 glottic carcinoma: a systematic review of the literature. *Curr Opin Otolaryngol Head Neck Surg.* 2018;26(2):84-93.
- Warner L, Lee K, Homer JJ. Transoral laser microsurgery versus radiotherapy for T2 glottic squamous cell carcinoma: a systematic review of local control outcomes. *Clin Otolaryngol.* 2017;42(3): 629-636.
- Amin MB, Greene FL, Edge SB, et al. The eighth edition AJCC Cancer Staging Manual: continuing to build a bridge from a population-based to a more “personalized” approach to cancer staging. *CA Cancer J Clin.* 2017;67(2):93-99.
- Wasserman JM, Wynn R, Bash TS, Rosenfeld RM. Levels of evidence in otolaryngology journals. *Otolaryngol Head Neck Surg.* 2006;134(5):717-723.
- Turesson I, Sandberg N, Mercke C, Johansson KA, Sandin I, Wallgren A. Primary radiotherapy for glottic laryngeal carcinoma stage I and II: a retrospective study with special regard to failure patterns. *Acta Oncol.* 1991;30(3):357-362.
- Fein DA, Mendenhall WM, Parsons JT, Million RR. T1-T2 squamous cell carcinoma of the glottic larynx treated with radiotherapy: a multivariate analysis of variables potentially influencing local control. *Int J Radiat Oncol Biol Phys.* 1993;25(4):605-611.
- Stevens G, Castle G, O'Brien CJ. Treatment of early carcinoma of the vocal cords by radiotherapy. *Australas Radiol.* 1994;38(2): 119-122.
- Klintonberg C, Lundgren J, Adell G, et al. Primary radiotherapy of T1 and T2 glottic carcinoma—analysis of treatment results and prognostic factors in 223 patients. *Acta Oncol.* 1996;35(Suppl 8):81-86.
- Burke LS, Greven KM, McGuiert WT, Case D, Hoen HM, Raben M. Definitive radiotherapy for early glottic carcinoma: prognostic factors and implications for treatment. *Int J Radiat Oncol Biol Phys.* 1997;38(5):1001-1006.
- Le QT, Fu KK, Kroll S, et al. Influence of fraction size, total dose, and overall time on local control of T1-T2 glottic carcinoma. *Int J Radiat Oncol Biol Phys.* 1997;39(1):115-126.
- Franchin G, Minatel E, Gobitti C, et al. Radiation treatment of glottic squamous cell carcinoma, stage I and II: analysis of factors affecting prognosis. *Int J Radiat Oncol Biol Phys.* 1998;40(3): 541-548.
- Sakata K, Oouchi A, Nagakura H, et al. Accelerated radiotherapy for T1, 2 glottic carcinoma: analysis of results with KI-67 index. *Int J Radiat Oncol Biol Phys.* 2000;47(1):81-88.
- Smee R, Bridger GP, Williams J, Fisher R. Early glottic carcinoma: results of treatment by radiotherapy. *Australas Radiol.* 2000;44(1):53-59.
- Haugen H, Johansson KA, Mercke C. Hyperfractionated-accelerated or conventionally fractionated radiotherapy for early glottic cancer. *Int J Radiat Oncol Biol Phys.* 2002;52(1): 109-119.
- Garden AS, Forster K, Wong PF, Morrison WH, Schechter NR, Ang KK. Results of radiotherapy for T2N0 glottic carcinoma: does the “2” stand for twice-daily treatment? *Int J Radiat Oncol Biol Phys.* 2003;55(2):322-328.
- Stoeckli SJ, Schnieper I, Huguenin P, Schmid S. Early glottic carcinoma: treatment according patient's preference? *Head Neck.* 2003;25(12):1051-1056.
- Chen MF, Chang JT, Tsang NM, Liao CT, Chen WC. Radiotherapy of early-stage glottic cancer: analysis of factors affecting prognosis. *Ann Otol Rhinol Laryngol.* 2003;112(10):904-911.
- Zouhair A, Azria D, Coucke P, et al. Decreased local control following radiation therapy alone in early-stage glottic carcinoma with anterior commissure extension. *Strahlenther Onkol.* 2004; 180(2):84-90.
- Frata P, Cellai E, Magrini SM, et al. Radical radiotherapy for early glottic cancer: Results in a series of 1087 patients from two Italian radiation oncology centers. II. The case of T2N0 disease. *Int J Radiat Oncol Biol Phys.* 2005;63(5):1387-1394.
- Murakami R, Nishimura R, Baba Y, et al. Prognostic factors of glottic carcinomas treated with radiation therapy: value of the adjacent sign on radiological examinations in the sixth edition of the UICC TNM staging system. *Int J Radiat Oncol Biol Phys.* 2005;61(2):471-475.
- Short S, Krawitz H, Macann A, et al. TN/TN glottic carcinoma: a comparison of two fractionation schedules. *Australas Radiol.* 2006;50(2):152-157.
- Tateya I, Hirano S, Kojima H, et al. Hyperfractionated radiotherapy for T2 glottic cancer for preservation of the larynx. *Eur Arch Otorhinolaryngol.* 2006;263(2):144-148.
- Dagan R, Morris CG, Bennett JA, et al. Prognostic significance of paraglottic space invasion in T2N0 glottic carcinoma. *Am J Clin Oncol.* 2007;30(2):186-190.
- Chera BS, Amdur RJ, Morris CG, Kirwan JM, Mendenhall WM. T1N0 to T2N0 squamous cell carcinoma of the glottic larynx treated with definitive radiotherapy. *Int J Radiat Oncol Biol Phys.* 2010;78(2):461-466.
- Jones DA, Mendenhall CM, Kirwan J, et al. Radiation therapy for management of t1-t2 glottic cancer at a private practice. *Am J Clin Oncol.* 2010;33(6):587-590.
- Khan MK, Koyfman SA, Hunter GK, Reddy CA, Saxton JP. Definitive radiotherapy for early (T1-T2) glottic squamous cell

- carcinoma: a 20 year Cleveland Clinic experience. *Radiat Oncol.* 2012;7:193.
31. Tong CC, Au KH, Ngan RK, et al. Definitive radiotherapy for early stage glottic cancer by 6 MV photons. *Head Neck Oncol.* 2012;4:23.
 32. Al-Mamgani A, van Rooij PH, Woutersen DP, et al. Radiotherapy for T1-2N0 glottic cancer: a multivariate analysis of predictive factors for the long-term outcome in 1050 patients and a prospective assessment of quality of life and voice handicap index in a subset of 233 patients. *Clin Otolaryngol.* 2013; 38(4):306-312.
 33. Douglas CM, Bernstein JM, Ormston VE, et al. Lack of prognostic effect of carbonic anhydrase-9, hypoxia inducible factor-1alpha and bcl-2 in 286 patients with early squamous cell carcinoma of the glottic larynx treated with radiotherapy. *Clin Oncol (R Coll Radiol).* 2013;25(1):59-65.
 34. Karasawa K, Kunogi H, Hirai T, et al. Radiotherapy with fraction size of 2.25 Gy in T1-2 laryngeal and hypopharyngeal cancer. *J Radiat Res.* 2013;54(4):684-689.
 35. Hoebers F, Rios E, Troost E, et al. Definitive radiation therapy for treatment of laryngeal carcinoma: impact of local relapse on outcome and implications for treatment strategies. *Strahlenther Onkol.* 2013;189(10):834-841.
 36. Higashino M, Kawata R, Lee K, Nishikawa S, Ichihara S, Uesugi Y. Radiotherapy concurrent with S-1 and radiotherapy alone for T2N0 glottic carcinoma: a retrospective comparative study. *Auris Nasus Larynx.* 2014;41(4):364-368.
 37. Moon SH, Cho KH, Chung EJ, et al. A prospective randomized trial comparing hypofractionation with conventional fractionation radiotherapy for T1-2 glottic squamous cell carcinomas: results of a Korean Radiation Oncology Group (KROG-0201) study. *Radiother Oncol.* 2014;110(1):98-103.
 38. Rutkowski T. Impact of initial tumor volume on radiotherapy outcome in patients with T2 glottic cancer. *Strahlenther Onkol.* 2014;190(5):480-484.
 39. Motegi A, Kawashima M, Arahira S, et al. Accelerated radiotherapy for T1 to T2 glottic cancer. *Head Neck.* 2015;37(4): 579-584.
 40. Ermis E, Teo M, Dyker KE, Fosker C, Sen M, Prestwich RJ. Definitive hypofractionated radiotherapy for early glottic carcinoma: experience of 55Gy in 20 fractions. *Radiat Oncol.* 2015;10: 203.
 41. Lim YJ, Wu HG, Kwon TK, et al. Long-Term Outcome of Definitive Radiotherapy for Early Glottic Cancer: Prognostic Factors and Patterns of Local Failure. *Cancer Res Treat.* 2015;47(4): 862-870.
 42. Harada A, Sasaki R, Miyawaki D, et al. Treatment outcomes of the patients with early glottic cancer treated with initial radiotherapy and salvaged by conservative surgery. *Jpn J Clin Oncol.* 2015;45(3):248-255.
 43. Potenza I, Franco P, Moretto F, et al. Exclusive Radiotherapy for Early-stage Glottic Cancer: A Single-institution Retrospective Analysis with a Focus on Voice Quality. *Anticancer Res.* 2015; 35(7):4155-4160.
 44. Zumsteg ZS, Riaz N, Jaffery S, et al. Carotid sparing intensity-modulated radiation therapy achieves comparable locoregional control to conventional radiotherapy in T1-2N0 laryngeal carcinoma. *Oral Oncol.* 2015;51(7):716-723.
 45. Sert F, Kaya I, Ozturk K, Esassolak M. Patterns of failure for early-stage glottic carcinoma: 10 years' experience in conformal radiotherapy era. *J Cancer Res Ther.* 2019;15(3):576-581.
 46. Eckel HE, Thumfart W, Jungehulsing M, Sittel C, Stennert E. Transoral laser surgery for early glottic carcinoma. *Eur Arch Otorhinolaryngol.* 2000;257(4):221-226.
 47. Peretti G, Nicolai P, Redaelli De Zinis LO, et al. Endoscopic CO2 laser excision for T1, and T2 glottic carcinomas: cure rate and prognostic factors. *Otolaryngol Head Neck Surg.* 2000;123(1 Pt 1):124-131.
 48. Motta G, Esposito E, Motta S, Tartaro G, Testa D. CO2 laser surgery in the treatment of glottic cancer. *Head Neck.* 2005; 27(8):733.
 49. Peretti G, Piazza C, Mensi MC, Magnoni L, Bolzoni A. Endoscopic treatment of cT2 glottic carcinoma: prognostic impact of different pT subcategories. *Ann Otol Rhinol Laryngol.* 2005; 114(8):579-586.
 50. Rodel RM, Steiner W, Muller RM, Kron M, Matthias C. Endoscopic laser surgery of early glottic cancer: involvement of the anterior commissure. *Head Neck.* 2009;31(5):583-592.
 51. Mantsopoulos K, Psychogios G, Koch M, Zenk J, Waldfahrer F, Iro H. Comparison of different surgical approaches in T2 glottic cancer. *Head Neck.* 2012;34(1):73-77.
 52. Peretti G, Piazza C, Cocco D, et al. Transoral CO(2) laser treatment for T(is)-T(3) glottic cancer: the University of Brescia experience on 595 patients. *Head Neck.* 2010;32(8):977-983.
 53. Blanch JL, Vilaseca I, Caballero M, Moragas M, Berenguer J, Sprekelsen MB. Outcome of transoral laser microsurgery for T2-T3 tumors growing in the laryngeal anterior commissure. *Head Neck.* 2011;33(9):1252-1259.
 54. Lucioni M, Marioni G, Bertolin A, Giacomelli L, Rizzotto G. Glottic laser surgery: outcomes according to 2007 ELS classification. *Eur Arch Otorhinolaryngol.* 2011;268(12):1771-1778.
 55. Canis M, Martin A, Ihler F, et al. Transoral laser microsurgery in treatment of pT2 and pT3 glottic laryngeal squamous cell carcinoma—results of 391 patients. *Head Neck.* 2014;36(6):859-866.
 56. Fang TJ, Courey MS, Liao CT, Yen TC, Li HY. Frozen margin analysis as a prognosis predictor in early glottic cancer by laser cordectomy. *Laryngoscope.* 2013;123(6):1490-1495.
 57. Lee HS, Chun BG, Kim SW, et al. Transoral laser microsurgery for early glottic cancer as one-stage single-modality therapy. *Laryngoscope.* 2013;123(11):2670-2674.
 58. Peretti G, Piazza C, Del Bon F, et al. Function preservation using transoral laser surgery for T2-T3 glottic cancer: oncologic, vocal, and swallowing outcomes. *Eur Arch Otorhinolaryngol.* 2013; 270(8):2275-2281.
 59. Hoffmann C, Cornu N, Hans S, Sadoughi B, Badoual C, Brasnu D. Early glottic cancer involving the anterior commissure treated by transoral laser cordectomy. *Laryngoscope.* 2016;126(8): 1817-1822.
 60. Ansarin M, Cattaneo A, De Benedetto L, et al. Retrospective analysis of factors influencing oncologic outcome in 590 patients with early-intermediate glottic cancer treated by transoral laser microsurgery. *Head Neck.* 2017;39(1):71-81.

61. Day AT, Sinha P, Nussenbaum B, Kallogjeri D, Haughey BH. Management of primary T1-T4 glottic squamous cell carcinoma by transoral laser microsurgery. *Laryngoscope*. 2017;127(3):597-604.
62. Chang CF, Chu PY. Predictors of local recurrence of glottic cancer in patients after transoral laser microsurgery. *J Chin Med Assoc*. 2017;80(7):452-457.
63. Carta F, Mariani C, Sambiagio GB, et al. CO2 Transoral Microsurgery for Supraglottic Squamous Cell Carcinoma. *Front Oncol*. 2018;8:321.
64. Pedregal-Mallo D, Sanchez Canteli M, Lopez F, Alvarez-Marcos C, Llorente JL, Rodrigo JP. Oncological and functional outcomes of transoral laser surgery for laryngeal carcinoma. *Eur Arch Otorhinolaryngol*. 2018;275(8):2071-2077.
65. Succo G, Crosetti E, Bertolin A, et al. Benefits and drawbacks of open partial horizontal laryngectomies, Part A: Early- to intermediate-stage glottic carcinoma. *Head Neck*. 2016;38(Suppl 1):E333-E340.
66. Giovanni A, Guelfucci B, Gras R, Yu P, Zanaret M. Partial frontolateral laryngectomy with epiglottic reconstruction for management of early-stage glottic carcinoma. *Laryngoscope*. 2001;111(4 Pt 1):663-668.
67. Crampette L, Garrel R, Gardiner Q, et al. Modified subtotal laryngectomy with cricohyoidoepiglottopexy—long term results in 81 patients. *Head Neck*. 1999;21(2):95-103.
68. Spector JG, Sessions DG, Chao KS, et al. Stage I (T1 N0 M0) squamous cell carcinoma of the laryngeal glottis: therapeutic results and voice preservation. *Head Neck*. 1999;21(8):707-717.
69. Smith JC, Johnson JT, Cognetti DM, et al. Quality of life, functional outcome, and costs of early glottic cancer. *Laryngoscope*. 2003;113(1):68-76.
70. Phillips TJ, Sader C, Brown T, et al. Transoral laser microsurgery versus radiation therapy for early glottic cancer in Canada: cost analysis. *J Otolaryngol Head Neck Surg*. 2009;38(6):619-623.
71. Diaz-de-Cerio P, Preciado J, Santaolalla F, Sanchez-Del-Rey A. Cost-minimisation and cost-effectiveness analysis comparing transoral CO(2) laser cordectomy, laryngofissure cordectomy and radiotherapy for the treatment of T1-2, N0, M0 glottic carcinoma. *Eur Arch Otorhinolaryngol*. 2013;270(4):1181-1188.
72. Campo F, D'Aguanno V, Greco A, Ralli M, de Vincentiis M. The Prognostic Value of Adding Narrow-Band Imaging in Transoral Laser Microsurgery for Early Glottic Cancer: A Review. *Lasers Surg Med*. 2019.
73. de Vincentiis M, De Virgilio A, Bussu F, et al. Oncologic results of the surgical salvage of recurrent laryngeal squamous cell carcinoma in a multicentric retrospective series: emerging role of supracricoid partial laryngectomy. *Head Neck*. 2015;37(1):84-91.
74. Silverman DA, Puram SV, Rocco JW, Old MO, Kang SY. Salvage laryngectomy following organ-preservation therapy—an evidence-based review. *Oral Oncol*. 2019;88():137-144.
75. McCoul ED, El GH. Meta-analysis of impaired vocal cord mobility as a prognostic factor in T2 glottic carcinoma. *Arch Otolaryngol Head Neck Surg*. 2009;135(5):479-486.
76. Gorphe P, Blanchard P, Breuskin I, Temam S, Tao Y, Janot F. Vocal fold mobility as the main prognostic factor of treatment outcomes and survival in stage II squamous cell carcinomas of the glottic larynx. *J Laryngol Otol*. 2015;129(9):903-909.
77. Rucci L, Romagnoli P, Casucci A, Ferlito A. Embryological study of the glottic site and clinical implications. *Oral Oncol*. 2004;40(10):1017-1025.
78. Allegra E, Ferrise P, Trapasso S, et al. Early glottic cancer: role of MRI in the preoperative staging. *Biomed Res Int*. 2014;2014:890385.
79. Laccourreye O, Weinstein G, Brasnu D, Trotoux J, Laccourreye H. Vertical partial laryngectomy: a critical analysis of local recurrence. *Ann Otol Rhinol Laryngol*. 1991;100(1):68-71.
80. Rucci L, Gammarota L, Gallo O. Carcinoma of the anterior commissure of the larynx: II. Proposal of a new staging system. *Ann Otol Rhinol Laryngol*. 1996;105(5):391-396.
81. Rucci L, Romagnoli P, Scala J. CO(2) laser therapy in Tis and T1 glottic cancer: indications and results. *Head Neck*. 2010;32(3):392-398.
82. Eckel HE. Local recurrences following transoral laser surgery for early glottic carcinoma: frequency, management, and outcome. *Ann Otol Rhinol Laryngol*. 2001;110(1):7-15.
83. Strong MS. Laser excision of carcinoma of the larynx. *Laryngoscope*. 1975;85(8):1286-1289.
84. Wolfensberger M, Dort JC. Endoscopic laser surgery for early glottic carcinoma: a clinical and experimental study. *Laryngoscope*. 1990;100(10 pt 1):1100-1105.
85. Hendriksma M, Sjogren EV. Involvement of the anterior commissure in early glottic cancer (Tis-T2): a review of the literature. *Cancers (Basel)*. 2019;11(9):pii: E1234.