

Embolization of iliac metastasis during lenvatinib treatment in patient with advanced Hürthle cell thyroid carcinoma

Rossella Rodia^{*,1,2}, Stefano Marini³, Fabiana Pani^{1,4}, Francesco Boi^{1,2} & Stefano Mariotti^{1,2}

¹Department of Medical Sciences & Public Health, Postgraduate School of Endocrinology & Metabolic Diseases, University of Cagliari, Cagliari, Italy

²Endocrinology Unit "Dulio Casula" Hospital, AOU Monserrato, Cagliari, Italy

³Department of Radiology, SS Trinità Hospital, ASSL Cagliari, Cagliari, Italy

⁴Division of Immunology, Department of Pathology, The Johns Hopkins School of Medicine, Ross Research Building-Room 656, 720 Rutland Avenue, Baltimore, MD 21205, USA

*Author for correspondence: rossellarodia@hotmail.it

Lenvatinib is a tyrosine kinase inhibitor (TKI) with antiproliferative and antiangiogenic effects indicated for the treatment of progressive, locally advanced or metastatic progressive thyroid carcinoma, refractory to radioactive iodine therapy. Antiangiogenic therapies induce ischemic necrosis of tumor tissue, with increased risk of hemorrhagic complications. The management of hemorrhagic risk is based on precautionary measures and for any surgical procedure, it is advised to interrupt the treatment in order to avoid complications. 'Flare-up' of tumor activity may follow TKI interruption. However, it is not known if continuing TKIs during minimally invasive interventions is safe. We report here the first case in which an embolization of metastasis is performed without interrupting lenvatinib treatment. The procedure was successful and free of complications.

First draft submitted: 29 March 2019; Accepted for publication: 8 July 2019; Published online: 6 August 2019

Keywords: antiangiogenic treatment • embolization • lenvatinib • metastatic thyroid cancer • patient safety

Differentiated thyroid carcinoma (DTC) has a generally good prognosis. The standard treatment for DTC is surgery followed by thyroid-stimulating hormone suppression therapy, and radioactive iodine (RAI) is often administered postoperatively to ablate the remaining thyroid tissue, eliminate any suspicious micrometastases or eliminate metastatic/recurrent disease. By contrast, patients developing recurrent or metastatic RAI refractory disease have a 10-year survival rate of only 15–20% [1,2]. Before the advent of tyrosine kinase inhibitors (TKIs), external beam radiotherapy [3,4] and volume reduction surgery were the only available remedies for RAI refractory DTC, while chemotherapy was mostly ineffective [4]. In 2014, sorafenib has been the first available multitargeted TKI [5], followed by lenvatinib, which was approved in 2015, concurring to the results of the Phase III SELECT study [6]. Lenvatinib targets VEGFR 1–3, FGFR1–4, PDGFR- α , RET rearranged during transfection and KIT, which are signaling networks implicated in tumor angiogenesis [6]. In patients treated with lenvatinib compared with those treated with the placebo, the Phase III SELECT study demonstrated significant amelioration in the median progression-free survival. Among other TKIs, lenvatinib inhibits FGFR1–4, therefore, it offers a potential chance to hamper the mechanism of resistance to the VEGF/VEGFR inhibitors. Besides, lenvatinib has a direct antioncogenic effect as it inhibits RET, thereby controlling tumor cell proliferation and blocking FGFR, and therefore modulating the tumor microenvironment [4,7,8].

The therapeutic use of lenvatinib is reserved to RAI-resistant metastatic carcinoma, with strict application rules in dosage and timing of use, due to various potential severe adverse events (AEs) that may lead to dose reduction up to therapy interruption [4,9]. Common AEs of lenvatinib include arterial hypertension, fatigue, proteinuria, nausea, decreased weight and abdominal pain, which may decrease the quality of life of patients and influence their acceptance of treatment [10–12]. In addition, care needs to be taken regarding hemorrhagic risk.

Table 1. Time course of the disease and of treatment.

Date	Disease course	Drug change	Locoregional procedures
2014	Advanced Hürthle cell thyroid carcinoma		Surgery; RAI (twice)
July 2014	RAI resistance and progression	Sorafenib (toxicity)	
September 2014		Sunitinib	
June 2015	Progression	Lenvatinib 24 mg/day	
January 2016	CT: tumor response		
June 2016	Adverse events	Lenvatinib 20 mg/day	
October 2016	CT: tumor response		
January 2017	Intolerance	Lenvatinib 14 mg/day	
July 2017	Persisting intolerance	Lenvatinib 10–14 mg/2 days	
April 2017	Increased vertebral and liver metastases. AE persistence		
January 2018			Thermoablation, IV liver segment metastasis
March 2018			Thermoablation, VI liver segment metastasis
May 2018	CT: L2 metastasis increased		
August 2018		Lenvatinib 4–10 mg/2 days from 5 days before the embolization to 1 week later	Embolization of the right lumbar artery
October 2018	CT: embolization success		
December 2018			EBRT of lumbar metastasis

AE: Adverse event; CT: Computed tomography; EBRT: External beam radiation therapy; RAI: Radioactive iodine.

Patient

A 48-year-old man affected by advanced Hürthle cell thyroid carcinoma underwent surgery (total thyroidectomy with lymphadenectomy of the central compartment and after bilateral cervical lymphadenectomy) and RAI therapy (Table 1). For the persistence of high thyroglobulin levels, the patient was submitted to another RAI treatment. At that time, the post-therapy whole body scan was negative and the disease became RAI refractory; metastatic bone and liver disease progressed. Therefore, first-line therapy with sorafenib was initiated in July 2014, but it was quickly discontinued due to severe skin toxicity. Subsequently, sunitinib was then administered in September 2014, but within 9 months the disease had further progression. Bisphosphonates could not be used because the patient needed important dental treatments. Although evidence is lacking, a multidisciplinary team with an oncologist and a radiologist decided to switch the patient to a nonconventional treatment with lenvatinib in June 2015, with a starting dosage of 24 mg/day. A CT scan in January 2016 showed shrinkage of metastases, in particular, a reduction in size from 26 to 14 mm of the VI liver segment lesion, from 34 to 20 mm of the IV liver segment lesion and from 106 × 82 mm to 93 × 56 mm of the right iliac bone metastasis. After 1 year, the lenvatinib dosage was reduced to 20 mg/day due to diarrhea grade 3 according to National Cancer Institute Common Toxicity Criteria (NCI-CTC). In October 2016, the patient performed a staging total body CT scan, which highlighted reduction of liver and bone metastases according to Response Evaluation Criteria in Solid Tumors (RECIST); the main metastatic sites (liver and right iliac bone metastases) decreased from 26 to 8 mm (VI liver segment), from 34 to 14 mm (IV liver segment) and from 106 × 82 mm to 85 × 46 mm (right iliac bone). In January 2017, weight loss, diarrhea and asthenia required a dosage reduction to 14 mg/day, and after 6 months, in July 2017, there was a further reduction to 10/14 mg on alternate days due to persistent AEs (weight loss, diarrhea, vomiting and asthenia). After 6 months (from October 2016 to April 2017) of stable disease, there was a dimensional increase of vertebral metastasis in L2 (from 36 to 42 mm), and 7 months later (November 2017), there was an increase in the size of liver metastases (12-mm VI liver segment metastasis and 27-mm IV liver segment metastasis). The AEs persisted and lenvatinib dose could not be changed. For this reason, in January 2018, the patient underwent his first thermoablation of the IV liver segment metastasis. In March 2018, he underwent a second thermoablation of the VI liver segment metastasis. After these procedures, a complete replacement of the lesions with necrotic parenchyma was observed.

During thermoablations, we continued with the same dose of lenvatinib with no subsequent procedural complications. In May 2018, a controlled CT scan showed increase in size of the known vertebral lesion in L2 (72 × 39 × 33 mm), which reduced the diameters of the spinal canal and also a volumetric increase of right iliac bone metastasis (110 × 85 × 110 mm) (Figure 1). Neurosurgeons suggested locoregional treatment of this

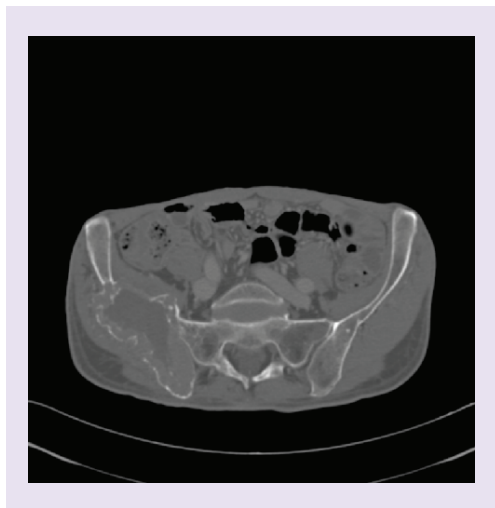


Figure 1. CT scan prior to embolization demonstrates a large locally invasive mass of right iliac bone.

metastasis rather than surgery. The multidisciplinary team decided to give priority to iliac bone metastasis treatment because that lesion was so big and hypervascularized that the progression risk could be higher than lumbar lesion. In August 2018, embolization of the right lumbar artery with subsequent devascularization of the cranial portion of the lesion (Figure 2) was performed (after the patient had been informed about risk and had accepted the procedure). In the absence of any specific guideline, to avoid tumor flare up we decided to not interrupt lenvatinib, but, given the hemorrhagic risk due to hypervascularization of the metastasis, the dosage was reduced from 10/14 to 4/10 mg on alternate days from 5 days before the embolization to 1 week later. The embolization was successful, and the CT scan performed in October 2018 showed necrosis of the cranial portion of the iliac lesion (Figure 3). No complications were observed after 3 months of follow-up. In December 2018, the lumbar metastasis was treated by EBRT.

Discussion

Clinical studies have demonstrated the essential role of angiogenesis in tumor progression and metastasis [13,14]. This process is principally guided by VEGF; therefore, angiogenesis inhibitors targeting the VEGF pathway have been taken into great consideration [15]. Although angiogenesis inhibitors have a lower toxicity than traditional chemotherapy agents, one of the most common AEs of these agents are hemorrhagic events [15–17]. The meta-analysis by Qi *et al.* [18] demonstrated a significant association between anti-VEGF TKIs and increased risk of bleeding [19]. The hemorrhagic risk seems to be correlated with arterial high blood pressure and concomitant thrombopenia [20]. Our patient did not have alterations in blood parameters but had arterial hypertension before starting lenvatinib, and there was an increase in arterial high blood pressure after the introduction of that therapy, which was well controlled with antihypertensive drugs. The management of hemorrhagic risk is essentially based on precautionary measures. We know that for any surgical procedure, interruption of antiangiogenic therapies is advised in order to avoid hemorrhagic complications [20], even if there is no unanimous consent about the period in which the drug should be discontinued, ranging from 24–48 h to 4 weeks before and 3–4 weeks later [20,21].

After a careful review of medical literature, we have not found guidelines to optimize lenvatinib treatment during minimally invasive procedure such as embolization, in which there is a vascular necrosis that may increase its intrinsic hemorrhagic risk. Since, like other AEs, the hemorrhagic risk of lenvatinib is dose dependent, in the absence of current recommendations we decided to reduce lenvatinib dose without interrupting the drug administration, in order to avoid flare up of tumor activity [22,23]. Indeed, when inhibitory effect of the antiangiogenic drug is removed, there is a rebound phenomenon regarding the blood vessels. Since blocking VEGF or VEGFR leads to apoptosis of endothelial cells and decrease in vascular diameters, cessation of antiangiogenic therapy leads to an increase of vascular density and tumor blood flow rate [24], showing rapid vascular regrowth of tumors [25] that may lead to early relapse and disease progression. Our management of lenvatinib therapy with dose reduction, in order to avoid hemorrhagic and ‘flare-up’ risk, appeared to be safe for our patient even after 3 months of follow-up. To the best of our knowledge, there is no previous clinical case dealing with the management of lenvatinib treatment during a metastasis embolization. The lack of scientific evidence on many practical problems linked to routine

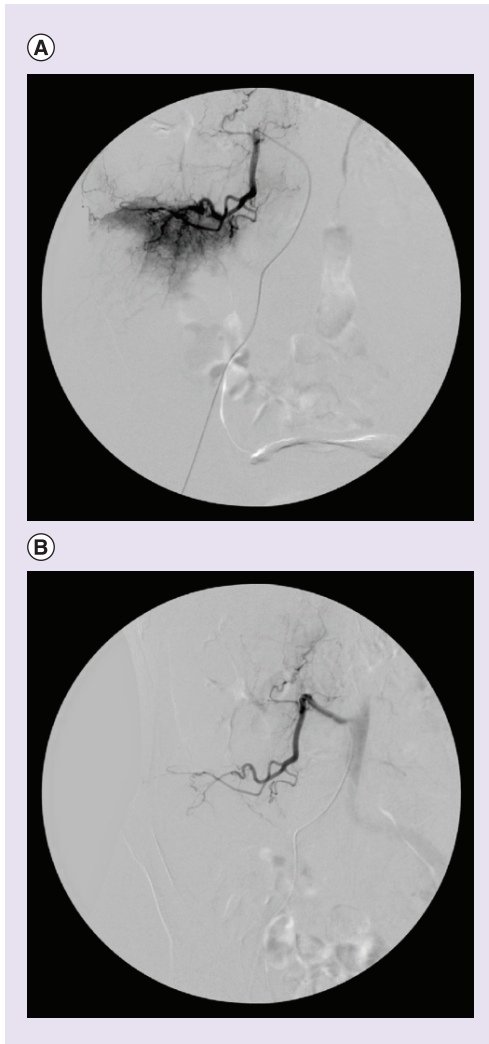


Figure 2. Selective angiography of the right lumbar artery. (A) Prior to embolization, shows vascularization of the cranial portion of the iliac metastasis and **(B)** postembolization, shows devascularization of the cranial portion of the lesion.

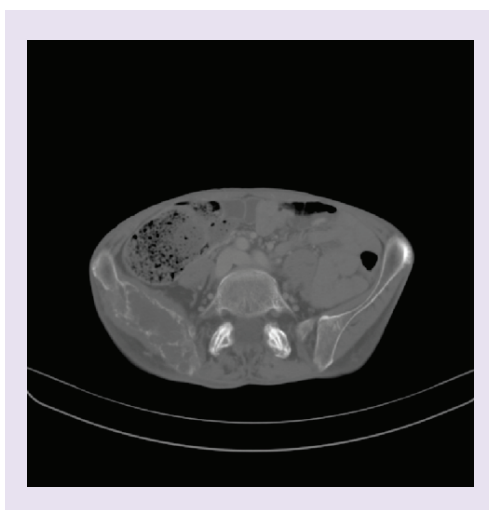


Figure 3. CT scan after embolization demonstrates response of right iliac metastasis with necrosis of the cranial portion of the lesion.

clinical use of lenvatinib strengthens the need of recommendations based on clinical experience in order to suitably administrate the therapy, and to optimize the dosage-limiting potential of AEs.

Summary points

- Antiangiogenic therapies induce ischemic necrosis of tumor tissue, with increased risk of hemorrhagic complications.
- The management of hemorrhagic risk is based on precautionary measures and for any surgical procedure; it is advised to interrupt the treatment in order to avoid complications.
- ‘Flare-up’ of tumor activity may follow tyrosine kinase inhibitor interruption.
- In a patient with radioactive iodine-resistant metastatic thyroid carcinoma, embolization of metastasis was performed without interrupting lenvatinib treatment, in order to reduce the risk of ‘flare up’.
- The procedure was successful and free of complications.

Financial & competing interests disclosure

S Mariotti received honorarium from Eisai for lecturing in Meetings on differentiated thyroid carcinoma treatment. The authors have no other relevant affiliations or financial involvement with any organization or entity with a financial interest in or financial conflict with the subject matter or materials discussed in the manuscript apart from those disclosed.

Editorial assistance was provided by A Shah and L Giacomelli (Polistudium srl, Milan, Italy), on behalf of Content Ed Net. This assistance was supported by Eisai. The supporting company was not given the opportunity to revise the manuscript and had no role in the decision to submit.

Informed consent disclosure

The patient gave written informed consent to describe his case.

Open access

This work is licensed under the Attribution-NonCommercial-NoDerivatives 4.0 Unported License. To view a copy of this license, visit <http://creativecommons.org/licenses/by-nc-nd/4.0/>

References

Papers of special note have been highlighted as: ● of interest; ●● of considerable interest

1. Gruber JJ, Colevas AD. Differentiated thyroid cancer: focus on emerging treatments for radioactive iodine-refractory patients. *Oncologist* 20(2), 113–126 (2015).
2. Schmidt A, Iglesias L, Klain M, Pitoia F, Schlumberger MJ. Radioactive iodine-refractory differentiated thyroid cancer: an uncommon but challenging situation. *Arch. Endocrinol. Metab.* 61(1), 81–89 (2017).
3. Sia MA, Tsang RW, Panzarella T, Brierley JD. Differentiated thyroid cancer with extrathyroidal extension: prognosis and the role of external beam radiotherapy. *J. Thyroid Res.* 183461, 1–7 (2010).
4. Tori M, Shimo T. Long-term efficacy of lenvatinib for recurrent papillary thyroid carcinoma after multimodal treatment and management of complications: a case report. *BMC Cancer* 18, 698 (2018).
- **Reports a real-life experience with lenvatinib.**
5. Brose MS, Nutting CM, Jarzab B *et al.* Sorafenib in radioactive iodine-refractory, locally advanced or metastatic differentiated thyroid cancer: a randomised, double-blind, Phase III trial. *Lancet* 384(9940), 319–328 (2014).
6. Schlumberger M, Tahara M, Wirth LJ *et al.* Lenvatinib versus placebo in radioiodine-refractory thyroid cancer. *N. Engl. J. Med.* 372(7), 621–630 (2015).
- **This trial demonstrates the efficacy of lenvatinib in radioactive iodine-resistant thyroid carcinoma.**
7. Tohyama O, Matsui J, Kodama K *et al.* Antitumor activity of lenvatinib (e7080): an angiogenesis inhibitor that targets multiple receptor tyrosine kinases in preclinical human thyroid cancer models. *Thyroid Res.* 638747, 1–13 (2014).
8. Stjepanovic N, Capdevila J. Multikinase inhibitors in the treatment of thyroid cancer: specific role of lenvatinib. *Biologics* 8, 129–139 (2014).
9. Brose MS, Smit J, Lin CC *et al.* Timing of multikinase inhibitor initiation in differentiated thyroid cancer. *Endocr. Relat. Cancer* 24(5), 237–242 (2017).
10. Jasim S, Ozsari L, Habra MA. Multikinase inhibitors use in differentiated thyroid carcinoma. *Biologics* 8, 281–291 (2014).
11. Carneiro RM, Carneiro BA, Agulnik M, Kopp PA, Giles FJ. Targeted therapies in advanced differentiated thyroid cancer. *Cancer Treat. Rev.* 41, 690–698 (2015).
12. Zhu C, Ma X, Hu Y *et al.* Safety and efficacy profile of lenvatinib in cancer therapy: a systematic review and meta-analysis. *Oncotarget* 7(28), 44545–44557 (2016).

13. Folkman J. Role of angiogenesis in tumor growth and metastasis. *Semin. Oncol.* 29, 15–18 (2002).
- **A fundamental tool to understand angiogenesis role in tumor biology.**
14. Zetter PBR. Angiogenesis and tumor metastasis. *Ann. Rev. Med.* 49, 407–424 (1998).
15. Qi WX, Tang LN, Sun YJ *et al.* Incidence and risk of hemorrhagic events with vascular endothelial growth factor receptor tyrosine-kinase inhibitors: an up-to-date meta-analysis of 27 randomized controlled trials. *Ann. Oncol.* 24, 2943–2952 (2013).
16. Duffy A, Wilkerson J, Greten TF. Hemorrhagic events in hepatocellular carcinoma patients treated with anti-angiogenic therapies. *Hepatology* 57, 1068–1077 (2012).
17. Elice F, Rodeghiero F. Side effects of anti-angiogenic drugs. *Thromb. Res.* 129, S50–S53 (2012).
18. Qi WX, Sun YJ, Tang LN, Shen Z, Yao Y. Risk of gastrointestinal perforation in cancer patients treated with vascular endothelial growth factor receptor tyrosine kinase inhibitors: a systematic review and meta-analysis. *Crit. Rev. Oncol. Hematol.* 89, 394–403 (2014).
19. Capdevila J, Newbold K, Licitra L *et al.* Optimisation of treatment with lenvatinib in radioactive iodine-refractory differentiated thyroid cancer. *Cancer Treat. Rev.* 69, 164–176 (2018).
20. Ayllon J, Pignot G. Anti-angiogenic therapies and hemorrhagic risk. *Prog. Urol.* 20(Suppl. 1), S20–S22 (2010).
21. Pignot G, Leuret T, Chekulaev D *et al.* Healing and targeted therapies: management in perioperative period? *Prog. Urol.* 21, 166–172 (2011).
22. Wolter P, Beuselink B, Pans S, Schöffski P. Flare-up: an often unreported phenomenon nevertheless familiar to oncologists prescribing tyrosine kinase inhibitors. *Acta Oncol.* 48(4), 621–624 (2009).
23. Uchida T, Yamaguchi H, Nagamine K *et al.* Rapid pleural effusion after discontinuation of lenvatinib in a patient with pleural metastasis from thyroid cancer. *Endocrinol. Diabetes Metab. Case Rep.* doi:10.1530/EDM-18-0158 (2019) (Epub ahead of print).
24. Desai IME, Mulder SF, Stillebroer AB *et al.* The reverse side of the victory: flare up of symptoms after discontinuation of sunitinib or sorafenib in renal cell cancer patients. A report of three cases. *Acta Oncol.* 48(6), 927–931 (2009).
25. Mancuso MR, Davis R, Norberg SM *et al.* Rapid vascular regrowth in tumours after reversal of VEGF inhibition. *J. Clin. Invest.* 116, 2610–2621 (2006).