



Contents lists available at ScienceDirect

## International Journal of Surgery Case Reports

journal homepage: [www.casereports.com](http://www.casereports.com)

# First-in-man permanent laparoscopic fixation free obliteration of inguinal hernia defect with the 3D dynamic responsive implant ProFlor-E®. Case report

Giuseppe Amato<sup>a,\*</sup>, Giorgio Romano<sup>b</sup>, Piergiorgio Calò<sup>c</sup>, Giuseppe Di Buono<sup>b</sup>, Antonino Agrusa<sup>b</sup>

<sup>a</sup> Postgraduate School of General Surgery, University of Cagliari, Italy

<sup>b</sup> Department of Surgical, Oncological and Oral Sciences, University of Palermo, Italy

<sup>c</sup> Department of General Surgery, University of Cagliari, Italy

## ARTICLE INFO

## Article history:

Received 4 June 2020

Received in revised form 22 July 2020

Accepted 23 July 2020

Available online 19 August 2020

## Keywords:

Inguinal hernia repair

Laparoscopic

Fixation free hernia repair

ProFlor prosthesis

Dynamic responsiveness

Regenerative scaffold

## ABSTRACT

**INTRODUCTION:** In the case of inguinal hernia recurrence after primary anterior repair, international guidelines strongly suggest a posterior laparoscopic approach. The 3D dynamic-responsive prosthesis for inguinal hernia repair ProFlor-E® has recently been introduced to the market. The present report describes the results of the first-in-man laparoscopic inguinal hernia repair carried out with ProFlor-E®. **PRESENTATION OF CASE:** A 71-year-old male Caucasian presented with recurrent inguinal hernia after primary anterior repair. A fixation free TAPP procedure with ProFlor-E® was planned. Implant delivery and placement to obliterate the defect was quick and safe. Postoperatively, starting from 2nd postop day, pain was practically absent allowing quick return to normal activities. During follow up, US and MRI scans confirmed the permanence of ProFlor-E® in the hernial gap. During 16-month follow-up no complications were reported.

**DISCUSSION:** Flat meshes used to reinforce the herniated inguinal area is a well-established concept. Notwithstanding, such static and passive implants leave the defect patent and cause specific complications related to mesh fixation and uncontrolled poor quality fibrotic ingrowth. ProFlor-E® respects the inguinal physiology resolving these issues. Its centrifugal expansion and dynamic responsiveness allows for fixation-free defect obliteration, thus avoiding complications, above all tissue tear, bleeding, mesh invagination, discomfort and chronic pain. In accord with the degenerative pathogenesis of hernia disease, by acting as a regenerative scaffold, ProFlor-E® restores the inguinal barrier promoting the regeneration of the typical inguinal components.

**CONCLUSION:** This initial experience seems to prove that ProFlor-E® can also be used with the laparoscopic approach achieving excellent results.

© 2020 The Author(s). Published by Elsevier Ltd on behalf of IJS Publishing Group Ltd. This is an open access article under the CC BY-NC-ND license (<http://creativecommons.org/licenses/by-nc-nd/4.0/>).

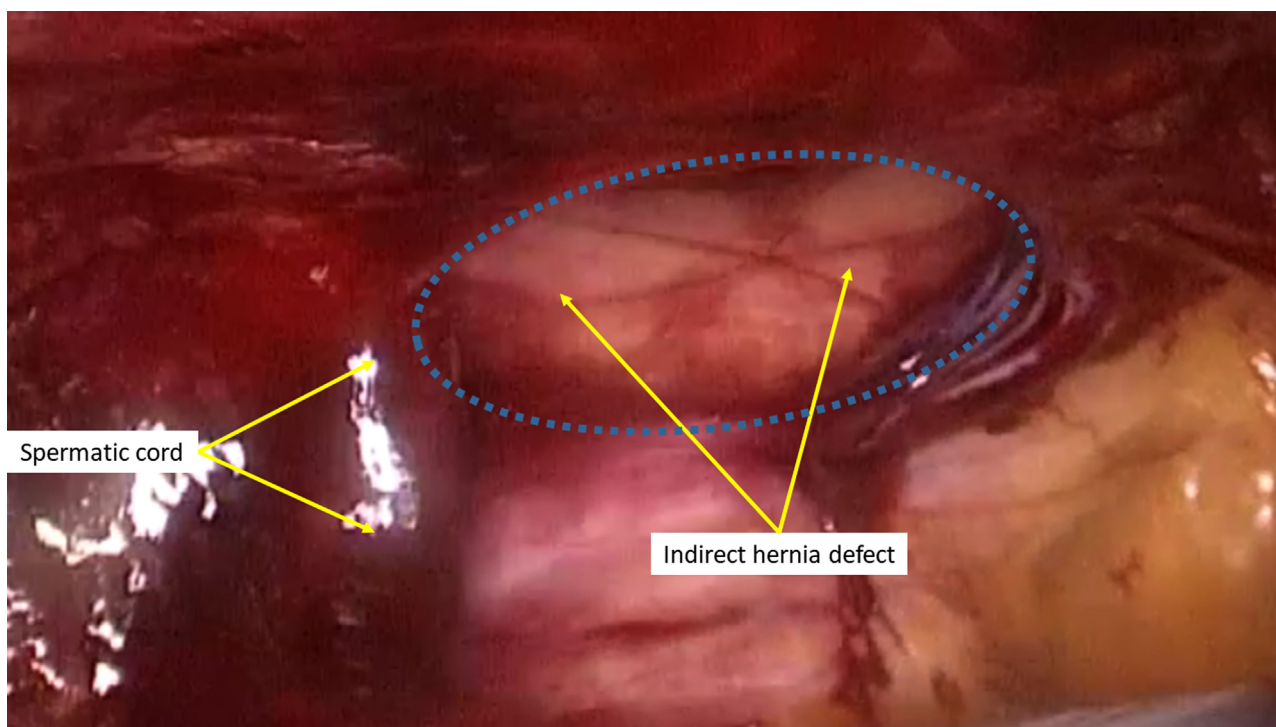
## 1. Introduction

Groin protrusion is one of the most common diseases. Millions of surgical inguinal hernia repair procedures are carried out yearly worldwide, but there is no agreement concerning surgical management and prosthetics used for primary repair. On the contrary, there is wide consensus concerning the type of repair technique to be adopted in the case of recurrence, with international guidelines stating that, in case of recurrence after open anterior procedure, a posterior (open or laparoscopic) approach is indicated [1–3].

Conversely, recurrence after posterior repair technique should be managed with open anterior approach. Several concerns related to prosthetic hernia repair are evident for both kinds of procedural approaches, including the use of flat and static meshes fixated to the highly sensitive myotendineal inguinal surround, which are the source of frequent early complications, like tissue tear or bleeding, and late adverse events such as motile impairment, discomfort or chronic pain [4–6]. Regarding the laparoscopic approach, mesh fixation with tacks seems to further increase tissue tear and post-operative pain [3]. Additionally, tack detachment may be followed by mesh invagination and increased risks of recurrences [7]. Also, poor quality biological response producing a hard scare plate due to uncontrolled foreign body reaction might possibly lead to discomfort and chronic pain [8]. To overcome these incongruences, the 3D dynamic-responsive prosthesis ProFlor-E® (Insightra Medical Inc. - Clarksville, TN USA) has recently been introduced to the

\* Corresponding author at: Via Rapisardi 66, I, 90144, Palermo, Italy.

E-mail addresses: [amatomed@gmail.com](mailto:amatomed@gmail.com) (G. Amato), [giorgio.romano@unipa.it](mailto:giorgio.romano@unipa.it) (G. Romano), [pgcalo@tiscali.it](mailto:pgcalo@tiscali.it) (P. Calò), [giuseppe.dibuono@unipa.it](mailto:giuseppe.dibuono@unipa.it) (G. Di Buono), [agrusa.antonino@unipa.it](mailto:agrusa.antonino@unipa.it) (A. Agrusa).



**Fig. 1.** Preperitoneal view of recurrent indirect hernia defect left.

market. Made from low weight large porous polypropylene, it is composed of a multilamellar cylindrical 3D core, 15 mm thick, with 2 different longitudinal dimensions, 25 or 40 mm. On one surface, the center of the implant core is connected to a large oval flat mesh measuring  $8 \times 10$  cm. This flat part of the prosthesis is intended for coverage of the posterior inguinal area counterfacing the peritoneal sheath. The 3D core of ProFlor-E<sup>®</sup> is arranged to be compressible on both planes, longitudinal and transverse, therefore it is intrinsically provided with dynamic responsivity since it contracts and relaxes in unison with impulses received from the surrounding environment. Due to its proprietary centrifugal expansion it can be positioned fixation free into the hernia defect for permanent obliteration [9–11]. The biological response of ProFlor, although made from the same biocompatible polypropylene material used for flat meshes, is completely different from conventional hernia prostheses. Enhanced quality of tissue ingrowth has been repeatedly demonstrated in many scientific reports that clearly evidence the development of newly formed muscles, vessels and nerves in ProFlor fabric [12–14]. The benefits of open inguinal hernia repair with ProFlor have already been described in recently published clinical studies [9,10,15]. Aiming to further widen indications for the use of this 3D dynamic responsive prosthesis, a first-in-man laparoscopic attempt to repair a recurrent inguinal hernia after open anterior approach was planned with ProFlor E. This study is reported in line with SCARE 2018 criteria [16].

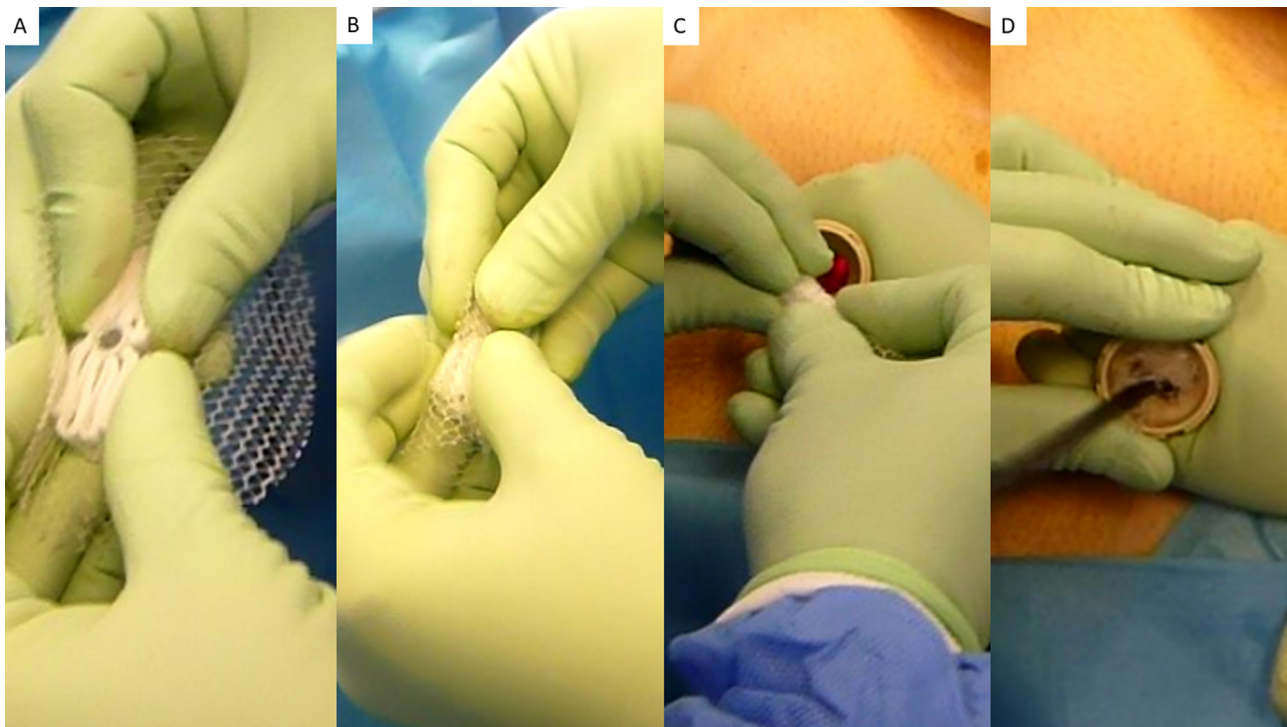
## 2. Case report

A 71-year-old Caucasian man, who one year previously underwent open anterior inguinal hernia repair left with placement of a flat mesh, came to our observation with referred pain during normal daily activity and a palpable mass in correspondence of the already operated groin. On clinical examination, an obstructed hernia protrusion was identified. US and CT scans confirmed diagnosis. CT scan also helped measure the hernia defect, which was 30.5 mm. Defect assessment allowed for the preoperative choice of the ProFlor-E<sup>®</sup> dimension to be used, in this case the 40 mm

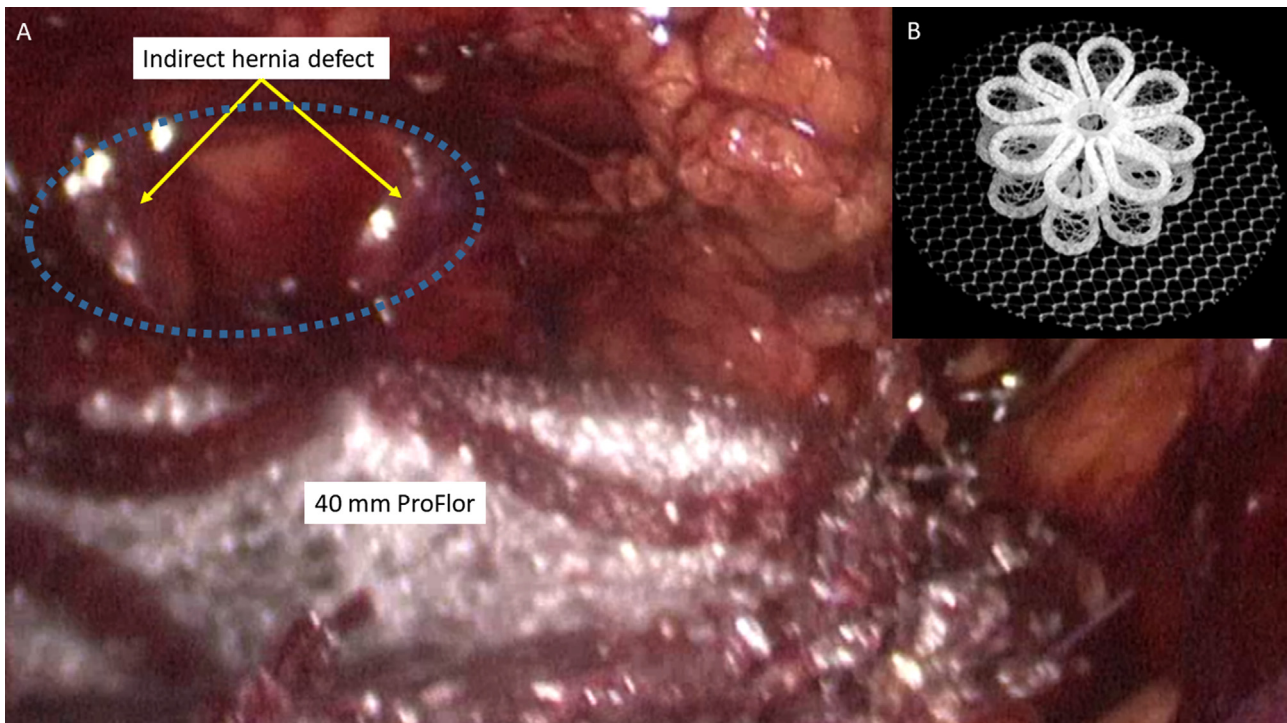
type. In absence of comorbidity or medical therapy for other diseases, all preoperative clinical examinations were in normal range. Given the previous anterior repair, a laparoscopic TAPP approach under general anesthesia using ProFlor-E<sup>®</sup> was selected. The patient was positioned in supine decubitus with closed legs and urinary catheter. Pneumoperitoneum was achieved by placing a 10-mm trocar with trans-umbilical open access. Another 5-mm trocar was positioned in the left flank and one 12 mm trocar in the right flank. The surgeon was on the right side and camera operator on left side. From exploration of the abdominal cavity, the diagnosed recurrent defect in the left lateral fossa inguinalis was identified. Then, a peritoneal flap from anterior superior iliac spine to plica umbilicalis medialis was prepared. After parietalization of the spermatic vessels the hernia sac was fully dissected and the previously assessed defect diameter of ca 30 mm was confirmed (Fig. 1). No others defects in the inguinal backwall were identified.

At this stage, the ProFlor-E<sup>®</sup> was prepared to be delivered into the abdominal cavity through the 12 mm trocar on the right flank. To allow the 40 mm wide, 15 mm thick prosthesis to be funneled across the 12 mm trocar channel, the implant core was squeezed with the fingers along its longitudinal axis reaching a thickness of ca 9 mm (Fig. 2A), then the connected flat mesh was rolled upon the squeezed core (Fig. 2B). The compressed, rolled ProFlor-E<sup>®</sup> configuration was brought close to the 12 mm trocar and introduced in screwing mode into the trocar to be finally funneled through the channel with a forceps (Fig. 2C, D). Once delivered into the abdominal cavity, the procedure continued by introducing the 3D prosthesis into the hernia defect (Fig. 3). This maneuver was carried out easily by holding the central connection point of the flat mesh to ProFlor's core with one pair of forceps and directing the prosthesis into the defect with a second forceps. The 3D structure of the implant was simply pushed into the defect until it was positioned with full thickness. A final adjustment of ProFlor-E<sup>®</sup> core to face the edges to the defect border was made (Fig. 4). To demonstrate that ProFlor's E<sup>®</sup> core was firmly lodged into the defect, the connected flat mesh was repeatedly pulled with a forceps trying to dislodge





**Fig. 2.** Preparing ProFlor-E® for the delivery into the abdominal cavity. A: The implant core is squeezed along its longitudinal axis. B: The connected flat mesh is rolled upon the squeezed core. C: The compressed and rolled ProFlor-E® is being approached to the 12 mm trocar. D: ProFlor-E® has been introduced into the trocar with screwing maneuver and is being funneled through the channel with a forceps.

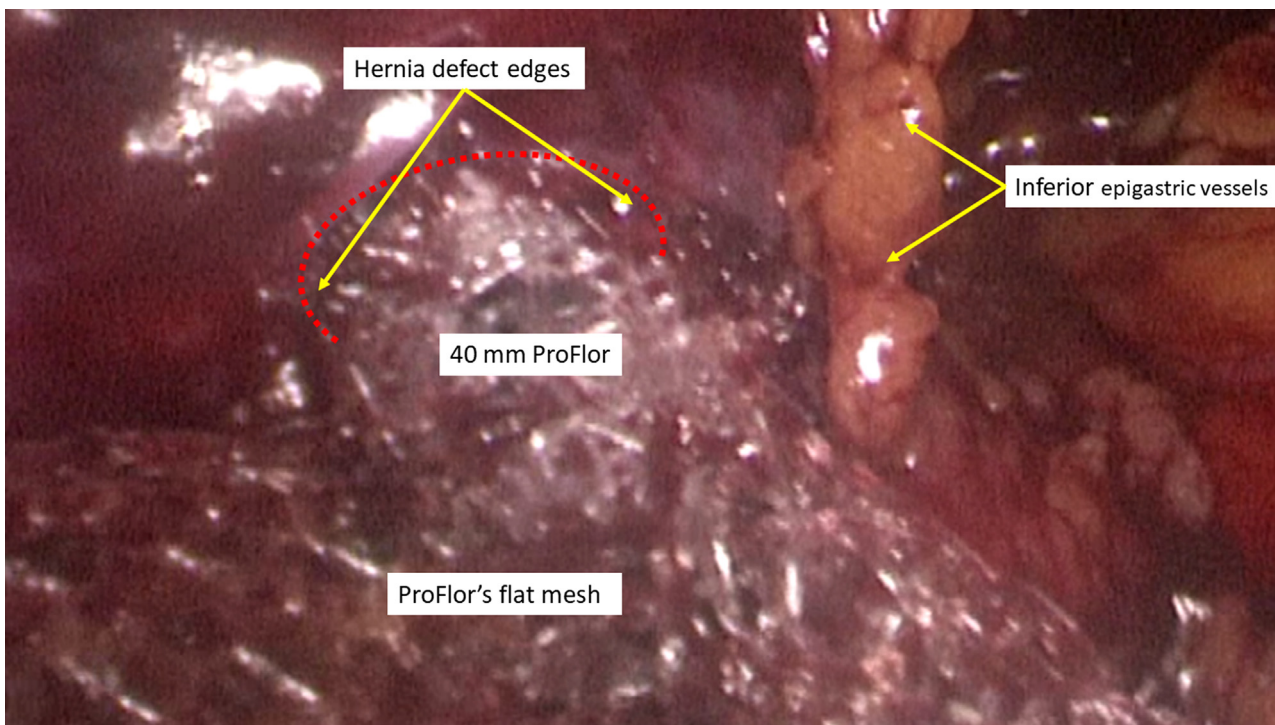


**Fig. 3.** A: ProFlor E is approached to the hernia defect. – B: the outline of 40 mm ProFlor prosthesis.

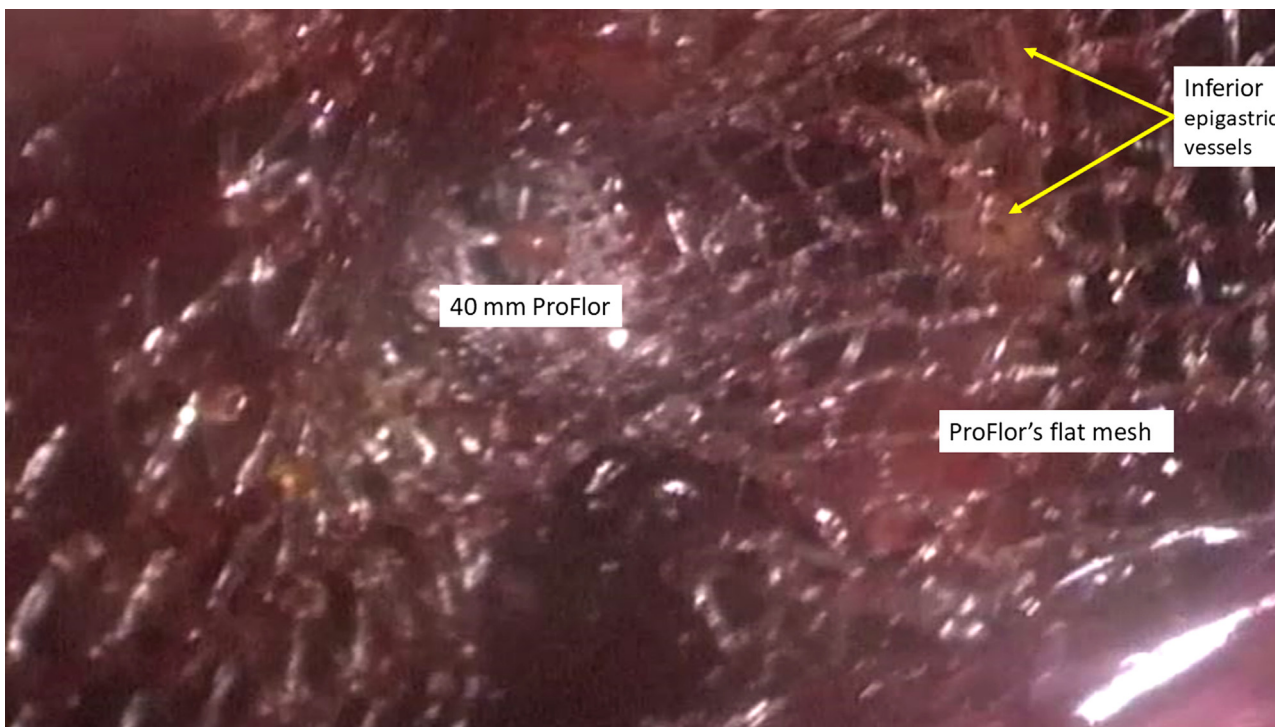
the implant, which remained firm in the defect. This maneuver confirmed that the compressed 3D core stayed put in the hernial gap and could not be removed. To complete the procedure, the connected flat mesh was deployed to cover the remaining surface of the inguinal backwall (Fig. 5). Of note, the 8 × 10 cm surface of the oval shaped connected flat mesh was large enough to broadly overlap all

three inguinal fossae and the femoral ring. Thanks to its proprietary centrifugal expansion, ProFlor-E® results self-retaining, therefore no fixation was needed to hold both parts of the prosthesis in place. At the end of the procedure, the peritoneal flap was closed over the deployed ProFlor-E® with absorbable barbed suture. Despite being the first-in-man attempt with this new approach, the time





**Fig. 4.** ProFlor-E® core fully obliterated the whole hernia defect. The connected flat mesh lies folded partially close to the inferior epigastric vessels.



**Fig. 5.** The placement of ProFlor-E® has been accomplished: the implant core occupies the hernial gap while its connected flat mesh fully covers the posterior inguinal backwall.

needed to delivery and deploy the 3D prosthesis into the hernia defect was less than 3 min. No abdominal drain was left and urinary catheter was removed at the end of surgical procedure. The procedure was carried out by a senior consultant surgeon with several years of surgical experience in the field. The patient was discharged within 24 h after the surgical procedure. In the early postoperative phase, no adverse event occurred and, above all, postoperative pain

score was very low since the patient declared to be without pain free starting from 2nd postop. day. Therefore, return to daily activities occurred within the first week. During follow up, repeated US control and one MRI carried out one year postop. confirmed the perfect position of ProFlor E® fully occupying the former site of protrusion in the inguinal backwall. On the last follow-up control (16 months later) patient showed excellent general clinical condi-

tion and, above all, no pain or discomfort by motion, no chronic pain, no clinical evidence of recurrence.

### 3. Discussion

The conventional concept of prosthetic inguinal hernia repair is reinforcing the groin by deploying a synthetic flat mesh to cover the herniated groin. Nevertheless, some aspects of this therapeutic strategy seem to be in conflict with physiology and pathogenesis of hernia disease. Fixation of the mesh with sutures or tacks upon the highly motile, sensitive surround of the groin is likely to induce painful impairment of physiological inguinal kinetics. Being flat and passive, fixated conventional hernia prosthetics do not cope with the movements of the groin and, especially if laparoscopic repair is being considered, meshes should be large enough to assure broad defect overlap. However, even if covered by mesh, in conventional repair the hernia opening remains patent. In laparoscopic inguinal hernia repair, apart from expensive and short acting fibrin sealants, tack fixation is the most used method [17]. Helical titanium tacks provide stronger fixation than absorbable devices, but under visceral pressure fixation points are put under tension and may detach. Increased risks of mesh invagination and un-coverage of the hernial gap are the consequences. Ineffective mesh fixation by defect patency is considered one of the most common causes of recurrence [7,8]. Furthermore, detached titanium tacks can also migrate into the abdominal cavity thereby increasing the risk of intestinal obstruction or perforation [18].

Another controversial aspect of inguinal hernia repair with conventional flat meshes concerns the inflammatory response leading to a typical foreign body reaction with fibrotic apposition in the implant fabric within weeks. Mesh shrinkage is the effect of this graft-versus-host reaction [19]. Even though this poor quality fibrotic ingrowth could be reputed suitable for reinforcing a weakened area, this has nothing to do with what is expected for the cure of the degenerative source of hernia disease [20–26]. Stopping degeneration and inducing regeneration should be the target to resolve degenerative damage causing a hole in the muscular barrier of the groin.

All described deficiencies of the conventional inguinal hernia repair concept seem to be resolved with the ProFlor-E<sup>®</sup> prosthesis, which, being self-retaining, does not need fixation and is not perceived by patients as it moves in physiological harmony with the groin. Acting as a regenerative scaffold, it is pathogenetically coherent since it induces an enhanced biological response with development of newly formed vessels, mature muscular and nervous structures to definitely fill the hernial gap [12–14]. However, by specifically considering ProFlor's E<sup>®</sup> use in laparoscopic inguinal hernia repair, an indisputable advantage emerges compared to conventional flat mesh repair: the laparoscopic ProFlor technique appears to be the sole hernia repair procedure that allows permanent obliteration of the hernial opening in fixation free fashion. These features seem decisive for achieving a dramatic decrease of postoperative pain and complications.

### 4. Conclusion

The described first-in-man use of the 3D dynamic responsive prosthesis ProFlor-E<sup>®</sup> was intended as a feasibility attempt with the aim of establishing an advanced, ameliorating treatment concept for laparoscopic inguinal hernia repair. In accordance with international guidelines, for the first case of laparoscopic ProFlor hernia repair technique a patient suffering from recurrent inguinal hernia after open anterior approach was chosen. The simple, quick and safe surgical procedure, as well as the excellent postoperative results acquired during 16 months follow-up appear to confirm the

laparoscopic ProFlor procedural concept as promising for further improving the results of inguinal hernia repair. Obviously, a clinical trial with a larger patient cohort is needed to further validate the results of this innovative treatment strategy. Based on these premises, a clinical study is already ongoing, hoping to be able to share outcomes with the surgical community as soon as possible.

### Funding

No grants or other kind of financial support has been received for realizing the article.

### Ethical approval

Being a retrospective study, the investigation is exempted from approval by Ethics Committee.

### Consent

Written informed consent was obtained from the patients for publication of this case report and any accompanying images. A copy of the written consent is available for review by the Editor-in-Chief of this journal.

### Author contribution

Giuseppe Amato: made substantial contributions to study conception and design as well as interpretation of data.

Giorgio Romano: made substantial contributions to acquisition and analysis of data.

Piergiorgio Calò: made substantial contributions to analysis and interpretation of data.

Giuseppe Di Buono: has been involved in drafting the manuscript and revising it critically for important intellectual content.

Antonino Agrusa: made substantial contributions to interpretation of data and gave the final approval of the version to be published.

### Registration of research studies

1. Name of the registry: Research Registry
2. Unique identifying number or registration ID: researchregistry5827
3. Hyperlink to your specific registration (must be publicly accessible and will be checked): <https://www.researchregistry.com/browse-theregistry#home/registrationdetails/5f15aef7ba97eb0015e988d7/>

### Guarantor

Giuseppe Amato.

### Availability of data and materials

The datasets used and/or analysed during the current study are available from the corresponding author upon request.

### Declaration of Competing Interest

Giuseppe Amato is the developer of the prosthesis and the surgical technique being described. The remaining authors have no conflicts of interests.

## Acknowledgements

This article is part of a supplement entitled Case reports from Italian young surgeons, published with support from the Department of Surgical, Oncological and Oral Sciences - University of Palermo.

## References

- [1] M.P. Simons, T. Aufenacker, M. Bay-Nielsen, J.L. Bouillot, G. Campanelli, J. Conze, D. de Lange, R. Fortelny, T. Heikkinen, A. Kingsnorth, J. Kukleta, S. Morales-Conde, P. Nordin, V. Schumpelick, S. Smedberg, M. Smietanski, G. Weber, M. Miserez, European Hernia Society guidelines on the treatment of inguinal hernia in adult patients, *Hernia* 13 (August (4)) (2009) 343–403.
- [2] R. Bittner, J. Bingener-Casey, U. Dietz, et al., Guidelines for laparoscopic treatment of ventral and incisional abdominal wall hernias. International Endohernia Society (IEHS), *Surg. Endosc.* 28 (2014) 2–29.
- [3] HerniaSurge Group: international guidelines for groin hernia management, *Hernia* 22 (2018) 1–165.
- [4] P.K. Amid, Causes, prevention, and surgical treatment of postherniorrhaphy neuropathic inguinodynia: triple neurectomy with proximal end implantation, *Hernia* 8 (2004) 343–349.
- [5] P.J. O'Dwyer, A.N. Kingsnorth, R.G. Mohillo, P.K. Small, B. Lammers, G. Horeysee, Randomized clinical trial assessing impact of a lightweight or heavyweight on chronic pain after inguinal hernia repair, *Br. J. Surg.* 92 (2005) 166–170.
- [6] E. Aasvang, H. Kehlet, Surgical management of chronic pain after inguinal hernia repair, *Br. J. Surg.* 92 (2005) 795–801.
- [7] C.G. Schmedt, S. Sauerland, R. Bittner, Comparison of endoscopic procedure vs Lichtenstein and other open mesh techniques for inguinal hernia repair: a meta-analysis of randomized controlled trials, *Surg. Endosc.* 19 (2005) 188–189.
- [8] G. Amato, A. Agrusa, G. Romano, G. Cocorullo, G. Di Buono, S. Mularo, G. Gulotta, Modified fixation free plug technique using a new 3D multilamellar implant for inguinal hernia repair: a retrospective study of a single operator case series, *Hernia* 18 (April (2)) (2014) 243–250, <http://dx.doi.org/10.1007/s10029-013-1102-y>, Epub 2013 May 8.
- [9] G. Amato, A. Agrusa, G. Romano, Fixation-free inguinal hernia repair using a dynamic self-retaining implant, *Surg. Technol. Int.* 30 (2012), XXII:22/17.
- [10] G. Amato, G. Romano, A. Agrusa, G. Cocorullo, G. Gulotta, T. Goetze, Dynamic inguinal hernia repair with a 3d fixation-free and motion-compliant implant: a clinical study, *Surg. Technol. Int.* 24 (2014) 155–165.
- [11] G. Amato, A.I. Lo Monte, Cassata, G. Damiano, G. Romano, R. Bussani, A new prosthetic implant for inguinal hernia repair: its features in a porcine experimental model, *Artif. Organs* 35 (8) (2011) E181–E190.
- [12] G. Amato, G. Romano, A. Agrusa, S. Marasa, G. Cocorullo, G. Gulotta, T. Goetze, R. Puleio, Biologic response of inguinal hernia prosthetics: a comparative study of conventional static meshes versus 3D dynamic implants, *Artif. Organs* 39 (January (1)) (2015).
- [13] G. Amato, G. Romano, R. Puleio, A. Agrusa, T. Goetze, E. Gulotta, L. Gordini, E. Erdas, P. Calò, Neomyogenesis in 3D dynamic responsive prosthesis for inguinal hernia repair, *Artif. Organs* 42 (December (12)) (2018) 1216–1223.
- [14] G. Amato, A. Agrusa, R. Puleio, P.G. Calò, T. Goetze, G. Romano, Neo-nervegenesis in 3D dynamic responsive implant for inguinal hernia repair. Qualitative study, *Int. J. Surg.* 76 (April) (2020) 114–119.
- [15] G. Amato, G. Romano, T. Goetze, L. Cicero, E. Gulotta, P.G. Calò, A. Agrusa, Fixation free inguinal hernia repair with the 3D dynamic responsive prosthesis ProFlor: features, procedural steps and long-term results, *Int. J. Surg. Open* 21 (2019) 34–43.
- [16] R.A. Agha, M.R. Borrelli, R. Farwana, K. Koshy, A. Fowler, D.P. Orgill, For the SCARE Group, The SCARE 2018 statement: updating consensus Surgical Case Report (SCARE) guidelines, *Int. J. Surg.* 60 (2018) 132–136.
- [17] N. Shah, C. Fullwood, A.K. Siriwardena, et al., Mesh fixation at laparoscopic inguinal hernia repair: a meta-analysis comparing tissue glue and tack fixation, *World J. Surg.* 38 (2014) 2558–2570.
- [18] E. Reynvoet, F. Berrevoet, Pros and cons of tacking in laparoscopic hernia repair, *Surg. Technol. Int.* 25 (2014) 136–140.
- [19] P.K. Amid, Shrinkage: fake or fact? in: V. Schumpelick, L.M. Nyhus (Eds.), *Meshes: Benefits and Risks*, Springer, Berlin, 2004, pp. 198–204.
- [20] G. Amato, E. Ober, G. Romano, G. Salamone, A. Agrusa, G. Gulotta, R. Bussani, Nerve degeneration in inguinal hernia specimens *Hernia* 15 (2011) 53–58.
- [21] G. Amato, G. Romano, G. Salamone, A. Agrusa, V.A. Saladino, F. Silvestri, R. Bussani, Damage to the vascular structures in inguinal hernia specimens, *Hernia* 16 (2012) 63–67.
- [22] G. Amato, A. Agrusa, G. Romano, G. Salamone, G. Gulotta, F. Silvestri, R. Bussani, Muscle degeneration in inguinal hernia specimens, *Hernia* 16 (3) (2012) 327–331.
- [23] G. Amato, A. Agrusa, G. Romano, G. Salamone, G. Cocorullo, S.A. Mularo, S. Marasa, G. Gulotta, Histological findings in direct inguinal hernia, *Hernia* 17 (6) (2013) 757–763.
- [24] G. Amato, A. Agrusa, V. Rodolico, R. Puleio, G. Di Buono, S. Amodeo, E. Gulotta, G. Romano, Combined inguinal hernia in the elderly. Portraying the progression of hernia disease, *Int. J. Surg.* 1 (Suppl) (2016) S20–S29.
- [25] G. Amato, P. Calò, V. Rodolico, R. Puleio, A. Agrusa, L. Gulotta, L. Gordini, G. Romano, The septum inguinalis: a clue to hernia genesis? *J. Invest. Surg.* (October) (2018) 1–9.
- [26] G. Amato, A. Agrusa, V. Rodolico, P.G. Calò, R. Puleio, G. Romano, Inguinal hernia: the destiny of the inferior epigastric vessels and the pathogenesis of the disease, *Surg. Technol. Int.* 36 (March) (2020), pii: sti36/1274. [Epub ahead of print].

## Open Access

This article is published Open Access at [sciencedirect.com](https://www.sciencedirect.com). It is distributed under the [IJSCR Supplemental terms and conditions](#), which permits unrestricted non commercial use, distribution, and reproduction in any medium, provided the original authors and source are credited.