



## Stimulating the deprived motor ‘hand’ area causes facial muscle responses in one-handers



**Keywords:**  
Plasticity  
Single-pulse TMS  
Motor cortex  
One-handers  
Face

### Introduction

How the brain adapts to the absence of sensory inputs and motor outputs from early development is a key question in neuroscience. While sensory deprivation has long been known to trigger changes to cortical maps in sensory and motor cortex, e.g. due to blindness [1], deafness [2] or arm malformation [3], there is an ongoing debate on their functional relevance. For example, using fMRI, we have previously reported that the deprived sensorimotor hand territory of individuals born without a hand shows increased activity evoked by movements of the lips, feet and residual arm, when compared to two-handed controls [4,5]. This is consistent with the idea that the missing-hand area may be recruited to support increased representation of alternative intact body parts. However, changes to cortical map boundaries (i.e., remapping), as measured through fMRI, do not necessarily entail changed representational content and readout [3]. As such, the observed remapping may not subservise a functional role. By allowing to directly stimulate the motor cortex and measure the evoked muscular responses in various body parts, TMS provides a unique opportunity to causally assess the functional consequences of motor remapping.

Few previous studies have used this technique to investigate the functional content of the missing-hand area of individuals with congenital limb deficiencies. In people born without both hands and with exceptional foot dexterity, TMS over the missing-hand area elicited MEPs in the feet and interfered with foot movements [6,7]. In congenital one-handers, studies have focused on the residual arm [8–10], with mixed evidence: two studies reported an expansion of the residual arm representation [8,9], but this has not been replicated [10]. Here, we used single-pulse TMS to investigate the functional relevance of the previously observed remapping of the lips in the missing-hand motor cortex of one-handers [4,5]. We hypothesised that functional reorganisation should result in facial MEPs when the missing-hand area is activated.

### Methods

To this end, we stimulated the missing-hand region in 10 congenital one-handers (OH) and the non-dominant hand area in 10 two-handed controls (CT), and measured EMG activity from the muscle surrounding the mouth (orbicularis oris). The missing-hand region was defined by first locating the motor hotspot of the intact first dorsal interosseous muscle and then flipping the coordinates onto the other hemisphere using a neuronavigation software (BrainSight, Rogue Research). The stimulation intensity was set to 150% of the resting motor threshold (rMT) of the intact-hand hotspot. We administered 30 pulses with muscles at rest and 15 pulses during slight lip contraction (for details, see ‘Supplementary Methods’; or <https://osf.io/6n7s8/> to full study protocol and EMG data).

Peak-to-peak amplitudes and MEP response latencies were examined for all trials showing an MEP. The proportion of individuals showing face MEPs across groups was compared using Fisher’s Exact Test. Whenever possible, we also stimulated the face hotspot ipsilateral to the missing hand with an intensity of 120% rMT and compared the face MEP latencies of the two stimulation locations (missing-hand vs. face hotspot) with Welch’s t-tests. When non-significant differences were found, we calculated the Bayes factor (Cauchy prior width = 0.707) to obtain the likelihood of observing our data under the null hypothesis.

During stimulation, we additionally recorded EMG from a prominent residual arm muscle in one-handers, or the non-dominant forearm extensor in controls. The arm recordings were used to confirm that we were stimulating close to the (missing) hand region. We compared the MEP arm latency of ‘face-responders’ (participants that showed face MEPs during missing-hand stimulation) to controls using two-tailed Bayesian tests for single case assessment [11]; see Fig. S1 for group comparisons. One one-hander (OH4) had a transhumeral arrest, making the comparison to controls’ forearm muscles inadequate. As a substitute, an image of the participant’s MRI scan overlaid with the stimulation coordinates was used to confirm the stimulation location (Fig. S2).

### Results

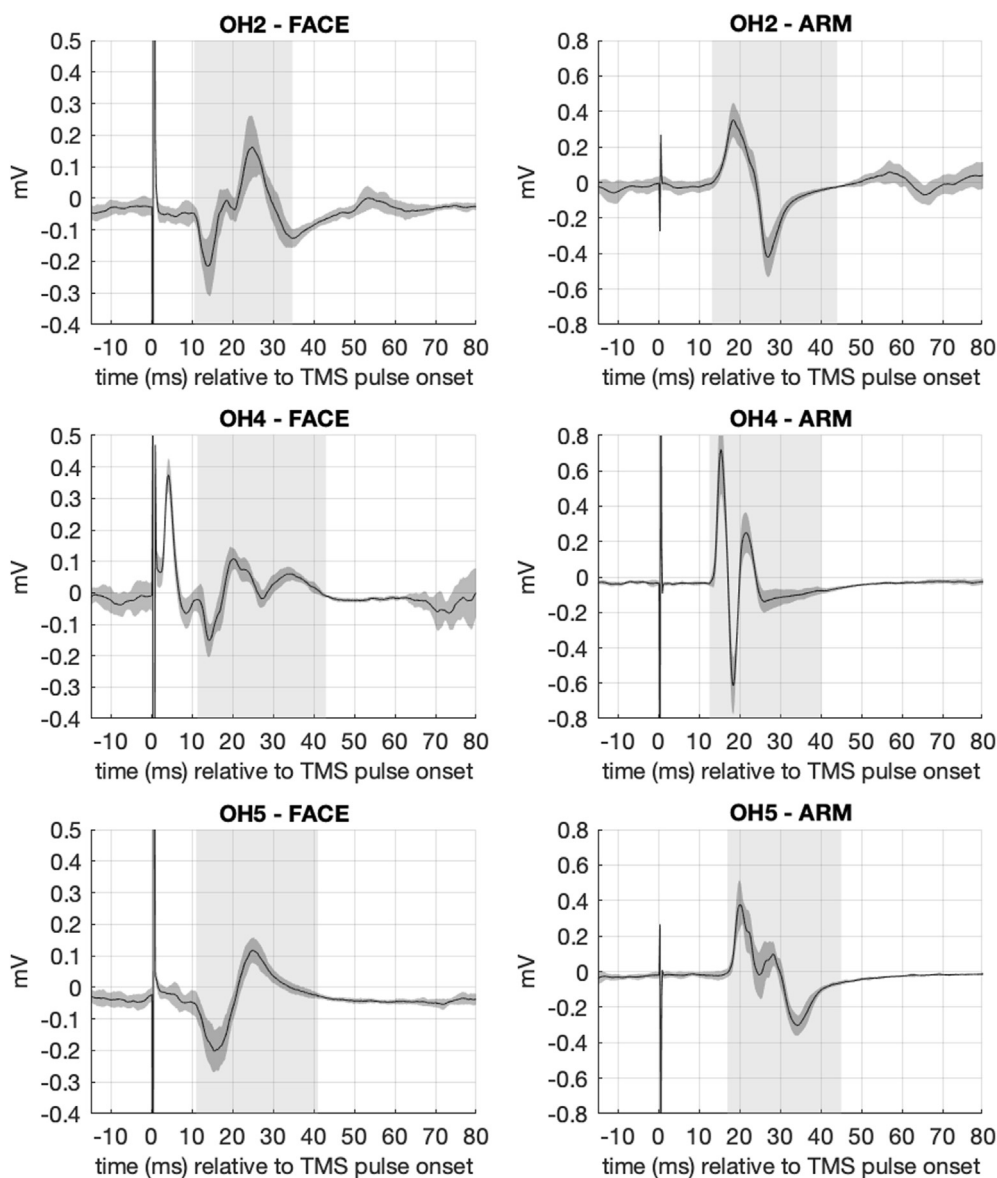
We observed clear arm MEPs in 6 out of 10 one-handers and in all controls. Of these 6 one-handers, 3 showed face MEPs during lip contraction trials (Fig. 1) while, importantly, no face MEPs were found in controls (Fig. S3). Average MEP amplitude and latencies were as follows: OH2 (87% MEP-trials): 0.47 mV ( $SD = 0.13$  mV) and 11.5 ms ( $SD = 0.4$  ms); OH4 (93% MEP-trials): 0.29 mV

( $SD = 0.07$  mV) and 12.5 ms ( $SD = 1.0$  ms); OH5 (93% MEP-trials): 0.36 mV ( $SD = 0.10$  mV) and 12.2 ms ( $SD = 0.9$  ms). The remaining one-handers showed either a strong decay artefact in the facial EMG or did not show face MEPs (Fig. S3). A Fisher's Exact Test confirmed that face MEPs are more common in one-handers than controls ( $p = 0.036$ ). During rest trials, no clear face MEPs were observed (Fig. S4).

Additionally, we stimulated the face hotspot in two of the three face-responders. Average MEP amplitudes and latencies were as follows: OH4 (100% MEP-trials): 0.57 mV ( $SD = 0.13$  mV) and 11.2 ms ( $SD = 1.5$  ms); OH5 (74% MEP-trials): 0.20 mV ( $SD = 0.07$  mV) and 12.5 ms ( $SD = 0.3$  ms). In OH4, face MEPs from the face hotspot had shorter latencies compared to the face MEPs from the missing-hand hotspot ( $W(24.61) = 2.9, p < 0.01$ ). OH5 showed no significant differences in latencies across the two stimulation locations ( $W(15.68) = -1.17, p = 0.26, BF(01) = 1.7$ ). Importantly, in

both cases the shape of the MEPs looks similar for the two stimulation locations (Fig. S5) suggesting that the observed facial EMG-signal during missing-hand stimulation are indeed MEPs. No arm MEPs were observed during face-hotspot stimulation.

All face-responders (OH2, OH4, OH5) exhibited arm MEPs during missing-hand stimulation (Fig. 1). The Bayesian test for single case assessment revealed no differences in arm MEP latencies between OH5 ( $M = 17.6$  ms,  $SD = 0.5$  ms) and controls ( $Z = 0.41, p = 0.7$ ), with an estimated 65% of the control population falling below OH5's value, and between OH2 ( $M = 14.8$  ms,  $SD = 1.4$  ms) and controls ( $Z = -1.97, p = 0.09$ ), with an estimated 2.5% of the control population falling below OH2's value. These findings provide indirect evidence that it is unlikely that we stimulated closer to the face region in the face-responders compared to controls ( $M = 17.1$  ms,  $SE = 0.4$  ms; Fig. S1), for OH4 see Fig. S2.



**Fig. 1.** Average EMG from the orbicularis oris (left) and residual arm muscle of face-responders for all lip contraction trials during missing-hand stimulation (solid line: mean value; shaded area:  $\pm$  one standard deviation). The mean MEP-window is highlighted in light grey. For OH4, the spike at around 5 ms reflects a peripherally evoked compound muscle action potential (CMAP).

## Discussion

Here, we show that muscle responses in the lower face can be evoked in a subgroup of congenital one-handers by applying single-pulse TMS over the missing-hand motor area. The normative values and shape of these observed MEPs are in line with previous research directly stimulating the face area [12]. The fact that MEP latencies evoked from the missing-hand and face sites are not conclusively similar in our sample, with OH4 reporting increased latencies from the missing-hand site, suggests that a mono-synaptic corticospinal projection from the missing-hand area is likely unsuited to explain our findings [13]. Rather, although our data contain no direct evidence, it appears more plausible that the observed MEPs are generated through cortico-cortical projections through horizontal connections from the missing-hand to the face site [14].

By showing that the missing-hand motor area can engage in motor control of the lower face muscles, we provide direct evidence for functionally relevant sensorimotor reorganisation in congenital one-handers. We suggest that, in absence of the typical peripheral input/output sensorimotor dynamics during development, the sensorimotor missing-hand area becomes responsive to face inputs, otherwise normally inhibited. This hypothesis is supported by the findings of increased global connectivity and decreased GABA in the missing-hand area, indicating decreased inhibition in one-handers [4]. Our present results suggest that such release from inhibition has functional consequences.

Interestingly, we only detected facial motor responses in a subset of one-handed participants. This could be due to methodological reasons (see Supplementary Methods), but it could also indicate that the patterns of functional reorganisation differ across one-handed individuals. It was suggested that patterns of remapping in the deprived hand area may be dictated by the relative compensatory use of alternative body parts during development, due to mechanisms of Hebbian-like plasticity [4]. Under this framework, only individuals who have used their mouth more frequently to compensate for the missing-hand functions would show functional reorganisation of the face. However, since one-handers predominantly rely on their residual arm for compensatory behaviours, this framework would have predicted shorter arm MEP latencies, which was not consistently observed here (Fig. S1). Nevertheless, our unique dataset provides a rare opportunity to demonstrate that deprivation-triggered plasticity, which results in new functional outcomes, is possible in the human brain even in absence of exceptional training [as in 6,7]. Further research using longitudinal approaches is needed to better understand the role of motor experience in shaping brain reorganisation as it unfolds across development.

## Declaration of competing interest

The authors confirm that there are no known conflicts of interest associated with this publication and there has been no financial support for this work that could have influenced its outcome.

## Acknowledgements

This work was supported by a Wellcome Trust Senior Research Fellowship (215575/Z/19/Z), awarded to TRM. For the purpose of Open Access, the author has applied a CC BY public copyright licence to any Author Accepted Manuscript (AAM) version arising from this submission. We thank our participants and Opcare for their invaluable help.

## Appendix A. Supplementary data

Supplementary data to this article can be found online at <https://doi.org/10.1016/j.brs.2021.01.022>.

## References

- [1] Singh AK, Phillips F, Merabet LB, Sinha P. Why does the cortex reorganize after sensory loss? *Trends Cognit Sci* 2018;22:569–82. <https://doi.org/10.1016/j.tics.2018.04.004>.
- [2] Land R, Baumhoff P, Tillein J, Lomber SG, Hubka P, Kral A. Cross-modal plasticity in higher-order auditory cortex of congenitally deaf cats does not limit auditory responsiveness to cochlear implants. *J Neurosci* 2016;36:6175–85. <https://doi.org/10.1523/JNEUROSCI.0046-16.2016>.
- [3] Muret D, Makin TR. The homeostatic homunculus: rethinking deprivation-triggered reorganisation. *Curr Opin Neurobiol* 2021;67:115–22. <https://doi.org/10.1016/j.conb.2020.08.008>.
- [4] Hahamy A, Macdonald SN, van den Heiligenberg F, Kieliba P, Emir U, Malach R, et al. Representation of multiple body parts in the missing-hand territory of congenital one-handers. *Curr Biol* 2017;27:1350–5. <https://doi.org/10.1016/j.cub.2017.03.053>.
- [5] Hahamy A, Makin TR. Remapping in cerebral and cerebellar cortices is not restricted by somatotopy. *J Neurosci* 2019;39:9328–42. <https://doi.org/10.1523/JNEUROSCI.2599-18.2019>.
- [6] Stoessel MC, Seitz RJ, Buettelisch CM. Congenitally altered motor experience alters somatotopic organization of human primary motor cortex. *Proc Natl Acad Sci Unit States Am* 2009;106(7):2395–400. <https://doi.org/10.1073/pnas.0803733106>.
- [7] Nakagawa K, Takemi M, Nakanishi T, Sasaki A, Nakazawa K. Cortical reorganization of lower-limb motor representations in an elite archery athlete with congenital amputation of both arms. *Neuroimage: Clinical* 2020;25:102144. <https://doi.org/10.1016/j.nicl.2019.102144>.
- [8] Cohen LG, Bandinelli S, Findley TW, Hallett M. Motor reorganization after upper limb amputation IN man. *Brain* 1991;114:615–27. <https://doi.org/10.1093/brain/114.1.615>.
- [9] Hall EJ, Flament D, Fraser C, Lemon RN. Non-invasive brain stimulation reveals reorganised cortical outputs in amputees. 1990.
- [10] Reilly KT, Sirigu A. Motor cortex representation of the upper-limb in individuals born without a hand. *PLoS One* 2011;6(4):e18100. <https://doi.org/10.1371/journal.pone.0018100>.
- [11] Crawford JR, Garthwaite PH. Comparison of a single case to a control or normative sample in neuropsychology: development of a Bayesian approach. *Cogn Neuropsychol* 2007;24:343–72. <https://doi.org/10.1080/02643290701290146>.
- [12] Adank P, Kennedy-Higgins D, Maegherman G, Hannah R, Nuttall HE. Effects of coil orientation on motor evoked potentials from orbicularis oris. *Front Neurosci* 2018;12. <https://doi.org/10.3389/fnins.2018.00683>.
- [13] Fuhr P, Cohen LG, Roth BJ, Hallett M. Latency of motor evoked potentials to focal transcranial stimulation varies as a function of scalp positions stimulated. *Electroencephalogr Clin Neurophysiol Evoked Potentials* 1991;81:81–9. [https://doi.org/10.1016/0168-5597\(91\)90001-E](https://doi.org/10.1016/0168-5597(91)90001-E).
- [14] Fang PC, Jain N, Kaas JH. Few intrinsic connections cross the hand-face border of area 3b of New World monkeys. *Journal of Comparative Neurology* 2002;454(3):310–9. <https://doi.org/10.1002/cne.10433>.

Elena Amoruso<sup>1</sup>

*Institute of Cognitive Neuroscience, University College London, London, United Kingdom*

Maria Kromm<sup>1,\*</sup>

*Institute of Cognitive Neuroscience, University College London, London, United Kingdom*

Danny Spampinato

*Department of Clinical and Movement Neurosciences, UCL Queen Square Institute of Neurology, University College London, London, United Kingdom*

Benjamin Kop

*Institute of Cognitive Neuroscience, University College London, London, United Kingdom*

Dollyane Muret

*Institute of Cognitive Neuroscience, University College London, London, United Kingdom*

John Rothwell  
*Department of Clinical and Movement Neurosciences, UCL Queen  
Square Institute of Neurology, University College London, London,  
United Kingdom*

Lorenzo Rocchi<sup>2</sup>  
*Department of Clinical and Movement Neurosciences, UCL Queen  
Square Institute of Neurology, University College London, London,  
United Kingdom*

Tamar R. Makin<sup>2</sup>  
*Institute of Cognitive Neuroscience, University College London,  
London, United Kingdom*

\* Corresponding author.  
E-mail address: [m.kromm@ucl.ac.uk](mailto:m.kromm@ucl.ac.uk) (M. Kromm).

28 January 2021  
Available online 5 February 2021

---

<sup>1</sup> Authors contributed equally.

<sup>2</sup> Authors contributed equally

## Supplementary Methods

### *Participants.*

We tested 12 congenital one-handers and 14 two-handed control participants. All participants had no prior history of neurological or psychiatric disorders and passed screening for contraindications to TMS [1]. Three control participants (CT2, CT8, CT9) and one congenital one-hander (OH8) had to be excluded from analysis due to technical issues in calibration of the participant's head shape to the neuro-navigation template. This affected the flipping procedure (see 'Definition of the main stimulation area' below), resulting in a defined stimulation location that was far off from the visually estimated hand motor region [2]. Two participants (OH7, CT11) were not included in the current analysis as they had a high resting motor threshold (rMT) and they could not tolerate a stimulation at 150%rMT. We therefore included 10 one-handed participants (mean age: 41.9 years (SD = 12.9); 7 females; 4 left-handed) and 10 control participants (mean age: 35 years (SD = 11.5); 6 females; 3 left-handed) in our main analysis (for demographics, see Table S6). Participants gave their written informed consent prior to the experimental session and received financial compensation for travel and participation. The study was approved to be in accordance with the Declaration of Helsinki by the NHS Research Ethics Committee (Project ID Number: 18/LO/0474).

### *Data acquisition and apparatus.*

#### ***Physiological measurements***

For all participants, electromyography (EMG) was recorded from the lower face (orbicularis oris), ipsilateral to the missing/non-dominant hand and from the first dorsal interosseous (FDI) of the intact/dominant hand, in one-handers and controls respectively. For one-handers, we selected a prominent stump muscle that was as distal as possible but still well controllable by the participant. In control participants, we recorded from the wrist extensor muscles on the non-dominant side. Additionally, we recorded from the non-dominant FDI in controls to validate the

estimated hand stimulation area. We also recorded from a leg muscle (tibialis anterior), as previous studies on people born without both hands showed MEPs in the feet during missing-hand stimulation [3,4] but we did not observe any leg MEPs during missing-hand stimulation.

Self-adhesive electrodes were arranged in a belly-tendon montage. For the orbicularis oris recording, we placed the active electrode on the upper lip, close to the vermillion border, and the reference on the zygomatic bone. A ground electrode was set on the dorsum of the intact/dominant hand. The EMG signals were amplified and band-pass filtered between 20 Hz and 2000 Hz (Digitimer D360, 2015 Digitimer Ltd, United Kingdom) and acquired at a 5000 Hz sampling rate with a data acquisition board (CED-1402, Cambridge Electronic Design Ltd 2016) connected to a PC and controlled with the Signal software (also by CED). The data were stored for offline analysis using the Signal software.

### ***Transcranial magnetic stimulation***

A Magstim 200 stimulator (Magstim, Whitland, United Kingdom) and a figure-of-eight, 70-mm-diameter TMS coil were used for the stimulation. We adjusted the position and orientation of the coil and the intensity of the single pulses for each participant individually. To determine and monitor the correct coil placement, a neuro-navigation system (BrainSight, Rogue Research) was used. Since not all of our participants were fMRI-safe and we could not obtain their brain scans, we calibrated the participants' head shape in the neuro-navigation system and fitted an MNI template. In case of a congenital transhumeral arrest, we used the individual's anatomical scan instead of an MNI template.

*Procedure.*

### ***Definition of the main stimulation area***

The participants sat in a comfortable chair with both forearms resting on a pillow placed on their

lap. Once the electrodes were set, the TMS coil was moved in small steps over the estimated site of the cortical motor area of the intact or dominant hand (in one handers and controls, respectively) in order to find the location on the scalp that consistently yielded the largest MEP amplitudes in the FDI contralateral to the stimulation side (i.e., intact/dominant hand hotspot). This hotspot was saved as a target in the neuro-navigation system. Next, we determined the resting motor threshold (rMT) of the saved hand hotspot. The rMT was defined as the minimal stimulation intensity that produced MEP peak-to-peak amplitudes larger than 0.05 mV in 50% of stimulation trials [5]. This threshold was used as a reference to determine the stimulation intensities. In order to define the cortical missing-hand area, we mirrored the hotspot of the intact hemisphere onto the deprived hemisphere by means of the neuro-navigation system. The same procedure was also applied to the control group, where we mirrored the hotspot of the dominant hand onto the nondominant hemisphere to define the cortical non-dominant hand area (corresponding to the missing-hand area in one-handers). The tilt of the coil had to be adjusted in some cases to ensure good contact of the coil with the participants' head, due to the asymmetry of their head shape. We based this procedure on the known symmetry of the M1 somatotopy across both hemispheres [6,7]. Furthermore, we validated this procedure by observing MEPs in the non-dominant hand of controls during stimulation of the estimated non-dominant hand region. The defined missing-hand territory was stimulated at intensities of 120% and 150% of the individual's rMT of the intact/dominant hand. The two intensities were chosen to ensure a sufficiently sensitive stimulation, as the threshold of the missing-hand hemisphere in congenital one-handers is shown to be higher than for the intact side [8].

### ***Stimulation at rest***

To map the cortical muscle representation in the deprived hand area, single-pulse TMS was applied to the defined missing-hand area while the participant was instructed to stay as relaxed

as possible. We administered 30 consecutive pulses with a stimulation intensity of 120%rMT, followed by 30 pulses with an intensity of 150%rMT, with an inter-trial interval of  $4\pm 10\%$  s.

### ***Stimulation during contraction***

Following the measurements at rest, the participant was asked to slightly contract the muscles during the stimulation. The contraction of a muscle recruits the respective cortical neurons that are functionally linked to that muscle, which makes these neurons more sensitive to the magnetic stimulation [5]. Thus, the contraction helps to attain a more functional picture of the missing-hand M1 representations.

This part consisted of two blocks - lip contraction and arm contraction. Each block consisted of 30 trials in total (15 trials at 120%rMT; 15 trials at 150%rMT), with an intertrial interval of  $4\pm 10\%$  s. However, since we could not identify consistent responses at 120%rMT, we only report results from the stimulation intensity of 150%rMT. The order of the body part contraction blocks was predefined and counterbalanced across participants. To ensure consistent force production, the participants were provided with the online EMG signal for visual feedback. Two horizontal cursors were set around 10% of the individual maximal contraction force in the EMG signal to facilitate the monitoring.

### ***Mouth hotspot***

For some participants, the mouth hotspot of the deprived (non-dominant) hemisphere was determined and stimulated as well. This was done by moving the coil more anteriorly and laterally. The spot that elicited the highest MEPs in the mouth muscles was sampled and the rMT was determined. We administered 20 pulses to this area with a stimulation intensity of 120%rMT. Note that this procedure requires high stimulation intensities as the threshold for the



mouth is usually much higher than for the hand. Many participants could not tolerate this stimulation; hence, we could only acquire partial data.

#### *Data analysis.*

Data analysis was performed with custom-made scripts in MATLAB (R2017a, Mathworks), SPSS (Version 25, IBM), and RStudio (R Core Team, 2020).

#### ***MEP detection***

The peak-to-peak MEP amplitude was determined by finding the global minimum and the global maximum of the EMG signal within a predefined temporal window. We selected the first occurring peak and then chose the temporally nearest peak. To avoid false positive registrations, the temporal window to search for peaks was adjusted for each body part, based on the time period in which an MEP is most likely to occur. The following time windows were used: hand = [15 - 40ms]; arm = [12 - 40ms]; mouth = [7 - 20ms] [5,10,11]. A time window of 150ms before the TMS pulse was used to compute the average and the standard deviation of the baseline noise level. Signals below a threshold of mean  $\pm$  4 standard deviations of the noise level were discarded as being indistinguishable from the baseline. A previous study suggested to use a threshold of three standard deviations around the average noise level [12]; however, given the noisy nature of our data, it was not conservative enough, resulting in a disproportionate number of false positives. Furthermore, MEP amplitudes lower than 0.05 mV were discarded as being indistinguishable from baseline as per general practice [5]. As an additional precaution, the single trial wave-plots of the signal for each subject were visually inspected. The latencies of the MEP onset were determined visually on a trial-by-trial basis. The experimenter performing the visual detection was blinded with respect to the participant group.

Some of our participants showed artefacts in the face signal data. During offline analysis, we determined whether signal displayed evidence of peripherally evoked compound muscle action potential (CMAP) or decay electrical artefacts. The CMAPs arise due to direct stimulation of the peripheral facial nerve fibres situated close to the targeted cortical area [13]. For most of our participants who showed CMAPs in the face EMG recording, the CMAPs ended around 8ms after the pulse onset. Thus, they were not likely to confound potential MEPs. In contrast, the decay artefact results from the voltage induced in the electrodes directly by the TMS pulse, which was of much larger magnitude than the physiological responses and could contaminate potential face MEPs, which complicates their detection. In order to detect eventual MEPs masked by the decay artefact, we fit a 2nd order polynomial function to the signal (which closely resembles the shape of the artefact) and computed the residuals between the fit and the signal. For some participants, the artefact was so strong that the fitting did not result in substantial improvement of the signal legibility. This was the case for three one-handers and one control during missing-hand stimulation at rest (Figure S4), and for the same control during missing-hand stimulation over the lip-contraction trials (Figure S3). Recollection of this data was originally planned, but then halted due to Covid-19 bans on human testing.

## References

- [1] Rossi S, Hallett M, Rossini PM. Screening questionnaire before TMS: An update. *Clin Neurophysiol* 2011;120:1686. <https://doi.org/10.1016/j.clinph.2010.12.037>.
- [2] Yousry TA, Schmid UD, Alkadhi H, Schmidt D, Peraud A, Buettner A, et al. Localization of the motor hand area to a knob on the precentral gyrus. A new landmark. *Brain* 1997;120 ( Pt 1):141–57. <https://doi.org/10.1093/brain/120.1.141>.
- [3] Stoeckel MC, Seitz RJ, Buetefisch CM. Congenitally altered motor experience alters somatotopic organization of human primary motor cortex. *Proceedings of the National Academy of Sciences* 2009. <https://doi.org/10.1073/pnas.0803733106>.
- [4] Nakagawa K, Takemi M, Nakanishi T, Sasaki A, Nakazawa K. Cortical reorganization of lower-limb motor representations in an elite archery athlete with congenital amputation of both arms. *NeuroImage: Clinical* 2020;25:102144. <https://doi.org/10.1016/j.nicl.2019.102144>.
- [5] Rossini PM, Burke D, Chen R, Cohen LG, Daskalakis Z, Di Iorio R, et al. Non-invasive electrical and magnetic stimulation of the brain, spinal cord, roots and peripheral nerves: Basic principles and procedures for routine clinical and research application. *Clin Neurophysiol* 2015;126:1071–107. <https://doi.org/10.1016/j.clinph.2015.02.001>.
- [6] Civardi C, Cavalli A, Naldi P, Varrasi C, Cantello R. Hemispheric asymmetries of cortico-cortical connections in human hand motor areas. 2000.
- [7] Cicinelli P, Pasqualetti P, Zaccagnini M, Traversa R, Oliveri M, Rossini PM. Interhemispheric Asymmetries of Motor Cortex Excitability in the Postacute Stroke Stage A Paired-Pulse Transcranial Magnetic Stimulation Study 2003. <https://doi.org/10.1161/01.STR.0000092122.96722.72>.
- [8] Reilly KT, Sirigu A. Motor cortex representation of the upper-limb in individuals born without a hand. *PLoS One* 2011. <https://doi.org/10.1371/journal.pone.0018100>.
- [9] Cardellicchio P, Sinigaglia C, Costantini M. Grasping affordances with the other's hand: a TMS study. *Soc Cogn Affect Neurosci* 2013;8:455–9. <https://doi.org/10.1093/scan/nss017>.
- [10] W Roedel RM, Laskawi R, Markus H. Cortical Representation of the Orbicularis Oculi Muscle as Assessed by Transcranial Magnetic Stimulation (TMS). 2005.
- [11] Säisänen L, Julkunen P, Niskanen E, Danner N, Hukkanen T, Lohioja T, et al. Motor potentials evoked by navigated transcranial magnetic stimulation in healthy subjects. *J Clin Neurophysiol* 2008;25:367–72. <https://doi.org/10.1097/WNP.0b013e31818e7944>.
- [12] Hodges PW, Bui BH. A comparison of computer-based methods for the determination of onset of muscle contraction using electromyography. *Electroencephalogr Clin Neurophysiol* 1996;101:511–9. [https://doi.org/10.1016/s0013-4694\(96\)95190-5](https://doi.org/10.1016/s0013-4694(96)95190-5).
- [13] Dubach P, Guggisberg AG, Rösler KM, Hess CW, Mathis J. Significance of coil orientation for motor evoked potentials from nasalis muscle elicited by transcranial magnetic stimulation. *Clin Neurophysiol* 2004;115:862–70. <https://doi.org/10.1016/j.clinph.2003.11.033>.

## Supplementary Material

### S1 – Group Comparison of Arm MEP latencies

To account for the different group sample sizes ( $n(\text{OH})=5$ ,  $n(\text{CT})=10$ ), a Welch's t-test was run for comparing the arm MEP latencies across groups. Note that OH4 had a transhumeral arrest, making the comparison to the controls' forearm muscle inadequate, and was thus not included in the analysis. We did not observe significant differences between one-handers ( $M=16.23\text{ms}$ ,  $SE=0.64\text{ms}$ ) and controls ( $M=17.11\text{ms}$ ,  $SE=0.35\text{ms}$ ,  $W(6.23)=-1.09$ ,  $p=0.32$ ). However, the Bayes factor ( $BF(01)=1.39$ ) does not suggest sufficient evidence for the null hypothesis.

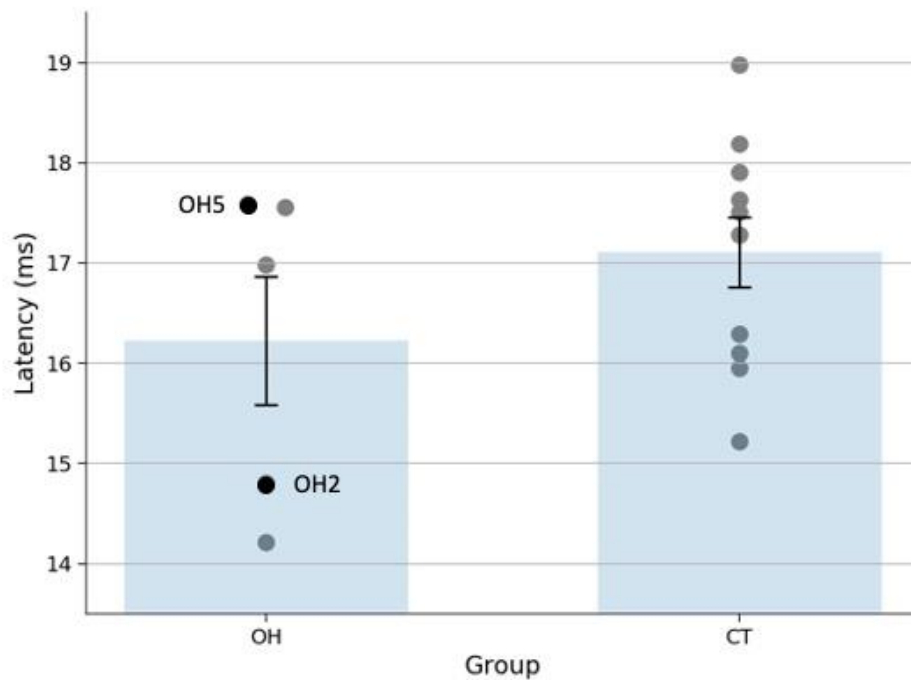
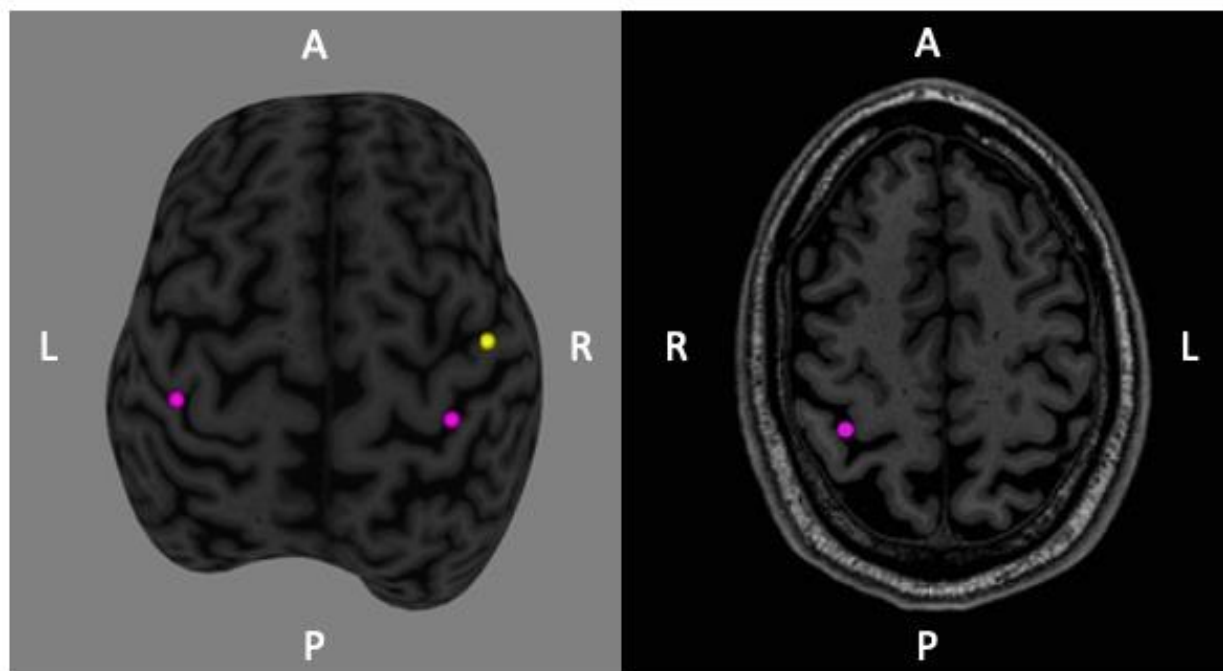


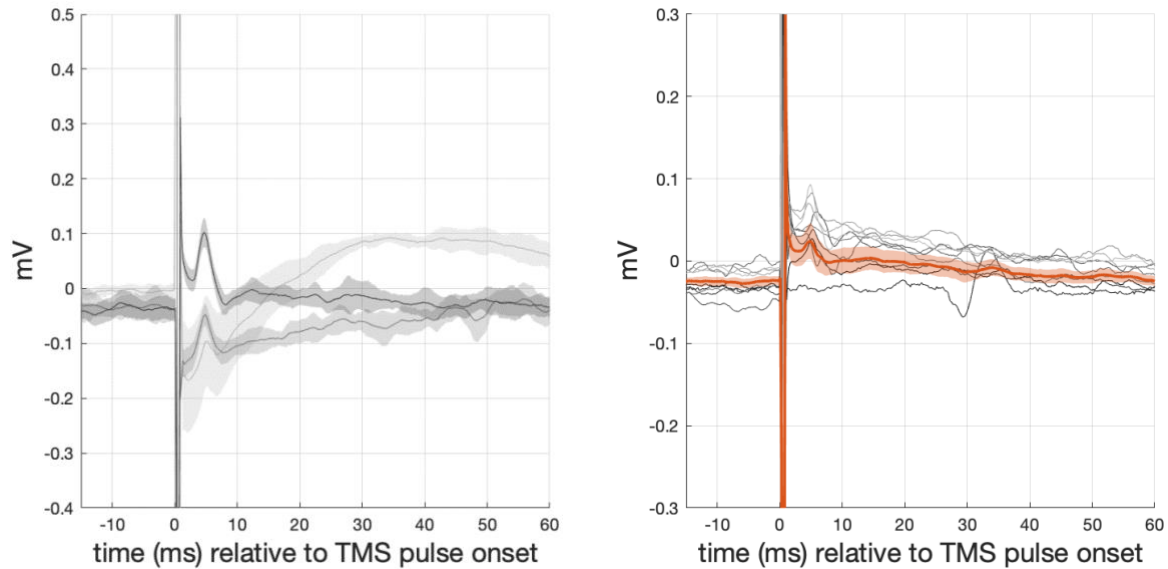
Figure S1. Mean and standard error of group arm MEP onset latency in milliseconds. The markers show the mean latency of each participant. The face responders are highlighted in black. OH = one handers; CT = two-handed controls.

## S2 – Visualisation of Stimulation Location for OH4



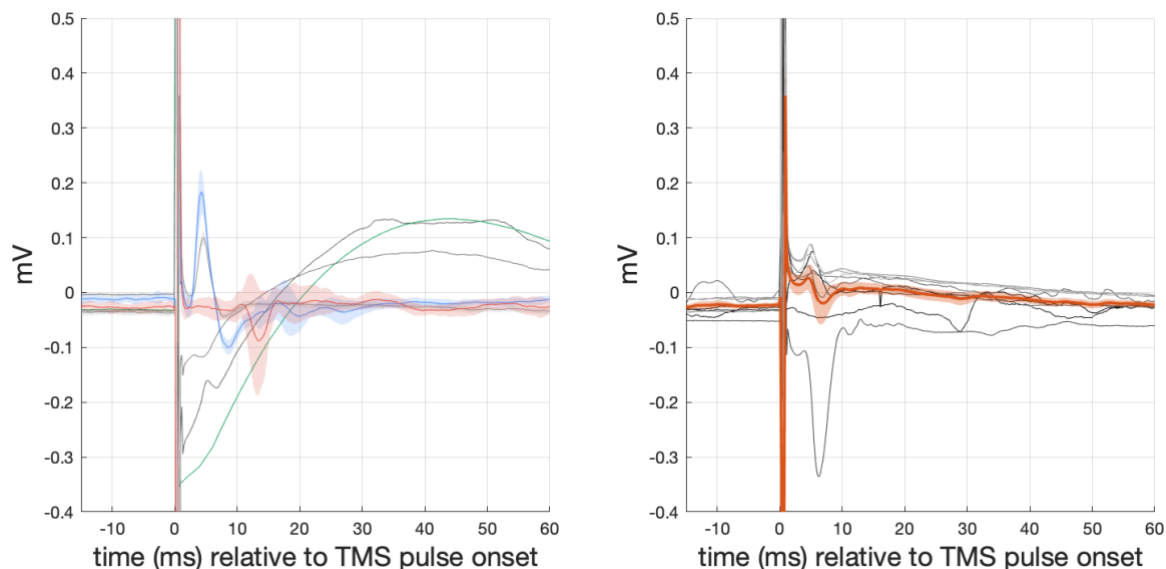
*Figure S2.* Participant's anatomical scan (left image: 3D-reconstructed, right image: axial slice) with markers representing the approximated stimulation location provided by the neuro-navigation software. The magenta-coloured marker on the right hemisphere shows the stimulated area during the missing-hand stimulation, the yellow marker shows the stimulated area during face hotspot stimulation. The marker on the left hemisphere shows the intact hand hotspot. Images were extracted from BrainSight, Rogue Research.

### S3 – Average Face EMG Signal during Lip Contraction



*Figure S3.* Average EMG waveform of contracted lower face muscle during (missing) hand stimulation. The left plot represents one-handers that showed arm MEPs but no face MEPs ( $n=3$ ), the light grey line shows the detrended signal of one participant. The right plot shows controls ( $n=9$ ). Each grey line represents a single participant. For controls, the average signal across all participants and the standard error are shown in orange, for each one-hander the standard deviation is shown. The small peaks right after the TMS pulse are CMAPs. One control's face recording is not plotted here because of a strong electrical decay that could not be detrended successfully (for further explanation, see Supplementary Methods).

### S4 – Average Face EMG Signal at Rest



*Figure S4.* Average EMG waveform of the relaxed face muscle during (missing) hand stimulation in 6 one-handers (left) and 9 controls (right). The face responders from the contraction condition are shown in colour (OH2 – red; OH4 – blue; OH5 – green), the other participants in grey. Three one-handers showed an electrical artefact (incl. OH5), here we show the detrended signal without standard deviation (for better legibility). OH2 (red) shows small potential face MEPs at around 11ms. For controls, the average signal across all participants and the standard error are shown in orange. The small peaks right after the TMS pulse (at around 5ms) are CMAPs. One control's face recording is not plotted here because of a strong electrical decay that could not be detrended successfully (for further explanation, see Supplementary Methods).

### S5 – Average EMG Signal during Face Area Stimulation

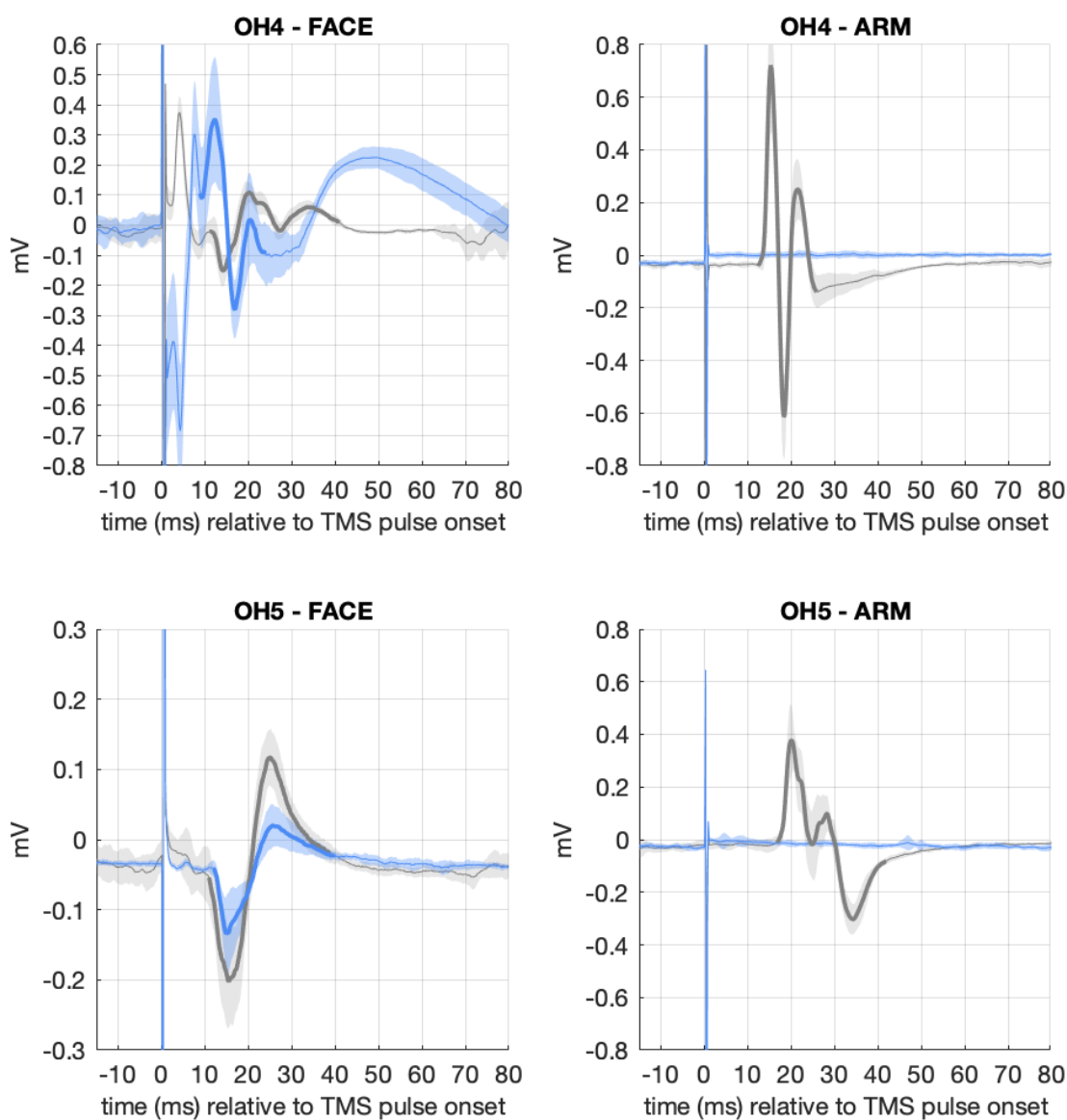


Figure S5. Average EMG waveform from the orbicularis oris for two face-responders. The blue line shows the EMG during face hotspot stimulation, the grey line represents the signal during missing-hand stimulation. The bold highlight shows the average MEP shape. Note that OH4's recording showed an electrical artefact during face hotspot stimulation, here we show the detrended signal.



## S6 – Participant Demographics

Participant	Sex	Age	Missing/ Nondominant	rMT	Amputation Level
<b>One-Handers</b>					
OH1	F	32	L	34	1
OH2	F	28	R	39	1
OH3	F	52	R	35	1
OH4	M	52	L	45*	0
OH5	M	35	L	40*	1
OH6	F	32	L	36	1
OH9	F	29	L	42	1
OH10	M	63	L	45	1
OH11	F	57	R	46	1
OH12	F	39	R	41	1
<b>Controls</b>					
CT1	M	22	R	40	
CT3	M	26	L	39	
CT4	F	22	L	32	
CT5	F	21	R	35	
CT6	F	45	L	58	
CT7	F	48	L	47	
CT10	M	45	L	39	
CT12	M	47	R	38	
CT13	F	42	L	33	
CT14	F	32	L	43	

*Note:* Sex: female (F) and male (M); Missing/Nondominant hand on left (L) or right (R) side; Amputation level either above elbow (0) or below elbow (1); rMT is the resting motor threshold of the intact ( or dominant) hand hotspot in % of maximum stimulator output (MSO). \*The resting motor threshold of the face hotspot was 50% MSO for OH4 and 46% MSO for OH5.