

## Review Article



# Peri-implant disease: what we know and what we need to know

**Nicola Alberto Valente,<sup>1\*</sup> Sebastiano Andreana<sup>2</sup>**

<sup>1</sup>Department of Periodontics and Endodontics, State University of New York at Buffalo School of Dental Medicine, Buffalo, NY, USA

<sup>2</sup>Department of Restorative Dentistry, State University of New York at Buffalo School of Dental Medicine, Buffalo, NY, USA



Received: May 10, 2016

Accepted: Jun 14, 2016

### \*Correspondence to

**Nicola Alberto Valente**

Department of Periodontics and Endodontics, State University of New York at Buffalo School of Dental Medicine, 250 Squire Hall, 3435 Main St., Buffalo, NY 14214, USA. Tel: +1-716-939-5979, Fax: +1-716-829-6840, Email: nicolaal@buffalo.edu

Copyright © 2016 Korean Academy of Periodontology

This is an Open Access article distributed under the terms of the Creative Commons Attribution Non-Commercial License (<http://creativecommons.org/licenses/by-nc/3.0/>).

### ORCID

Nicola Alberto Valente

<http://orcid.org/0000-0003-1403-5274>

Sebastiano Andreana

<http://orcid.org/0000-0002-7476-8376>

### Conflict of Interest

No potential conflict of interest relevant to this article was reported.

## ABSTRACT

Peri-implant disease is a serious problem that plagues today's dentistry, both in terms of therapy and epidemiology. With the expansion of the practice of implantology and an increasing number of implants placed annually, the frequency of peri-implant disease has greatly expanded. Its clinical manifestations, in the absence of a globally established classification, are peri-implant mucositis and peri-implantitis, the counterparts of gingivitis and periodontitis, respectively.

However, many doubts remain about its features. Official diagnostic criteria, globally recognized by the dental community, have not yet been introduced. The latest studies using metagenomic methods are casting doubt on the assumption of microbial equivalence between periodontal and peri-implant crevices. Research on most of the features of peri-implant disease remains at an early stage; moreover, there is not a commonly accepted treatment for it. In any case, although the evidence so far collected is limited, we need to be aware of the current state of the science regarding this topic to better understand and ultimately prevent this disease.

**Keywords:** Dental implants; Diagnosis; Microbiota; Peri-implantitis; Periodontitis

## INTRODUCTION

Dental implant placement has been recognized for more than 30 years as a predictable, long-term option in the treatment of edentulous areas. Through the years, the validity of this treatment option has been confirmed by several long-term studies [1,2].

Nonetheless, the possible complications arising from this therapeutic option have attracted the attention of research from early on. Researchers have focused their attention on the effects of plaque accumulation and sustained bacterial infection around implants [3-5].

Peri-implant disease has become a main focus in terms of prevention and treatment, and has come to the attention of the major international dental associations in the field. In fact, two consecutive consensus conferences have been organized by the European Federation of Periodontology (EFP), in 2008 and 2011, to discuss the disease. At the first conference, researchers focused on the definition, diagnosis, prevalence, risk factors, and surgical and non-surgical treatment of peri-implant disease, and, at the second, they discussed more

thoroughly the similarities and differences between peri-implant mucositis/peri-implantitis and gingivitis/periodontitis, the relationships between tooth and implant biofilms, and the influence of surface characteristics on implant biofilm formation [6,7]. The third European Association for the Osseointegration (EAO) Consensus Conference in 2012 outlined the most recent evidence regarding prevalence, the role of occlusal overload, and the outcomes of surgical and non-surgical treatment [8]. More recently, in 2013, the American Academy of Periodontology (AAP) released its official statement regarding the diagnosis and clinical implications of peri-implant mucositis and peri-implantitis [9].

## ETIOLOGY AND DIAGNOSIS

None of the consensus statements from the EFP or EAO report any specific data regarding a determined probing depth by which we can make a diagnosis of peri-implant mucositis or peri-implantitis, but, rather, they refer to the presence of bleeding on probing (BOP) for peri-implant mucositis and progressive bone loss for peri-implantitis [6,7]. The AAP guidelines, conversely, refer to the diagnostic findings of BOP and bone loss at a probing depth (PD) of  $\geq 4$  mm [9]. Mombelli and Lang [10] state that pockets of 5 mm or more may serve as protected habitats for the putative pathogens of peri-implant disease, though they do not imply that a PD  $\geq 5$  mm is a diagnostic criterion for peri-implantitis. Indeed, they observe that peculiarity in the implant's design and surface characteristics can make probing impossible or increase resistance to probe penetration, and that marginal tissue recessions can lead to misinterpretation of the PD as an indicator of bone loss. For these reasons, attachment level relative to a fixed reference point on the implant or its suprastructure should be used as a reference for diagnostic implant probing.

The onset of peri-implant disease is caused by an imbalance between the bacterial load and the host defense. The microbiota responsible for the disease and the factors that can sustain and increase its detrimental potential will be discussed later in this chapter.

The criteria for a correct diagnosis of peri-implant disease have been clearly defined by Heitz-Mayfield in a review edited in the context of the 6<sup>th</sup> EFP Consensus [11]. According to this review, probing and radiographic assessment are the primary diagnostic means. Probing should be performed using a force of 0.25 N in order not to damage the peri-implant tissues and aims at assessing the presence of BOP, which indicates the presence of inflammation in the peri-implant mucosa. It is a predictor for the loss of tissue support. PD should be assessed regularly for the detection of BOP and possible suppuration, and to determine any increase in depth over time, which is usually associated with the loss of attachment and supporting bone.

Radiographs should also be taken regularly to assess the possible increase in bone loss. Thus far there has not been a settled, official classification distinguishing different degrees of severity of peri-implant disease, such as the classification we have for periodontal disease, but, in 2012, a classification was proposed by Froum and Rosen [12] (Table 1).

This classification uses, as diagnostic criteria, a dichotomous method based on PD and bone loss, dividing the disease into three clinical stages: early, with PD  $\geq 4$  mm and bone loss of less than 25% of the implant length; moderate, with PD  $\geq 6$  mm and bone loss between 25% and

**Table 1.** Classification of peri-implant disease

Types	Characteristics
Early	PD ≥ 4 mm (bleeding and/or suppuration on probing) Bone loss < 25% of the implant length
Moderate	PD ≥ 6 mm (bleeding and/or suppuration on probing) Bone loss 25% to 50% of the implant length
Advanced	PD ≥ 8 mm (bleeding and/or suppuration on probing) Bone loss > 50% of the implant length

PD, probing depth.

50% of the implant length; and advanced, with PD ≥8 mm and bone loss of more than 50% of the implant length.

A considerable advantage of this classification is the assessment of bone loss in terms of percentage of the total length, rather than in millimeters (since every implant has a different length and every implant system has a different shape).

Diagnostic prerequisites for this classification are the presence of inflammation and progressive bone loss. Clinical inflammation was defined as the presence of BOP, or suppuration at two out of six areas around the implant. Bone loss was defined as that seen and measured on radiographs that have been taken regularly.

A classification of the peri-implant defect configuration has been proposed by Schwarz et al. [13] after examining 40 implants affected by peri-implantitis in human subjects and after inducing peri-implantitis in 15 implants placed in five beagle dogs. The defects were classified as Class I when featuring a clear intrabony component (Figure 1 and 2), and Class II when the bone resorption was horizontal suprabony (Figure 3). Class I defects were further classified into five sub-categories (a-e) according to the configuration of the intrabony component (Table 2).

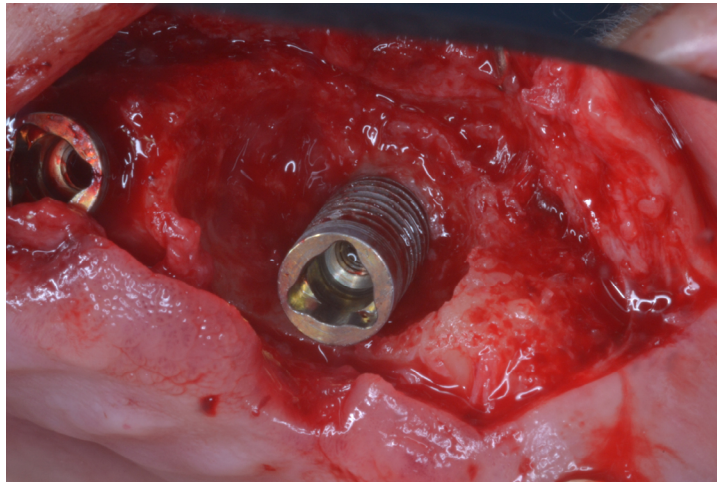
However, a new and commonly accepted classification system for peri-implant disease is expected from a workshop to be held in 2017 by the AAP and EFP [14].

## THE MICROBIOTA ASSOCIATED WITH PERI-IMPLANTITIS

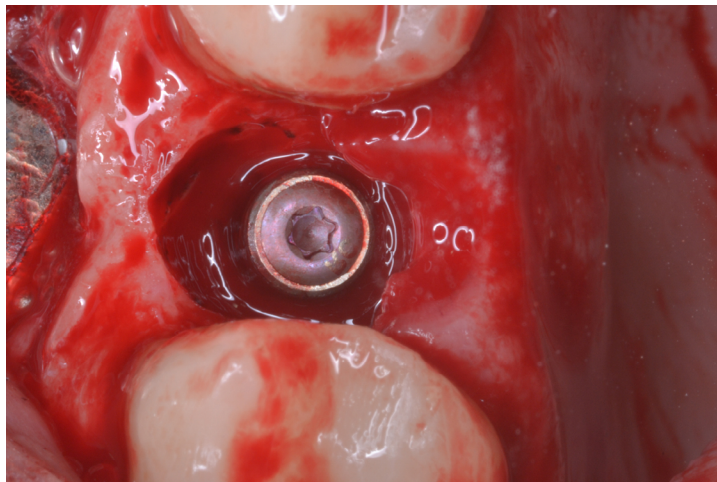
The subgingival microbial flora of diseased implants has generally been considered to have quite common characteristics. An early study from Rams et al. [15] showed that, while the microbial population surrounding healthy implants had high rates of coccoid gram-positive cells and few spirochetes, there was an inversion of this tendency with increasing PD and gingival inflammation. In most of the human studies assessing peri-implant

**Table 2.** Classification of periodontal bony defects

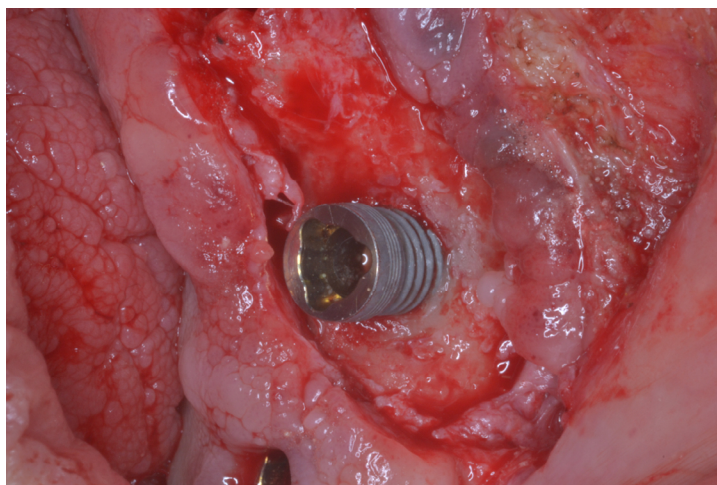
Types	Characteristics
Class I	<ul style="list-style-type: none"> <li>a Combined horizontal and vertical loss of the adjacent vestibular alveolar bone, leading to a dehiscence-type defect.</li> <li>b Higher dehiscence values than Class Ia defects and clearly identifiable mesial and distal circumferential component.</li> <li>c Additional circumferential component measured as the linear mid-oral distance from the implant surface to the inner surface of the alveolar bone components, without resulting in a dehiscence-type defect on the oral aspect.</li> <li>d Clear mesial and distal component with oral and vestibular dehiscence.</li> <li>e Clear mesial, distal, vestibular, and oral component without a dehiscence-type defect.</li> </ul>
Class II	Consistent horizontal bone loss, identifiable as supra-alveolar exposition of the implant.



**Figure 1.** Class I-c peri-implant defect.



**Figure 2.** Class I-e peri-implant defect.



**Figure 3.** Class II peri-implant defect.

microbiota, there is a consistently high incidence of Prevotellaceae (*P. intermedia*, *P. buccae*, *P. oralis*, *P. melaninogenica*, *P. denticola*, *P. nigrescens*), *Porphyromonas gingivalis*, *Fusobacterium nucleatum*, *Tannerella forsythia*, and *Treponema denticola* in diseased implants, as well as coccoid gram positive cells in healthy implants [16-22]. These findings have been confirmed by experimental studies on ligature-induced peri-implantitis on animal models, in which the characteristic shift in the microbial flora has been confirmed [23-26].

The finding of *Aggregatibacter actinomycetemcomitans* is inconstant with the findings of the other studies; this might be due to the individual composition of the oral microflora of the patients included in the studies [17,18].

The colonization of the implant's surface by microbial species starts already 30 minutes after implant placement, and the bacteria load stays the same for the first week. Between the first and the twelfth week after surgery, the bacterial load becomes significantly higher for several species, among which are *P. gingivalis*, *T. forsythia*, and *T. denticola* [22]. At 12 months, the bacterial load appears to be significantly higher for some species, in particular *T. forsythia* and, to a lesser extent, *P. gingivalis* [21].

According to the studies cited above, the bacterial composition of the peri-implant biofilm closely resembles that of the neighboring teeth, which implies that the microbial flora on natural teeth serve as the reservoir for the biofilm formation around implants. In the same way, the qualitative composition of the biofilm microflora in peri-implantitis resembles that of periodontitis, which explains why patients with active periodontal disease are at higher risk for peri-implantitis. In support of this theory, a study conducted by Kočar et al. [27] on a population of partially edentulous and fully edentulous patients found that the peri-implant and periodontal sulci of partially edentulous patients had no differences in the microflora, sharing the same periodontopathogenic species, but none of these bacteria were found in the peri-implant sulci or the alveolar gingiva of completely edentulous patients. Moreover, a few studies on humans have shown the presence of non-periodontal microbial species, such as *Pseudomonas aeruginosa*, *Candida albicans*, *Staphylococcus aureus*, and *Staphylococcus Warneri*, around diseased implants [18,19,28]. In particular, Albertini et al. [19] found, in two patients out of 33, a complete absence of periodontal microorganisms commonly found in periodontitis.

However, all the above-mentioned studies have the limitation of using culture-dependent or molecular methods to detect bacteria around implants. The culture-dependent methods initially used are time consuming and limited only to the cultivable species. Molecular methods, such as PCR or DNA-DNA hybridization, are faster, but have the disadvantage of a need to pre-select DNA probes for the specific bacterial taxa investigated, thus creating a sort of bias. In fact, most of the knowledge of peri-implant microbiota derives from periodontitis. In recent years, the latest sequencing technologies, such as the 16S rRNA sequencing, have been able to overcome the limitations of both the methods mentioned above and have introduced a new concept of the "microbiome," intended to refer to the full collection of genes of all the microbes in a community [29]. These culture-independent metagenomic methods are potentially able to identify previously undetected and uncultivable bacteria, as well as different strains of known bacteria, allowing the analysis of genetic material harvested directly from the oral microbial environment. The Human Oral Microbiome Database (HOMD) includes 619 taxa in 13 phyla, as follows: Actinobacteria, Bacteroidetes, Chlamydiae, Chloroflexi, Euryarchaeota, Firmicutes, Fusobacteria, Proteobacteria, Spirochaetes, SR1, Synergistetes, Tenericutes, and TM7. Fifty-four percent are officially named, 14% unnamed

(but cultivated) and 32% are known only as uncultivated phylotypes [30].

There are only a few studies thus far that have used metagenomic methods of investigation, but the results are interesting and pave the way to a paradigm shift in the understanding of peri-implantitis disease. Kumar et al. [31] found a unique microbial population in peri-implant sulci (both healthy and diseased) compared to periodontal-associated biofilm, with lower levels of *Prevotella*, non-mutans *Streptococcus*, *Lactobacillus*, *Selenomonas*, *Leptotrichia*, and *Actinomyces*, and higher levels of *Peptococcus*, *Mycoplasma*, *Eubacterium*, *Campylobacter*, *Butyrivibrio*, *S. mutans*, and *Treponema*. In a subsequent study, they also concluded that local proximity of teeth to the implant is not sufficient to determine colonization, in contrast with the previous theory based on culture-based and molecular methods [32]. Sixty percent of subjects analyzed in the aforementioned study shared less than 50% of all species between their periodontal and peri-implant biofilms, and 85% of individuals shared less than 8% of abundant species between tooth and implant. Consistent with these results, a study by Koyanagi et al. [33] found 192 and 148 bacterial taxa in peri-implant and periodontal sites, respectively, and the microbial composition of peri-implantitis was more diverse when compared with that of periodontitis. The microbial diversity of peri-implantitis was also detected in a study by van der Horst et al. [34], but clinical parameters such as probing depth and dentate status were determinant for the composition of the submucosal microbiome.

Zhang et al. [35] found that *Catonella*, *Desulfovibrio*, *Mogibacterium*, *Peptostreptococcus*, and *Propionibacterium* were present in greater abundance in chronic periodontitis subjects, while implant subjects had higher proportions of *Brevundimonas* and *Pseudomonas* species. Zheng et al. [36] noted that putative pathogens associated with peri-implantitis were present at a moderate level relative to their abundance in peri-implant mucositis and that *Eubacterium minutum* levels were greater at peri-implantitis locations.

Synergistetes—a bacterial phylum of gram-negative curved rods recently associated with chronic periodontitis—necrotizing gingivitis, and endodontic infections have been detected in two recent studies [37,38]. Belisabakis et al. [37] found that Spirochaetes of the *Treponema* groups I–III, but not group IV, and Synergistetes of cluster A were highly associated with peri-implantitis and that these latter species appear to display a stronger association with peri-implantitis than Spirochaetes. Yu et al. [38] investigated the presence of Synergistetes in healthy and diseased periodontal and peri-implant sites and found 25 of oral cluster A and one of oral cluster B, belonging to the species of *Fretibacterium fastidiosum* and *Pyramidobacter piscolens*, and the results showed that diverse Synergistetes populations inhabit both diseased and healthy periodontal and peri-implant niches.

## HOST-RESPONSE IN PERI-IMPLANT DISEASE

After an initial focus on the etiology and microbiology of peri-implantitis, the attention of research since the late 90s has shifted towards the host-response and inflammatory mediators involved in the disease. A study from Salcetti et al. [39] has shown the significantly elevated levels of PGE<sub>2</sub>, IL-1 $\beta$ , and PDGF in the crevicular fluid of implants affected by peri-implantitis, as compared to mouths with healthy control implants. Plagnat et al. [40] showed how levels of alkaline phosphatase activity, elastase activity, and  $\alpha$ 2-macroglobulin, markers commonly associated with periodontitis, were significantly higher in crevicular fluid collected around

implants with peri-implantitis, as compared to crevicular fluid from healthy implants.

More recently, Duarte et al. [41] have assessed, using quantitative polymerase chain reaction, the gene expression of inflammation-related factors such as interleukin (IL)-12, tumor necrosis factor- $\alpha$  (TNF- $\alpha$ ), IL-4, and IL-10, and osteoclastogenesis-related factors such as receptor activator of NF- $\kappa$ B ligand (RANKL) and osteoprotegerin (OPG) in gingival biopsy from healthy implants and implants showing mucositis, initial peri-implantitis, and severe peri-implantitis. The results showed that, regarding the inflammation-related factors, IL-12 and TNF- $\alpha$  mRNA levels were significantly higher in severe peri-implantitis, followed by initial peri-implantitis, and mucositis, while IL-4 was higher in healthy implants, followed by mucositis, severe, and initial peri-implantitis. Concerning osteoclastogenesis-related factors, OPG mRNA levels were higher in healthy implants, followed by initial peri-implantitis, severe peri-implantitis, and mucositis, whereas RANKL increased as the severity of peri-implantitis increased.

Several studies have focused their attention on the correlation between IL-1 $\beta$  gene polymorphism and peri-implantitis. IL-1 genotype-positive patients strongly overproduce the inflammatory mediator interleukin-1, making them more prone to develop periodontitis. The results of these studies are so far contradictory and have been summarized in a review by Bormann et al. [42] There, the results were categorized as follows: IL-1 polymorphism is not related to periimplantitis; the influence of IL-1 polymorphism on peri-implantitis is not clear; a correlation exists between IL-1 polymorphism and peri-implantitis; a correlation exists between IL-1 polymorphism and peri-implantitis given certain risk factors; further examination and consideration of interleukin-1 polymorphism and implants is needed to clarify this correlation.

## PROGRESSION

As mentioned previously, a key principle in the detection of peri-implantitis is the progressive bone loss around the titanium fixture, which is even more important in light of the inadequate reliability of PD alone for diagnosis. In order to be able to correctly identify pathologic progressive bone destruction, it is necessary to understand the process of bone remodeling around an implant. In a three-year prospective longitudinal study on implants placed in edentulous patients, Adell et al. [3] observed that a mean of 0.9 mm of marginal bone was lost during the first year after loading and about 0.05 mm annually for the following two years. In addition, the peri-implant bone gradually becomes more radiopaque, indicating successive load-related remodeling.

In a study aimed at assessing the spontaneous progression of experimental peri-implantitis, Zitzmann et al. [43] induced the disease around 22 osseointegrated implants placed in five beagle dogs, placing ligatures and allowing plaque accumulation until about 40% of the marginal bone was lost, after which the ligatures were removed without reinstating any plaque control measures for an additional 12 months. In the ligature period, all the implants lost a comparable amount of marginal bone; after removal, the bone loss continued with different degrees of severity for each implant, with five implants showing no changes, 10 implants showing 0 to 1 mm of further loss, two implants showing 1 to 2 mm and four implants showing more than 2 mm of additional bone loss. Histologically, the mucosa of all implant sites harbored inflammatory lesions extending apically to the pocket epithelium, separated from the marginal bone by a zone of apparently normal connective tissue. The authors state

that the variability in the severity of bone loss might be due to differences between implant sites in terms of local microbiota, or the quality of the host's response to the infection.

In a different study that used exactly the same protocol of the study described above, Beglundh et al. [44] induced peri-implantitis in five beagle dogs using two different implant surfaces, sandblasted acid-etched surface (SLAS) or a polished surface (PS). Radiographic analysis showed similar amounts of bone loss at SLAS and PS implants during the ligature period, while the progression of bone loss was greater at SLAS than at PS implants after ligature removal. Furthermore, the histological examination showed that both bone loss and the size of the inflammatory lesion in the connective tissue were greater in SLAS than in PS implant lesions.

In a similar study, Martins et al. [45] induced the same experimental peri-implantitis around 36 implants placed in six mongrel dogs, with the difference that, after 60 days of disease induction, ligatures were removed but a plaque control regimen was reinstated, thus creating a condition, as designated by the authors, of experimental chronic peri-implantitis. The implants had four different surfaces but no statistically significant differences between the surfaces were noted in the progression of the disease prior to and following ligature removal. Clinical attachment loss showed a statistically significant increase both after ligature placement and after ligature removal, with a decrease after ligature removal that was statistically significant compared to the "acute" phase (the first 60 days). Bone loss increased, with statistical significance observed, after ligature placement, and continued after ligature removal. In any case, a statistically significant decrease in bone resorption, compared to the acute phase, was observed.

Fransson et al. [46] performed a radiographic analysis of 419 implants diagnosed with peri-implantitis, from 182 subjects, between the first year follow-up and the endpoint examination, which varied between 5 and 23 years. After the first year of loading, the bone loss was 1.68 mm with 32% of the implants showing  $\geq 2$  mm of bone loss. The bone loss showed a non-linear pattern and an increase in rate over time. They further noted that the pattern of bone loss around implants was similar within the same subject.

## RISK INDICATORS

Placement of implants in the maxilla, in males, and in those with a history of periodontitis have been identified as risk indicators [47-49]. Several other risk factors have been associated with the development of peri-implant disease and will be described here. The role of occlusal overload as a single risk factor is not clearly determined, despite the indications from some studies that suggest that overload per se is not associated with tissue destruction and peri-implant disease in absence of plaque. Occlusal overload may play a role when associated with plaque accumulation or pre-existing inflammation. However, the data is not clear [50-52].

### History of periodontitis

A history of periodontitis seems to affect the outcomes of the implant therapy and increase the risk of peri-implantitis. In a prospective study with follow-up at 10 years on 53 patients receiving 112 ITI implants, the survival rate was 90.5% in patients with a previous history of periodontitis and 96.5% in patients with no history of periodontitis. The incidence of peri-



implantitis was 28.6% in patients with a history of periodontitis, and 5.8% in those patients without a history of the disease [53].

A meta-analysis by Sgolastra et al. [54] showed that patients who were periodontally compromised had an increased risk of a higher plaque index (PI) when compared with patients without periodontitis. The same meta-analysis showed a higher and significant risk for both implant loss and implant bone loss in patients with periodontitis than in those who were periodontally healthy.

In a 10-year prospective cohort study, Rocuzzo et al. [55] showed that patients with a history of periodontitis have a higher rate of implant loss and sites with  $\geq 6$  mm PD around implants.

### Smoking

Though a smoking habit is commonly considered to be detrimental for implant survival, Koldslund et al. [47] could not find an association between smoking and peri-implant disease. Roos-Jansåker et al. [48,49] also did not find a significant relationship between smoking habits and implant loss, although they indicated smokers as having more mucositis, bone level at  $\geq 3$  threads, and peri-implantitis. A different meta-analysis by Sgolastra et al. [56] showed, in the implant-based results, that smokers have a higher and significant risk of peri-implantitis compared with nonsmokers, but the patient-based meta-analysis did not reveal any significant differences in risks of peri-implantitis for smokers. No evidence of significant heterogeneity was detected for the two analyses.

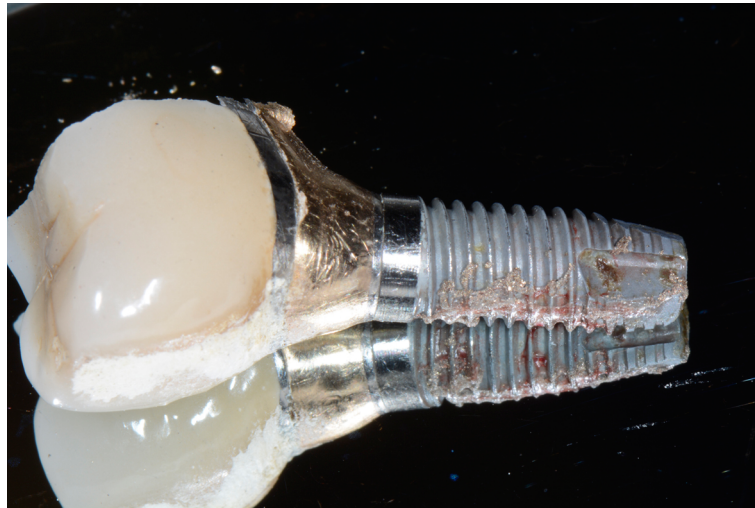
Concerning the microbiological aspect, it has been shown that current smokers harbor more periodontal pathogens in the peri-implant sulci, thus implying a potential risk for the onset of peri-implant disease [28].

In conclusion, the evidence that smoking is a risk factor for peri-implantitis is limited, and more studies are needed to confirm this assumption.

### Oral hygiene and supportive periodontal therapy

Oral hygiene plays a key role in the implant survival rate. The hygiene of the implants and implant-supported prosthesis must be maintained with daily home care and with the patient adhering to a supportive maintenance program. A study on 23 patients, for a total of 109 implants showing signs of peri-implantitis, has demonstrated that, despite a higher plaque index commonly associated with the disease, a very high rate (48%) of implants showing signs of peri-implantitis had no accessibility for proper oral hygiene measures, while accessibility was rarely associated with peri-implant disease (4%) [57].

In a study by Pjetursson et al. [58], differences in the prevalence of peri-implantitis at follow-up visits, were seen between the patients that had been incorporated into a well-organized supportive periodontal therapy (SPT) program both at the university where the study was conducted and by their referring private practitioners. However, these differences did not reach statistical significance. In this study, only 12 patients out of 70 were enrolled in a SPT program at a private practice, and the authors did not have data about the actual attendance of these patients, so the conclusions are based only on the assumption that those few patients receiving SPT outside the university might have had less consistent attendance.



**Figure 4.** Implant removed for advanced peri-implantitis with a clear cement remnant visible on the prosthetic crown.

In a 10-year prospective cohort study, Rocuzzo et al. [55] showed that patients with inconsistent attendance at an SPT program showed worse results in terms of their PI, BOP, mean PD, number of teeth lost during SPT, and mean deepest PD at the 10-year examination, as well as mean deepest PD registered during follow-up, with the difference in these parameters being statistically significant when compared with patients adhering to the SPT.

#### Excess of cementum

In a retrospective analysis on 77 patients with 129 implants referred for mechanical or biological complications, cement remnants were found in 11 of 32 implants affected by mechanical complications, and in 62 of 97 implants that had biological complications, for a total of 73 implants out of 129 (56%) with complications [59]. Peri-implant disease developed in 62 of the 73 implants with cement remnants (85%). Early peri-implant disease occurred in seven implants (12%) and delayed disease developed in 55 cases (88%) (Figure 4). All the patients with a previous history of periodontitis that had implants with extracoronary cement residuals developed peri-implantitis.

## PREVALENCE

A study conducted in 1999 at the Brånemark clinic in Gothenburg, Sweden on patients with implants that had at least 5 years of follow-up showed that, analyzing all the implants that showed bone loss to a level of  $\geq 3$  threads and that had progressive bone loss defined as bone-level alterations occurring between the first year examination and the  $\geq 5$ -year follow-up, 184 (27.8%) of 662 subjects had one or more implants with progressive bone loss, and 423 implants (12.4%) out of the 3,413 implants demonstrated progressive bone loss [60].

Roos-Jansåker et al. [61] showed that, during an observation period of 9–14 years on 218 patients and 999 implants, 48% of the implants and 76.6% of the patients demonstrated probing depths  $\geq 4$  mm with BOP, and 7% of the implants and 18.3% of the patients had probing depths  $\geq 6$  mm with BOP. They observed that 16.0% of the implants and 48% of the patients had pockets  $\geq 4$  mm and BOP, but no concomitant bone loss. The diagnosis of

peri-implantitis in this study was done with bone loss  $\geq 3$  threads (a minimum bone loss of 1.8 mm) following the first year in function combined with BOP and/or pus on probing. According to this definition, 16% of the patients and 6.6% of the implants were diagnosed with peri-implantitis during the observation period.

In a different study, Koldslund et al. [62], assessed the prevalence of mucositis and peri-implantitis in 99 patients and 351 implants. They defined mucositis as the presence of inflammation without detectible bone loss and peri-implantitis as detectible peri-implant bone loss with inflammation. An interesting aspect of this study is that the analysis was carried out on four different levels of severity of the disease: radiographic peri-implant bone loss  $\geq 2.0$  mm and BOP/suppuration at PD  $\geq 4$  or  $\geq 6$  mm; and radiographic peri-implant bone loss  $\geq 3.0$  mm and BOP/suppuration at PD  $\geq 4$  or  $\geq 6$  mm. Mucositis was detected in 27.3% of implants and 39.4% of patients. Peri-implantitis, according to the categories mentioned previously, was found in 20.4%, 15.1%, 11.7%, and 11.3% of patients, and 11.4%, 7.7%, 6.0%, and 5.4% of implants, respectively.

It is clearly noticeable from the few studies mentioned above that, regardless of the way the study is conducted, the definition of peri-implant disease varies. It is reasonable to assume that such variability could affect the results in terms of prevalence, since a single millimeter of difference in the diagnosis of peri-implantitis can include or exclude a great number of subjects from the total count.

The problem presented by this limitation was evidenced and reported by Zitzmann and Berglundh [63] in a review. In their report, they define peri-implantitis as the presence of BOP and concomitant bone loss, regardless of any specific amount measured in millimeters or threads, and categorize as “peri-implant disease” all those studies reporting data on BOP without information on bone loss. Despite these relatively lax inclusion criteria, only nine studies, related to six different subject samples, were included, and only two studies had data clearly specifying the presence of mucositis and/or peri-implantitis. The frequencies reported by the review, then, were those obtained by the only two study samples available, which are the already-mentioned Fransson et al. [60] and Roos-Jansåker et al. [61].

A more recent systematic review by Atieh et al. [64] including a larger number of studies after the application of selection criteria, applies a definition of peri-implant mucositis as an inflamed mucosa with a bleeding index of  $\geq 2$  and/or suppuration, but without bone loss. Peri-implantitis is defined as the presence of inflamed mucosa with a positive BOP, PD  $\geq 5$  mm, and cumulative bone loss of  $\geq 2$  mm and/or  $\geq 3$  threads of implant. The nine papers included in the meta-analysis of this review included a total of 6,283 implants and 1,497 patients followed during an observation period ranging from five years to more than 10 years. At the patient level, the overall frequency of peri-implant mucositis and peri-implantitis was 63.4% and 18.8%, respectively. At the implant level, the overall frequency of peri-implant mucositis and peri-implantitis was 30.7% and 9.6%.

In conclusion, it does not seem possible to clearly define the prevalence of peri-implantitis as long as commonly accepted diagnostic criteria for peri-implant disease have not been adopted.

## PERI-IMPLANTITIS VS. PERIODONTITIS

Periodontal and peri-implant tissues are obviously extremely different, and the most evident difference is the presence of a ligament around a tooth compared to the ankylosed state of an implant. At a microscopic level, already in 1984, Gould et al. [65] demonstrated the presence of a hemidesmosomal attachment at the epithelium–implant surface in contrast to the fibrous junctional epithelium of the periodontium. We have already shown in this discussion how the peri-implant microbiota closely resemble, in health and in disease, the microbiota of the periodontium, and that the inflammatory mediators involved are the same in peri-implant and periodontal disease. Most of the risk factors previously discussed, except for excess of cementum, relate to those involved in periodontitis.

Several animal studies in the early 90s have compared the initiation and progression of peri-implant disease and then compared that to periodontal disease. One of the first studies using a canine model showed that tissue destruction proceeds more slowly around implants than around natural teeth [51]. This finding was later contradicted by subsequent animal studies. Lindhe et al. [4], using a dog model, induced peri-implantitis and showed that signs of tissue destruction were more pronounced in dental implants than in natural teeth. Using both clinical signs and radiographs, they showed that the size of the soft tissue lesions were larger surrounding dental implants than around natural teeth. Interestingly, the lesions around dental implants extended into the bone marrow, but those around natural teeth did not. Lang et al. [5], using a cynomolgus monkey model, showed that development of peri-implant infections progressed at a similar rate to the development of a periodontal lesion.

Chambrone et al. [52], using a similar model, induced peri-implantitis and periodontitis around ankylosed teeth and control teeth. They demonstrated that loss of bone height was significant, and limited to implants and ankylosed teeth, and that it did not occur in normal teeth used as controls. Bone loss around implants was significantly greater than that observed around ankylosed teeth.

The results of these early animal studies have been confirmed by studies on human subjects. In a study on 275 implants in 50 subjects, Karoussis et al. [53] concluded that, over a period of 30 months post-loading, the peri-implant mucosa demonstrated a significantly greater likelihood of having elevated inflammation and plaque when compared to the gingiva around natural teeth. Sgolastra et al. [54] compared peri-implant disease initiation in 15 healthy subjects. He measured plaque accumulation and inflammatory parameters, inflammatory mediators, and microbiota around implants and teeth over a period of three weeks of undisturbed plaque accumulation. He then introduced three weeks of subsequent plaque control. He found a significant increase in plaque and gingival indices in implant sites, compared to natural teeth. He found a significantly higher increase of MMP-8 at implant crevicular fluid, but no differences in levels of IL-1 $\beta$ , and no differences in the detection of putative periodontal pathogens between implant and natural tooth sites.

## CONCLUSION

Current knowledge, although limited, suggests that peri-implant disease is a condition that, while having several traits in common with periodontal disease, is probably much more complex and with unique and distinctive features that need to be thoroughly investigated.

A history of periodontitis, lack of maintenance, and cement remnants are certainly factors that play a significant role in the development of the disease and should be addressed from the beginning.

Recent discoveries in microbiology open a completely new perspective on the etiology of peri-implant disease and the further development of metagenomics might open the way to thoroughly new therapeutic approaches. A complete knowledge of oral and peri-implant microbiota in health and disease in their full genomic composition could potentially lead to the development of a microbiota transplant therapy, as has been developed and successfully used in other fields of medicine, for example fecal transplant in gastroenterology [66].

The development of a globally accepted classification system, expected from the future 2017 workshop, will help not only in diagnosis but in all epidemiological investigations on the prevalence, incidence, and distribution of this disease.

Treatment of peri-implant disease is not the object of this review but, in absence of any clearly defined therapy supported by evidence, we believe that a thorough knowledge of this disease, supported by the concepts introduced here, will allow the clinician to better understand and prevent its occurrence and arrest its progression.

## REFERENCES

1. Adell R, Lekholm U, Rockler B, Brånemark PI. A 15-year study of osseointegrated implants in the treatment of the edentulous jaw. *Int J Oral Surg* 1981;10:387-416.  
[PUBMED](#) | [CROSSREF](#)
2. Iacono VJ Committee on Research, Science and Therapy, the American Academy of Periodontology. Dental implants in periodontal therapy. *J Periodontol* 2000;71:1934-42.  
[PUBMED](#) | [CROSSREF](#)
3. Adell R, Lekholm U, Rockler B, Brånemark PI, Lindhe J, Eriksson B, et al. Marginal tissue reactions at osseointegrated titanium fixtures (I). A 3-year longitudinal prospective study. *Int J Oral Maxillofac Surg* 1986;15:39-52.  
[PUBMED](#) | [CROSSREF](#)
4. Lindhe J, Berglundh T, Ericsson I, Liljenberg B, Marinello C. Experimental breakdown of peri-implant and periodontal tissues. A study in the beagle dog. *Clin Oral Implants Res* 1992;3:9-16.  
[PUBMED](#) | [CROSSREF](#)
5. Lang NP, Brägger U, Walther D, Beamer B, Kornman KS. Ligature-induced peri-implant infection in cynomolgus monkeys. I. Clinical and radiographic findings. *Clin Oral Implants Res* 1993;4:2-11.  
[PUBMED](#) | [CROSSREF](#)
6. Lindhe J, Meyle J Group D of European Workshop on Periodontology. Peri-implant diseases: Consensus Report of the Sixth European Workshop on Periodontology. *J Clin Periodontol* 2008;35 Suppl:282-5.  
[PUBMED](#) | [CROSSREF](#)
7. Lang NP, Berglundh T Working Group 4 of Seventh European Workshop on Periodontology. Periimplant diseases: where are we now?--Consensus of the Seventh European Workshop on Periodontology. *J Clin Periodontol* 2011;38 Suppl 11:178-81.  
[PUBMED](#) | [CROSSREF](#)
8. Klinge B, Meyle J Working Group 2. Peri-implant tissue destruction. The Third EAO Consensus Conference 2012. *Clin Oral Implants Res* 2012;23 Suppl 6:108-10.  
[PUBMED](#) | [CROSSREF](#)
9. Peri-implant mucositis and peri-implantitis: a current understanding of their diagnoses and clinical implications. *J Periodontol* 2013;84:436-43.  
[PUBMED](#) | [CROSSREF](#)
10. Mombelli A, Lang NP. Clinical parameters for the evaluation of dental implants. *Periodontol* 2000

- 1994;4:81-6.  
[PUBMED](#) | [CROSSREF](#)
11. Heitz-Mayfield LJ. Peri-implant diseases: diagnosis and risk indicators. *J Clin Periodontol* 2008;35 Suppl:292-304.  
[PUBMED](#) | [CROSSREF](#)
  12. Froum SJ, Rosen PS. A proposed classification for peri-implantitis. *Int J Periodontics Restorative Dent* 2012;32:533-40.  
[PUBMED](#)
  13. Schwarz F, Herten M, Sager M, Bieling K, Sculean A, Becker J. Comparison of naturally occurring and ligature-induced peri-implantitis bone defects in humans and dogs. *Clin Oral Implants Res* 2007;18:161-70.  
[PUBMED](#) | [CROSSREF](#)
  14. American Academy of Periodontology Task Force report on the update to the 1999 classification of periodontal diseases and conditions. *J Periodontol* 2015;86:835-8.  
[PUBMED](#) | [CROSSREF](#)
  15. Rams TE, Roberts TW, Tatum H Jr, Keyes PH. The subgingival microbial flora associated with human dental implants. *J Prosthet Dent* 1984;51:529-34.  
[PUBMED](#) | [CROSSREF](#)
  16. Mombelli A, van Oosten MA, Schurch E Jr, Land NP. The microbiota associated with successful or failing osseointegrated titanium implants. *Oral Microbiol Immunol* 1987;2:145-51.  
[PUBMED](#) | [CROSSREF](#)
  17. Augthun M, Conrads G. Microbial findings of deep peri-implant bone defects. *Int J Oral Maxillofac Implants* 1997;12:106-12.  
[PUBMED](#)
  18. Leonhardt A, Renvert S, Dahlén G. Microbial findings at failing implants. *Clin Oral Implants Res* 1999;10:339-45.  
[PUBMED](#) | [CROSSREF](#)
  19. Albertini M, López-Cerero L, O'Sullivan MG, Chereguini CF, Ballesta S, Ríos V, et al. Assessment of periodontal and opportunistic flora in patients with peri-implantitis. *Clin Oral Implants Res* 2015;26:937-41.  
[PUBMED](#) | [CROSSREF](#)
  20. Botero JE, González AM, Mercado RA, Olave G, Contreras A. Subgingival microbiota in peri-implant mucosa lesions and adjacent teeth in partially edentulous patients. *J Periodontol* 2005;76:1490-5.  
[PUBMED](#) | [CROSSREF](#)
  21. Salvi GE, Fürst MM, Lang NP, Persson GR. One-year bacterial colonization patterns of *Staphylococcus aureus* and other bacteria at implants and adjacent teeth. *Clin Oral Implants Res* 2008;19:242-8.  
[PUBMED](#) | [CROSSREF](#)
  22. Fürst MM, Salvi GE, Lang NP, Persson GR. Bacterial colonization immediately after installation on oral titanium implants. *Clin Oral Implants Res* 2007;18:501-8.  
[PUBMED](#) | [CROSSREF](#)
  23. Hickey JS, O'Neal RB, Scheidt MJ, Strong SL, Turgeon D, Van Dyke TE. Microbiologic characterization of ligature-induced peri-implantitis in the microswine model. *J Periodontol* 1991;62:548-53.  
[PUBMED](#) | [CROSSREF](#)
  24. Hanisch O, Cortella CA, Boskovic MM, James RA, Slots J, Wikesjö UM. Experimental peri-implant tissue breakdown around hydroxyapatite-coated implants. *J Periodontol* 1997;68:59-66.  
[PUBMED](#) | [CROSSREF](#)
  25. Charalampakis G, Abrahamsson I, Carcuac O, Dahlén G, Berglundh T. Microbiota in experimental periodontitis and peri-implantitis in dogs. *Clin Oral Implants Res* 2014;25:1094-8.  
[PUBMED](#) | [CROSSREF](#)
  26. Zhuang LF, Watt RM, Mattheos N, Si MS, Lai HC, Lang NP. Periodontal and peri-implant microbiota in patients with healthy and inflamed periodontal and peri-implant tissues. *Clin Oral Implants Res* 2016;27:13-21.  
[PUBMED](#) | [CROSSREF](#)
  27. Kocar M, Seme K, Hren NI. Characterization of the normal bacterial flora in peri-implant sulci of partially and completely edentulous patients. *Int J Oral Maxillofac Implants* 2010;25:690-8.  
[PUBMED](#)
  28. Eick S, Ramseier CA, Rothenberger K, Brägger U, Buser D, Salvi GE. Microbiota at teeth and implants in partially edentulous patients. A 10-year retrospective study. *Clin Oral Implants Res* 2016;27:218-25.  
[PUBMED](#) | [CROSSREF](#)
  29. Charalampakis G, Belibasakis GN. Microbiome of peri-implant infections: lessons from conventional,

- molecular and metagenomic analyses. *Virulence* 2015;6:183-7.  
[PUBMED](#) | [CROSSREF](#)
30. Dewhirst FE, Chen T, Izard J, Paster BJ, Tanner AC, Yu WH, et al. The human oral microbiome. *J Bacteriol* 2010;192:5002-17.  
[PUBMED](#) | [CROSSREF](#)
  31. Kumar PS, Mason MR, Brooker MR, O'Brien K. Pyrosequencing reveals unique microbial signatures associated with healthy and failing dental implants. *J Clin Periodontol* 2012;39:425-33.  
[PUBMED](#) | [CROSSREF](#)
  32. Dabdoub SM, Tsigarida AA, Kumar PS. Patient-specific analysis of periodontal and peri-implant microbiomes. *J Dent Res* 2013;92 Suppl:168S-75S.  
[PUBMED](#) | [CROSSREF](#)
  33. Koyanagi T, Sakamoto M, Takeuchi Y, Maruyama N, Ohkuma M, Izumi Y. Comprehensive microbiological findings in peri-implantitis and periodontitis. *J Clin Periodontol* 2013;40:218-26.  
[PUBMED](#) | [CROSSREF](#)
  34. van der Horst J, Laine ML, Zaura E, Buijs MJ, Wismeijer D, Crielaard W, et al. Analysis of peri-implant sulcus/pocket microbiome. The 92nd General Session & Exhibition of the IADR; 2014 Jun 25-28; Cape Town, South Africa. Alexandria (VA): International Association for Dental Research; 2014. Abstr 1417.
  35. Zhang Q, Qin XY, Jiang WP, Zheng H, Xu XL, Chen F. Comparison of Subgingival and Peri-implant Microbiome in Chronic Periodontitis. *Chin J Dent Res* 2015;18:155-62.  
[PUBMED](#)
  36. Zheng H, Xu L, Wang Z, Li L, Zhang J, Zhang Q, et al. Subgingival microbiome in patients with healthy and ailing dental implants. *Sci Rep* 2015;5:10948.  
[PUBMED](#) | [CROSSREF](#)
  37. Belibasakis GN, Mir-Mari J, Sahrman P, Sanz-Martin I, Schmidlin PR, Jung RE. Clinical association of Spirochaetes and Synergistetes with peri-implantitis. *Clin Oral Implants Res* 2016;27:656-61.  
[PUBMED](#) | [CROSSREF](#)
  38. Yu XL, Chan Y, Zhuang LF, Lai HC, Lang NP, Lacap-Bugler DC, et al. Distributions of Synergistetes in clinically-healthy and diseased periodontal and peri-implant niches. *Microb Pathog* 2016;94:90-103.  
[PUBMED](#) | [CROSSREF](#)
  39. Salcetti JM, Moriarty JD, Cooper LF, Smith FW, Collins JG, Socransky SS, et al. The clinical, microbial, and host response characteristics of the failing implant. *Int J Oral Maxillofac Implants* 1997;12:32-42.  
[PUBMED](#)
  40. Plagnat D, Giannopoulou C, Carrel A, Bernard JP, Mombelli A, Belser UC. Elastase, alpha2-macroglobulin and alkaline phosphatase in crevicular fluid from implants with and without periimplantitis. *Clin Oral Implants Res* 2002;13:227-33.  
[PUBMED](#) | [CROSSREF](#)
  41. Duarte PM, de Mendonça AC, Máximo MB, Santos VR, Bastos MF, Nociti Júnior FH. Differential cytokine expressions affect the severity of peri-implant disease. *Clin Oral Implants Res* 2009;20:514-20.  
[PUBMED](#) | [CROSSREF](#)
  42. Bormann KH, Stühmer C, Z'Graggen M, Kokemöller H, Rücker M, Gellrich NC. IL-1 polymorphism and periimplantitis. A literature review. *Schweiz Monatsschr Zahnmed* 2010;120:510-20.  
[PUBMED](#)
  43. Zitzmann NU, Berglundh T, Ericsson I, Lindhe J. Spontaneous progression of experimentally induced periimplantitis. *J Clin Periodontol* 2004;31:845-9.  
[PUBMED](#) | [CROSSREF](#)
  44. Berglundh T, Gotfredsen K, Zitzmann NU, Lang NP, Lindhe J. Spontaneous progression of ligature induced peri-implantitis at implants with different surface roughness: an experimental study in dogs. *Clin Oral Implants Res* 2007;18:655-61.  
[PUBMED](#) | [CROSSREF](#)
  45. Martins MC, Shibli JA, Abi-Rached RS, Marcantonio E Jr. Progression of experimental chronic peri-implantitis in dogs: clinical and radiographic evaluation. *J Periodontol* 2005;76:1367-73.  
[PUBMED](#) | [CROSSREF](#)
  46. Fransson C, Tomasi C, Pikner SS, Gröndahl K, Wennström JL, Leyland AH, et al. Severity and pattern of peri-implantitis-associated bone loss. *J Clin Periodontol* 2010;37:442-8.  
[PUBMED](#) | [CROSSREF](#)
  47. Koldslund OC, Scheie AA, Aass AM. The association between selected risk indicators and severity of peri-implantitis using mixed model analyses. *J Clin Periodontol* 2011;38:285-92.  
[PUBMED](#) | [CROSSREF](#)
  48. Roos-Jansäker AM, Lindahl C, Renvert H, Renvert S. Nine- to fourteen-year follow-up of implant

- treatment. Part I: implant loss and associations to various factors. *J Clin Periodontol* 2006;33:283-9.  
[PUBMED](#) | [CROSSREF](#)
49. Roos-Jansåker AM, Renvert H, Lindahl C, Renvert S. Nine- to fourteen-year follow-up of implant treatment. Part III: factors associated with peri-implant lesions. *J Clin Periodontol* 2006;33:296-301.  
[PUBMED](#) | [CROSSREF](#)
50. Kozlovsky A, Tal H, Laufer BZ, Leshem R, Rohrer MD, Weinreb M, et al. Impact of implant overloading on the peri-implant bone in inflamed and non-inflamed peri-implant mucosa. *Clin Oral Implants Res* 2007;18:601-10.  
[PUBMED](#) | [CROSSREF](#)
51. Gotfredsen K, Berglundh T, Lindhe J. Bone reactions at implants subjected to experimental peri-implantitis and static load. A study in the dog. *J Clin Periodontol* 2002;29:144-51.  
[PUBMED](#) | [CROSSREF](#)
52. Chambrone L, Chambrone LA, Lima LA. Effects of occlusal overload on peri-implant tissue health: a systematic review of animal-model studies. *J Periodontol* 2010;81:1367-78.  
[PUBMED](#) | [CROSSREF](#)
53. Karoussis IK, Salvi GE, Heitz-Mayfield LJ, Bragger U, Hämmerle CH, Lang NP. Long-term implant prognosis in patients with and without a history of chronic periodontitis: a 10-year prospective cohort study of the ITI Dental Implant System. *Clin Oral Implants Res* 2003;14:329-39.  
[PUBMED](#) | [CROSSREF](#)
54. Sgolastra F, Petrucci A, Severino M, Gatto R, Monaco A. Periodontitis, implant loss and peri-implantitis. A meta-analysis. *Clin Oral Implants Res* 2015;26:e8-16.  
[PUBMED](#) | [CROSSREF](#)
55. Rocuzzo M, Bonino L, Dalmasso P, Aglietta M. Long-term results of a three arms prospective cohort study on implants in periodontally compromised patients: 10-year data around sandblasted and acid-etched (SLA) surface. *Clin Oral Implants Res* 2014;25:1105-12.  
[PUBMED](#) | [CROSSREF](#)
56. Sgolastra F, Petrucci A, Severino M, Gatto R, Monaco A. Smoking and the risk of peri-implantitis. A systematic review and meta-analysis. *Clin Oral Implants Res* 2015;26:e62-7.  
[PUBMED](#) | [CROSSREF](#)
57. Serino G, Ström C. Peri-implantitis in partially edentulous patients: association with inadequate plaque control. *Clin Oral Implants Res* 2009;20:169-74.  
[PUBMED](#) | [CROSSREF](#)
58. Pjetursson BE, Helbling C, Weber HP, Matuliene G, Salvi GE, Bragger U, et al. Peri-implantitis susceptibility as it relates to periodontal therapy and supportive care. *Clin Oral Implants Res* 2012;23:888-94.  
[PUBMED](#) | [CROSSREF](#)
59. Linkevicius T, Puisys A, Vindasiute E, Linkeviciene L, Apse P. Does residual cement around implant-supported restorations cause peri-implant disease? A retrospective case analysis. *Clin Oral Implants Res* 2013;24:1179-84.  
[PUBMED](#)
60. Fransson C, Lekholm U, Jemt T, Berglundh T. Prevalence of subjects with progressive bone loss at implants. *Clin Oral Implants Res* 2005;16:440-6.  
[PUBMED](#) | [CROSSREF](#)
61. Roos-Jansåker AM, Lindahl C, Renvert H, Renvert S. Nine- to fourteen-year follow-up of implant treatment. Part II: presence of peri-implant lesions. *J Clin Periodontol* 2006;33:290-5.  
[PUBMED](#) | [CROSSREF](#)
62. Koldslund OC, Scheie AA, Aass AM. Prevalence of peri-implantitis related to severity of the disease with different degrees of bone loss. *J Periodontol* 2010;81:231-8.  
[PUBMED](#) | [CROSSREF](#)
63. Zitzmann NU, Berglundh T. Definition and prevalence of peri-implant diseases. *J Clin Periodontol* 2008;35 Suppl:286-91.  
[PUBMED](#) | [CROSSREF](#)
64. Atieh MA, Alsabeeha NH, Faggion CM Jr, Duncan WJ. The frequency of peri-implant diseases: a systematic review and meta-analysis. *J Periodontol* 2013;84:1586-98.  
[PUBMED](#)
65. Gould TR, Westbury L, Brunette DM. Ultrastructural study of the attachment of human gingiva to titanium in vivo. *J Prosthet Dent* 1984;52:418-20.  
[PUBMED](#) | [CROSSREF](#)
66. Gens KD, Elshaboury RH, Holt JS. Fecal microbiota transplantation and emerging treatments for *Clostridium difficile* infection. *J Pharm Pract* 2013;26:498-505.  
[PUBMED](#) | [CROSSREF](#)