



Transoral-transpharyngeal CO₂ laser en bloc excision of voluminous left recurrent laryngeal nerve schwannoma: Case report and review of the literature

Cinzia Mariani¹ | Filippo Carta¹ | Daniele De Seta¹ | Ibragim I. Nazhmudinov² | Ismail G. Guseinov² | Kamilla M. Magomedova² | Natalia Chuchueva³ | Valeria Marrosu¹ | Roberto Puxeddu¹

¹Unit of Otorhinolaryngology, Department of Surgery, Azienda Ospedaliero-Universitaria di Cagliari, University of Cagliari, Cagliari, Italy

²The National Medical Research Center for Otorhinolaryngology, Federal Medico-Biological Agency of Russia, Moscow, Russia

³I. M. Sechenov First Moscow State Medical University, Moscow, Russia

Correspondence

Filippo Carta, Policlinico D. Casula, Department of Otorhinolaryngology, Azienda Ospedaliero-Universitaria, University of Cagliari - School of Medicine, SS 554 km 4,500, Monserrato (Cagliari), Italy.
Emails: filippocarta@unica.it

Abstract

Recurrent nerve laryngeal schwannoma is a rare benign tumor that, in expert hands, can be treated by transoral CO₂ laser surgery.

KEYWORDS

ear, nose and throat

1 | INTRODUCTION

Schwannomas are benign tumors arising from Schwann cells of cranial, peripheral, and autonomic nerves. The 25%-45% of all schwannomas occur in the head and neck region, but the laryngeal localization is rare.¹⁻³ They usually arise from branches of the superior laryngeal nerve, developing in the supraglottic region.^{4,5} Recurrent laryngeal nerve schwannomas are even more uncommon with only eight cases reported in the English literature.⁶⁻¹³

Recurrent laryngeal schwannomas usually present as insidious, slow-growing, submucosal masses located in the posterior paraglottic space, clinically associated with dysphagia,

dysphonia, dyspnea, or stridor. Preoperative diagnosis is possible on the basis of clinical findings and imaging.

Radical surgical excision with minimal injury to uninvolved surrounding areas is considered the treatment of choice, but there are currently no guidelines. The external approach is the most widely described technique for large lesions, while the endoscopic management, with or without laser, is generally proposed for smaller tumors confined in the glottic or supraglottic region.^{4,5,14}

The authors report a case of transoral-transpharyngeal CO₂ laser en bloc excision of a voluminous schwannoma of the intralaryngeal portion of the recurrent laryngeal nerve, along with the review of the pertinent literature.

Mariani and Carta have contributed equally to the manuscript.

This is an open access article under the terms of the Creative Commons Attribution-NonCommercial-NoDerivs License, which permits use and distribution in any medium, provided the original work is properly cited, the use is non-commercial and no modifications or adaptations are made.

© 2020 The Authors. *Clinical Case Reports* published by John Wiley & Sons Ltd

2 | CASE REPORT

A 43-year-old man was referred to the Research and Clinical Center of Otorhinolaryngology of the Russian Federal Medico-Biological Agency with an 8-month history of dysphonia and dysphagia. Fibrolaryngoscopy showed a smooth submucosal swelling of the left pyriform sinus, associated with immobility of the left vocal cord (Figure 1). Computed tomography (CT) of the neck showed a lesion in the left pyriform sinus extending into the ipsilateral paraglottic space (Figure 2). Clinical and radiological features suggested its benign nature, and the patient's anatomy did not contraindicate a favorable endoscopic exposure.

The patient underwent transoral laser excision under general anesthesia.

Surgical steps.

1. The patient was intubated with a Mallinckrodt laser-safe tube 5.5.
2. During direct microlaryngoscopy, with the patient in the “sniffing” Boyce-Jackson position (neck flexion and head extension), the bivalve laryngoscope offered a wide exposure of the pharyngo-larynx. A laser dedicated Steiner Distending Operating Laryngoscope was used with the Gottingen Laryngoscope Holder and Chest Support (Karl Storz Se & Co. KG).
3. CO₂ laser AcuPulse 40 ST (Lumenis) was set on 10 Watts, continuous wave in Superpulsed mode/emission, Acu-Blade 2 mm of length.
4. Surgery started with the incision of the mucosa of the left pyriform sinus overlying the tumor.
5. A careful laser resection with blunt dissection from the surrounding structures was performed preserving the capsule, until to achieve the caudal aspect of the tumor.

6. The ultimate release of the tumor was obtained by the use of a thin cotton loop allowing for the hanging of the mass and its en bloc removal.
7. Hemostasis was performed by monopolar cautery.

The tumor appeared as an oval mass of 30 mm in greatest dimension (Figure 3). After the excision, the surgical wound of the pyriform sinus was left to heal by secondary intention. Tracheostomy was not performed, but the patient was kept intubated in Intensive Care Unit (ICU) during the first 12 hours after surgery. Naso-gastric feeding tube (NGT) was used for 4 days after surgery, and then, oral feeding was regained. There were no complications, and the patient was discharged 7 days after surgery. The paralysis of the left vocal cord in median position, already observed at diagnosis, did not improve during the follow-up, suggesting the origin of the tumor from the intralaryngeal portion of the recurrent nerve. At histology, typical morphologic features of schwannoma (clear capsule, presence of Antoni A and/or B areas and a positive reaction for S-100 protein) were present¹⁵ (Figures 4 and 5). At 4 years of follow-up, there was no evidence of recurrence.

3 | DISCUSSION

Supraglottic localization of laryngeal schwannomas is the most frequently reported in literature,^{5,14} and it is generally managed by an endoscopic approach.

The nerve of origin is difficult to be identified precisely before and during surgery. The origin from the intralaryngeal portion of the recurrent nerve is extremely rare, probably because of its shortness,¹⁶ and, as shown in Table 1, only eight authors theorized the origin of the laryngeal schwannoma from the recurrent nerve.⁶⁻¹³

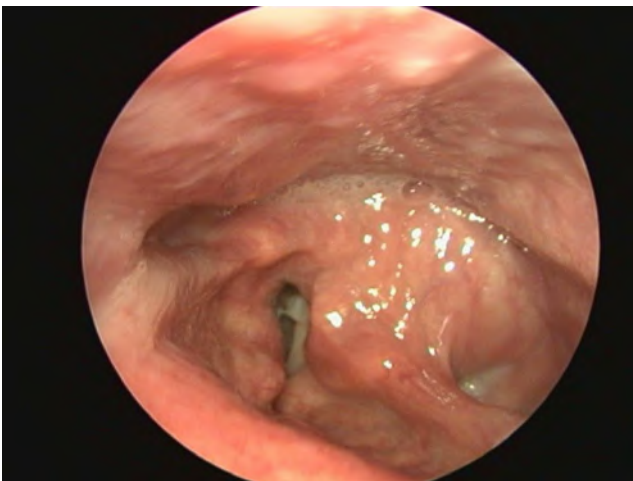


FIGURE 1 Endoscopic view showing a large submucosal lesion originating from the left pyriform sinus

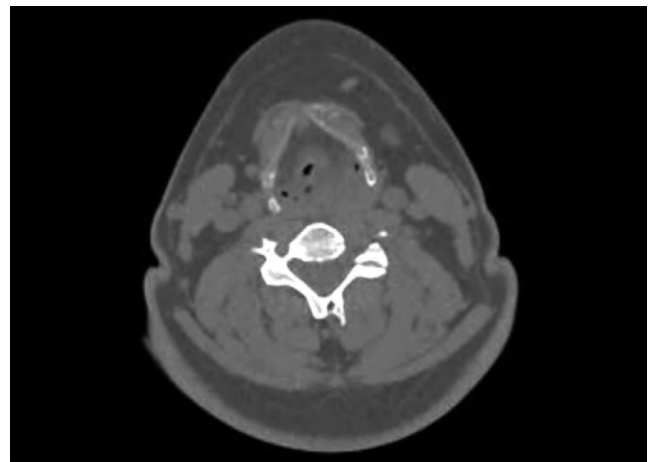


FIGURE 2 Computed tomography scan of the neck showing an oval mass located in the left pyriform sinus and extending into the ipsilateral paraglottic space

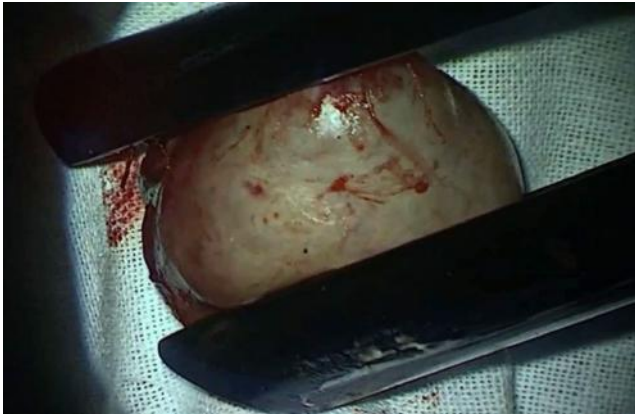


FIGURE 3 Tumor engaged in the Steiner laryngoscope

Schwannoma of the recurrent nerve is suspected in patients with a submucosal well capsulated tumor originating from the paraglottic space, especially when associated with vocal cord palsy. However, preoperative vocal cord palsy can be observed both when the tumor causes a compression of the recurrent laryngeal nerve and/or a mass effect to the cricoarytenoid joint (so-called pseudo-fixation),² and when the schwannoma originates from the recurrent laryngeal nerve.¹⁴ After surgery, the persistence of the preoperative vocal fold palsy confirms the origin of the tumor from the recurrent nerve, while in case of recovery of the palsy the mass was probably originating from another nerve.

Differential diagnosis includes other benign neoplastic and non-neoplastic laryngeal lesions that can arise from the paraglottic space (neurofibroma, lipoma, adenoma, chondroma, papilloma, paraganglioma, internal laryngocele, ectopic thyroglossal duct cyst, laryngeal cyst).⁴

The surgical resection of the mass with minimal injury of uninvolved areas is the treatment of choice because these

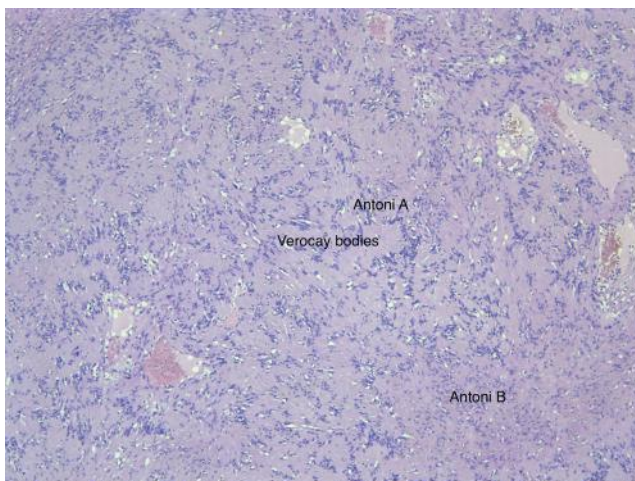


FIGURE 4 5X histological image of the Schwannoma that shows classic variable cellularity: hypercellular areas (Antoni A) with distinctive focal nuclear palisading surrounding aggregates of cellular processes (Verocay bodies) and hypocellular areas (Antoni B)

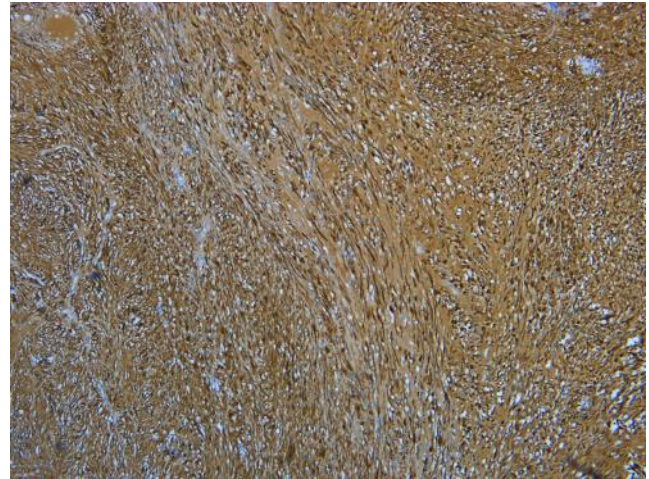


FIGURE 5 5X histological image of the Schwannoma: the tumor cells show strong and diffuse staining for S100 protein

tumors are radioresistant.² Surgery can be performed by an open approach or by an endoscopic one. The choice of the surgical approach is based on the tumor's size, the site of origin, patients' characteristics, and surgeon's skills.

Open approach can be done by median thyrotomy, lateral thyrotomy, and lateral pharyngotomy.¹⁴

Five authors^{6-9,13} choose this approach because it allows a wide exposure of the lesion for a complete en bloc removal. The morbidity of the open approach varies noticeably. The laryngeal mucosa could be spared minimizing complication and improving the postoperative voice recovery,^{2,17} but in one case a total laryngectomy was considered necessary.

Transoral endoscopic microsurgery, with or without the use of laser, is traditionally reserved to small glottic and supraglottic schwannomas, in patients with good pharyngo-laryngeal exposure.^{4,5,14} The advantages of the technique are less morbidity, the absence of scar in the neck, and shorter hospitalization time. However, some authors believe that the endoscopic approach could be associated with an increased risk of residual disease because of nonoptimal exposure of the mass.¹⁴

The endoscopic approach for recurrent nerve laryngeal schwannoma has been previously reported in three cases only.¹⁰⁻¹² In two patients, the tumor involved the glottis and the paraglottic space, and in the other case, it involved the aryepiglottic fold and the pyriform sinus.

As shown in Table 1, open and endoscopic approaches showed some difference in the radicality of resection. Residual disease was observed in one case treated by open approach (20%),⁹ while persistence of the tumor was reported in two cases treated endoscopically (50%)^{11,12} (*P*-value of .342782 according to the chi-square test). Radicality is then related to a wide exposure of the surgical area and the ability to control the inferior aspect of the lesion while working in a narrow lumen. The endoscopic approach should be performed

TABLE 1 Reported cases of laryngeal schwannoma originating from the recurrent nerve

Author (year)	Sex/age	Location	Presenting symptoms	Extra-laryngeal lesions	Tumor max dimension	Hypothetical nerve of origin	Surgical approach	Persistent disease or relapse
Jamal (1994)	M/42	Emilarynx with extralaryngeal extension	Dyspnea	No	4 cm	Recurrent nerve	Open approach, tracheostomy	No
Plantet (1995)	M/30	Aryepiglottic fold extending to paraglottic region	Cervical mass, dysphagia, dysphonia	Yes NF2	-	Recurrent nerve	Lateral pharyngotomy	-
Lone (2004)	M/80	Subglottic region extending to trachea	Hoarseness, dyspnea	No	5 cm	Recurrent nerve	Median thyrotomy, tracheostomy	No
Nagato (2010)	M/38	Aryepiglottic fold extending to arytenoids, cricoid and mediastinum	Throat discomfort, dyspnea	Yes NF2	-	Recurrent nerve	Open approach, tracheostomy	Yes
Kharytaniuk (2014)	M/30	True vocal cord extending to paraglottic space	Hoarseness	No	2 cm	Superior laryngeal nerve or Recurrent nerve	Microsurgery	No
Wang (2014)	F/29	Aryepiglottic fold extending to pyriform sinus	Hoarseness, dyspnea, dysphagia	No	5.8 cm	Recurrent nerve	Microsurgery	Yes
Kennedy (2015)	F/68	True vocal cord extending to false vocal cord and paraglottic space	Hoarseness, dysphagia	No	2.4 cm	Recurrent nerve	Microsurgery	Yes
Kamble (2017)	F/27	Aryepiglottic fold extending to true vocal cord and cricoid	Hoarseness, exertional dyspnea	No	5 cm	Recurrent nerve	Total laryngectomy	No
Present case	M/43	Pyriform sinus extending to the paraglottic space	Dysphonia, dysphagia	No	3 cm	Recurrent nerve	Microsurgery (CO ₂ laser)	No

Abbreviation: NF2, Neurofibromatosis type 2.

by surgeons with good expertise in both transoral and open procedures since during surgery the surgeon should be able to shift the endoscopy to an open procedure if he/she is not certain about the radicality of the technique, and in case of complications. Although wider lesions could require the external approach, a transoral management could be considered after precise counseling with the patient. In the present case, the transoral laser CO₂ assisted excision was performed in avoluminous schwannoma and resulted an optimal treatment in terms of radicality of the resection and low morbidity. The key points of the management were the good transoral exposure of the mass, a meticulous smooth dissection of the capsule avoiding remaining of the tumor, minimal injury to the surrounding areas to reduce the risk of postoperative edema/bleeding, and the ultimate release of the tumor obtained by a cotton loop.

Tracheostomy can be necessary preoperatively in case of airway obstruction,⁸ and after surgery to avoid life-threatening complications. In literature, tracheostomy was performed in 60% of the open procedures, while it has never been performed in patients treated endoscopically for recurrent laryngeal nerve schwannomas. In our case, the tracheostomy was not considered necessary, but the patient was kept intubated in ICU during the first postoperative hours under steroid therapy, and the endotracheal tube was removed the day after surgery under endoscopic view.

4 | CONCLUSIONS

Recurrent nerve laryngeal schwannoma is a rare benign tumor that should be considered in the differential diagnosis of all submucosal pharyngo-laryngeal lesions. Although “challenging,” in expert hands transoral CO₂ laser enucleation allows for the radical resection with low morbidity even for bigger tumors.

Since the histology of the lesion is benign, a conservative and mini-invasive approach should be considered as an alternative to open surgery, without excluding the open approach in case of failure to obtain the radical excision or in case of intraoperative complications such uncontrolled bleeding.

ACKNOWLEDGMENTS

None. Published with written consent of the patient.

CONFLICT OF INTEREST

The authors declare no conflicts of interest.

AUTHOR CONTRIBUTIONS

CM and FC: wrote the manuscript. IIN, IGG, KMM, and NC: involved in patient management. DDS and VM: provided editing and review of the manuscript. RP: involved in patient

management and provided editing and review of the manuscript. All authors: reviewed and contributed to the present form of the manuscript.

ORCID

Cinzia Mariani  <https://orcid.org/0000-0002-8887-0435>
 Filippo Carta  <https://orcid.org/0000-0003-0125-6588>
 Daniele De Seta  <https://orcid.org/0000-0003-2286-7265>
 Ibragim I. Nazhmudinov  <https://orcid.org/0000-0002-4302-5203>
 Ismail G. Guseinov  <https://orcid.org/0000-0003-0021-2049>
 Kamilla M. Magomedova  <https://orcid.org/0000-0003-2381-7817>
 Natalia Chuchueva  <https://orcid.org/0000-0001-9929-2506>
 Valeria Marrosu  <https://orcid.org/0000-0001-5054-7424>
 Roberto Puxeddu  <https://orcid.org/0000-0003-2829-0583>

REFERENCES

- Zbären P, Markwalder R. Schwannoma of the true vocal cord. *Otolaryngol Head Neck Surg.* 1999;121:837-839.
- Rosen FS, Pou AM, Quinn FB. Obstructive supraglottic schwannoma: a case report and review of the literature. *Laryngoscope.* 2002;112:997-1002.
- Cadoni G, Bucci G, Corina L, et al. Schwannoma of the larynx presenting with difficult swallowing. *Otolaryngol Head Neck Surg.* 2000;122:773-774.
- Tulli M, Bondi S, Bussi M. Voluminous laryngeal schwannoma excision with a mini-invasive external approach: a case report. *Acta Otorhinolaryngol Ital.* 2017;37:242-244.
- Wong BLK, Bathala S, Grant D. Laryngeal schwannoma: a systematic review. *Eur Arch Otorhinolaryngol.* 2017;274(1):25-34.
- Jamal MN. Schwannoma of the larynx: case report, and review of the literature. *J Laryngol Otol.* 1994;108:788-790.
- Plantet MM, Hagay C, De Maulmont C, et al. Laryngeal schwannomas. *Eur J Radiol.* 1995;21:61-66.
- Lone SA, Khan MA, Lateef M, Ahmad R. Sub Glottic Schwannoma of the Larynx. *JK Sci.* 2004;6:46-47.
- Nagato T, Katada A, Yoshizaki T, et al. Laryngeal plexiform schwannoma as first symptom in a patient with neurofibromatosis type 2. *Clin Neurol Neurosurg.* 2010;112:505-508.
- Kharytaniuk N. Beware: unilateral Reinke's oedema of the larynx. *Ir Med J.* 2014;107:153-154.
- Wang B, Dong P, Shen B, Xu H, Zheng J. Laryngeal schwannoma excised under a microlaryngoscope without tracheotomy: a case report. *Exp Ther Med.* 2014;7:1020-1022.
- Kennedy WP, Brody RM, LiVolsi VA, Wang AR, Mirza NA. Trauma-induced schwannoma of the recurrent laryngeal nerve after thyroidectomy. *Laryngoscope.* 2016;126(6):1408-1410.
- Kamble BB, Deshmukh P, Methwani D, Lakhotia P. A rare case of laryngeal Schwannoma. *Ann Clin Case Rep.* 2017;2:1364.
- Tulli M, Bondi S, Smart CE, et al. Diagnosis and treatment of laryngeal schwannoma: a systematic review. *Otolaryngol Head Neck Surg.* 2018;158(2):222-231.

15. Enzinger FM, Weiss SW. Benign tumors of the peripheral nerves. In: Enzinger FM, Weiss SW, eds. *Soft tissue tumors*. St Louis: Mosby; 1988:725-735.
16. Fini-Storchi I, Frosini P. Laryngeal neurinoma: a case report and review. *ORL J Otorhinolaryngol Relat Spec*. 1997;59:182-185.
17. Cohen S, Sinacori JT, Courey MS. Laryngeal schwannoma: diagnosis and management. *Otolaryngol Head Neck Surg*. 2004;130:363-365.

How to cite this article: Mariani C, Carta F, De Seta D, et al. Transoral-transpharyngeal CO₂ laser en bloc excision of voluminous left recurrent laryngeal nerve schwannoma: Case report and review of the literature. *Clin Case Rep*. 2020;00:1–6. <https://doi.org/10.1002/ccr3.3372>