

Kikuchi-Fujimoto disease associated with hemophagocytic lymphohistiocytosis following the BNT162b2 mRNA COVID-19 vaccination

by Giovanni Caocci , Daniela Fanni, Mariagrazia Porru, Marianna Greco, Sonia Nemolato, Davide Firinu, Gavino Faa, Angelo Scuteri, and Giorgio La Nasa

Received: October 25, 2021.

Accepted: December 20, 2021.

Citation: Giovanni Caocci , Daniela Fanni, Mariagrazia Porru, Marianna Greco, Sonia Nemolato, Davide Firinu, Gavino Faa, Angelo Scuteri, and Giorgio La Nasa. Kikuchi-Fujimoto disease associated with hemophagocytic lymphohistiocytosis following the BNT162b2 mRNA COVID-19 vaccination. *Haematologica*. 2021 Dec 30. doi: 10.3324/haematol.2021.280239. [Epub ahead of print]

Publisher's Disclaimer.

E-publishing ahead of print is increasingly important for the rapid dissemination of science. *Haematologica* is, therefore, E-publishing PDF files of an early version of manuscripts that have completed a regular peer review and have been accepted for publication. E-publishing of this PDF file has been approved by the authors. After having E-published Ahead of Print, manuscripts will then undergo technical and English editing, typesetting, proof correction and be presented for the authors' final approval; the final version of the manuscript will then appear in a regular issue of the journal. All legal disclaimers that apply to the journal also pertain to this production process.

Letter to the editor

Kikuchi-Fujimoto disease associated with hemophagocytic lymphohistiocytosis following the BNT162b2 mRNA COVID-19 vaccination

Giovanni Caocci¹, Daniela Fanni², Mariagrazia Porru³, Marianna Greco¹, Sonia Nemolato², Davide Firinu³, Gavino Faa², Angelo Scuteri³, Giorgio La Nasa¹

1 Department of Medical Sciences and Public Health, Haematology, University of Cagliari, Businco Hospital, Cagliari, Italy

2 Department of Medical Sciences and Public Health, Pathology, University of Cagliari, S.Giovanni di Dio and Businco Hospital, Cagliari, Italy

3 Department of Medical Sciences and Public Health, Internal Medicine, University of Cagliari, Policlinico Hospital, Cagliari, Italy

Running Title: Kikuchi with HLH after COVID-19 vaccine

Text word count: 1149

Figures: 2

Number of references: 12

Correspondence to: Giovanni Caocci

SC Ematologia e CTMO, Ospedale Businco, Dipartimento di Scienze Mediche e Sanità Pubblica, Università di Cagliari

Via Jenner, sn

09124 Cagliari, Italy

Tel. +39-70-52964901

Fax. +39-70-52965317

E-mail address: giovanni.caocci@unica.it

Acknowledgment: we thank Dr. Mariano Cabiddu and Dr. Giovanna Manconi for patient management in early phases; Prof. Fabio Medas for performing lymph node biopsy, Dr. Salvatore Labate for CT images and Dr. Valeria Fresu for interleukin analysis.

Compliance with Ethical Standards: All procedures performed in studies involving human participants were in accordance with the ethical standards of the institutional and/or national research committee and with the 1964 Helsinki declaration and its later amendments or comparable ethical standards

Funding: none

Conflict of interest:

Caocci G. declares that he has no conflict of interest; Fanni D declares that she has no conflict of interest, Porru MG declares that she has no conflict of interest, Greco M. declares that she has no conflict of interest; Nemolato S. declares that she has no conflict of interest; Firinu D. declares that he has not conflict of interest; Faa G. declares that he has no conflict of interest; Scuteri A. declares that he has no conflict of interest; La Nasa G. declares that he has no conflict of interest

Informed consent: informed consent was obtained from the patient, including personal images publication.

Author contribution

Conception and design: GC, GF, AS, GLN

Patient management: GC, MP, DF, AS, GLN

Pathologist analysis: DF, SN, GF

Immunophenotype and interleukin analysis: MG

Manuscript writing: GC

Final approval of the manuscript: GC, DF, MP, DF, MG, SN, GF, AS, GLN

Data sharing

The data that support the findings of this study are available from the corresponding author upon reasonable request

Dear Editor,

Kikuchi-Fujimoto disease (KD) is a self-limiting histiocytic necrotizing lymphadenitis. A case of KD following administration of the BNT162b2 mRNA COVID-19 vaccine was recently reported (1). Hemophagocytic lymphohistiocytosis (HLH) is a life-threatening hyperinflammatory state, brought on by uncontrolled histiocytes, macrophages and T-cell activation, which have also been occasionally observed after BNT162b2 vaccination (2). KD and HLH present overlapping pathogenesis and symptoms, and their association has been previously described in children and adult patients (3)(4). Here, we report the first case of KD associated with HLH following the BNT162b2 mRNA COVID-19 vaccination.

A 38-year-old previously healthy woman was admitted to the hospital with a history of a fever of 40° C for more than 10 days, associated with chills and fatigue. She presented with a diffuse cutaneous eruption of erythematous papules, that were subsequently confluent (Figure 1 A-B). She was previously treated with antibiotics (amoxicillin and clavulanic acid, followed by teicoplanin and doxycycline), with no improvement. The first dose of the vaccine was administered two months after giving birth to a healthy baby. Three weeks before the onset of fever, the patient received a second dose of the BNT162b2 mRNA COVID-19 vaccine, inoculated in the same left arm as the first dose. At hospital admission, her nasopharyngeal swab for SARS CoV-2 PCR was negative; SARS CoV-2 IgG antibodies were positive (>2.080 BAU/mL; cut-off: 33.8 BAU/mL; LIAISON SARS-CoV-2 TrimericS IgG, Diasorin, Saluggia, Italy).

Her physical exam was normal except for the cutaneous rash and multiple enlarged tender lymph nodes in the left axillary zone, confirmed by a contrast-enhanced computed tomography (CT) exam (Figure 1, C-D).

Laboratory tests showed bi-cytopenia with leukopenia and anemia (neutrophil count, $0.9 \times 10^9/L$; lymphocyte count, $0.3 \times 10^9/L$, hemoglobin, 9.8 g/L), increased lactate dehydrogenase and transaminase levels, high serum ferritin levels (500 $\mu\text{g/L}$), mild hypertriglyceridemia (225 mg/dL) and normal fibrinogen. Her serum soluble interleukin-2 receptor (IL-2R) level was increased to

2.610 U/mL (normal value 223-710) and her natural killer (NK) cell count was low (<35 cells/ μ L, normal value 200-400). IL-6, IL-8 and IL-10 levels were normal, but the tumor necrosis factor (TNF) level was increased. The patient underwent a bone marrow aspiration and trephine procedure, which showed hemophagocytosis (Figure 2, A-C). A diagnosis of HLH was confirmed based on the fulfilment of six out of eight criteria HLH-2004 diagnostic criteria (5). An excisional lymph node biopsy of the left axillary was additionally performed. Histopathological examination of the lymph node revealed histiocytic necrotizing lymphadenitis, characterized by paracortical, well-circumscribed necrotic areas with karyorrhexis and fibrin deposits. Immunohistochemistry revealed numerous CD68-positive histiocytes as well as several CD3-positive T cells and few CD20-positive B cells. All these features are considered typical of KD (Figure 2, D-F).

Further analysis did not show ongoing infections of HCV, HBV hepatitis virus, HIV, Toxoplasma, Rubivirus, Brucella, Leptospirosis, Bartonella, Chlamydia, Morbillivirus, Mycoplasma or Yersinia. The tuberculosis Quantiferon test was also negative. Epstein Barr virus (EBV), Parvovirus B19, Cytomegalovirus, JC virus and Herpes-6 DNA were also absent. Antinuclear antibodies (ANA), antibodies to double-stranded DNA (anti-dsDNA), and antibodies to extractable nuclear antigens (anti-ENA) were absent, and rheumatoid factor test was negative. Both complement C3 and C4 serum levels were normal.

The patient was promptly initiated on steroids (methylprednisolone 1 mg/kg i.v.), according to the recommended treatment for HLH. Sudden fever lysis was observed and clinical conditions improved. Methyl-prednisone was substituted with prednisone (1 mg/day) at hospital discharge 1 week later. This schedule was maintained for a further 2 weeks, changed to half dosage for 3 more weeks, then tapered in the following 3 weeks. IL-2R levels decreased to 1.170 U/mL and 740 U/mL after 2 and 3 weeks of steroid treatment, respectively, and reached normal levels (460 U/mL) after 4 weeks. NK cells also returned to normal levels. The patient is doing well and follow-up is still ongoing.

To the best of our knowledge, this is the first case of KD associated with HLH following COVID-19 vaccination. HLH is a severe hyperinflammatory syndrome, secondary to aberrant cytokine production and uncontrolled histiocyte activation, following infections, in particular EBV, hematological malignancies, autoimmune diseases, hematopoietic stem cells or organ transplantation. It is characterized by cytopenia, unremitting fever, hepatic dysfunction and a fatal multiple organ failure without early recognition and prompt treatment. First line of treatment is steroids and or immunoglobulins, with added etoposide in poor responders (5). KD is a self-limiting histiocytic necrotizing lymphadenitis that commonly occurs in Asia, although it is present globally (6). It is characterized by fever, lymphadenopathy and leukopenia, may be associated with a skin rash, and is mainly characterized by transient red, millet-sized maculopapules (7). Since no skin biopsy was done, it remains unclear whether the skin rash was associated with KD or represented a possible adverse effect of teicoplanin (Figure 1 A-B). KD pathogenesis is unknown, although it is believed to be a consequence of an aberrant immune response of T cells and histiocytes to an immunogenic antigen. An association with organisms such as Toxoplasma, Cytomegalovirus, Varicella-Zoster virus, EBV, Human Herpes virus-6, HIV, and Yersinia enterocolitica, has been suggested, even without convincing evidence. Moreover, a possible association with autoimmune disorders, including antiphospholipid antibody syndrome and mixed connective tissue disease, has been reported (1). Steroids and immunoglobulins treatment may be beneficial. The association between HLH and KD has been described in both children and adults patients and has a potentially fatal outcome if left untreated (3)(4)(8). Some authors reported that that CD8+ T lymphocytes in patients with HLH-KD may be excessively activated, altering the course of the self-limited KD progress and resulting in HLH (8).

Both HLH and KD have recently been described after the BNT162b2 mRNA COVID-19 vaccination (1)(2). Notably, after the mass vaccination against COVID-19, a vaccine-associated hypermetabolic lymphadenopathy (VAHL) in the axillary or supraclavicular lymph nodes, ipsilateral to the vaccination site, has been reported (9)(10)(11). This is frequently observed after

BNT162b2 administration, with higher intensities following the booster dose, and lasting until 3 weeks after vaccination. We hypothesize that our patient first developed a left-axillary VHAL following two ipsilateral vaccine dose inoculations, followed by a systemic inflammatory response syndrome (SIRS) with KD features in the axillary lymph nodes, and HLH symptoms as a systemic inflammatory reaction. Dermal histiocytes and macrophages represent the first resident antigen-presenting cell (APC) transfected by the mRNA vaccine that presents antigenic peptides on major histocompatibility (MHC) class I and MHC class II molecules of CD4+ and CD8+ cells, resulting in immune response expansion. Additionally, intramuscular vaccine injection leads to a local increase in proinflammatory cytokines, which forming an immune-stimulatory environment in draining axillary lymph nodes (12). It remains unclear whether an alternate arm inoculation in our patient might have been less immune-reactive.

In conclusion, we described the first case of KD associated with HLH following COVID-19 vaccination. This is a rare event and does not compromise the safety and efficacy of the BNT162b2 mRNA vaccine in the fight against COVID-19. Physicians should be aware of rare systemic inflammatory reactions that require an early diagnosis and treatment.

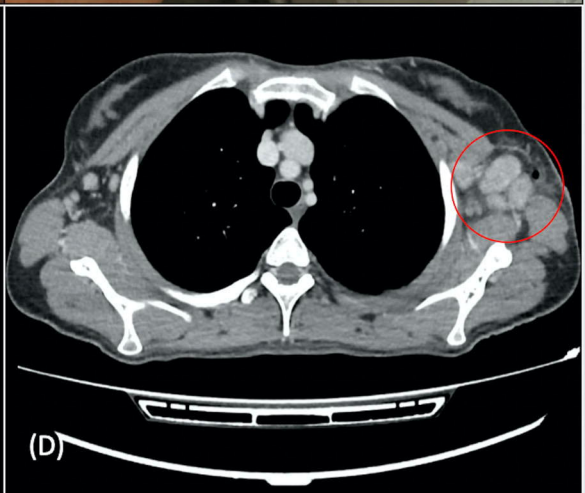
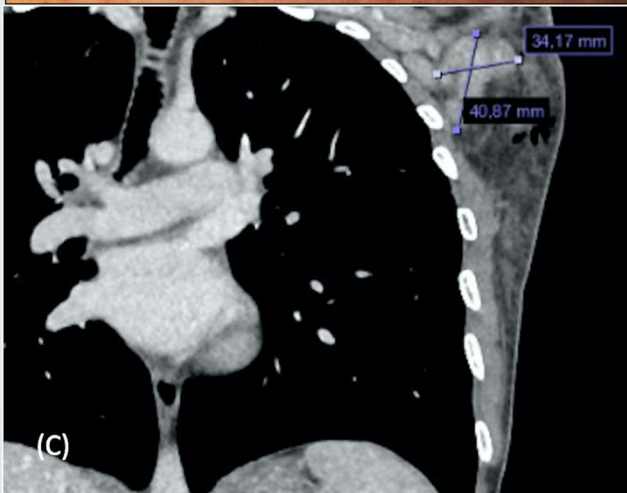
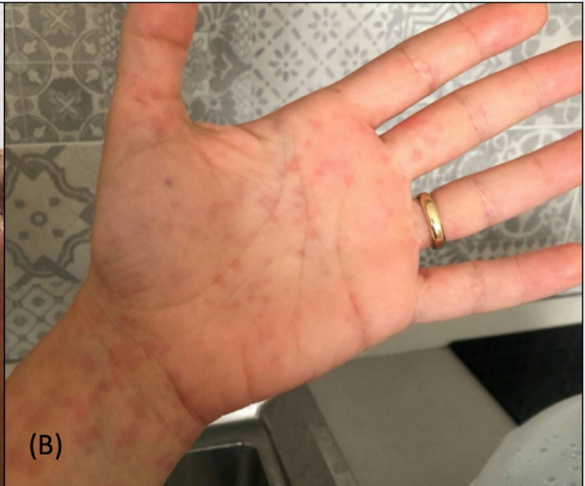
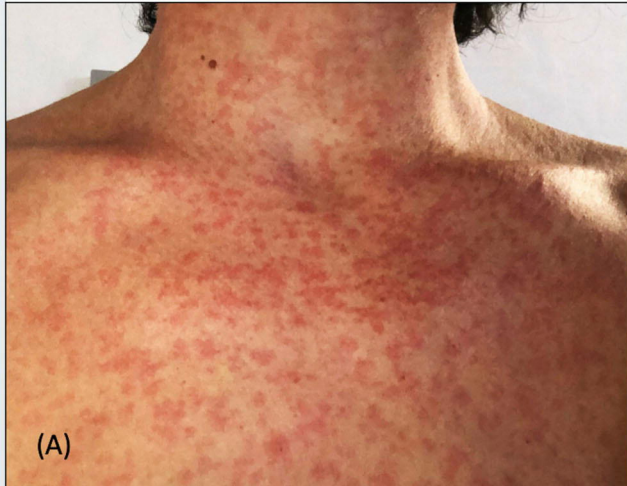Reference

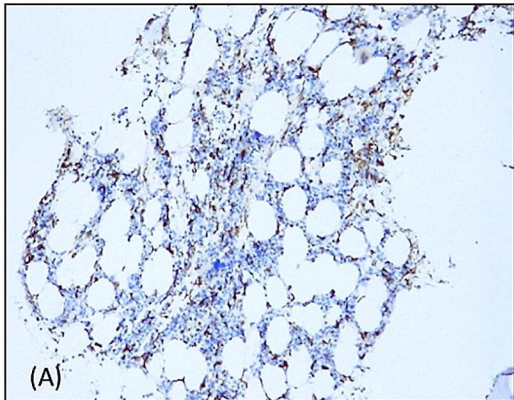
1. Soub HA, Ibrahim W, Maslamani MA, A Ali G, Ummer W, Abu-Dayeh A. Kikuchi-Fujimoto disease following SARS CoV2 vaccination: Case report. *IDCases*. 2021;25:e01253.
2. Tang LV, Hu Y. Hemophagocytic lymphohistiocytosis after COVID-19 vaccination. *J Hematol Oncol*. 2021;14(1):87.
3. Nishiwaki M, Hagiya H, Kamiya T. Kikuchi-Fujimoto Disease Complicated with Reactive Hemophagocytic Lymphohistiocytosis. *Acta Med Okayama*. 2016;70(5):383-388.
4. Duan W, Xiao Z-H, Yang L-G, Luo H-Y. Kikuchi's disease with hemophagocytic lymphohistiocytosis: A case report and literature review. *Medicine (Baltimore)*. 2020;99(51):e23500.
5. Henter J-I, Horne A, Aricó M, et al. HLH-2004: Diagnostic and therapeutic guidelines for hemophagocytic lymphohistiocytosis. *Pediatr Blood Cancer*. 2007;48(2):124-131.
6. Perry AM, Choi SM. Kikuchi-Fujimoto Disease: A Review. *Arch Pathol Lab Med*. 2018;142(11):1341-1346.
7. Resende C, Araújo C, Duarte M da L, Vieira AP, Brito C. Kikuchi's disease of the xanthomathous type with cutaneous manifestations. *An Bras Dermatol*. 2015;90(2):245-247.
8. Yang Y, Lian H, Ma H, et al. Hemophagocytic Lymphohistiocytosis Associated with Histiocytic Necrotizing Lymphadenitis: A Clinical Study of 13 Children and Literature Review. *J Pediatr*. 2021;229:267-274.
9. Cohen D, Krauthammer SH, Wolf I, Even-Sapir E. Hypermetabolic lymphadenopathy following administration of BNT162b2 mRNA Covid-19 vaccine: incidence assessed by [18F]FDG PET-CT and relevance to study interpretation. *Eur J Nucl Med Mol Imaging*. 2021;48(6):1854-1863.
10. Steinberg J, Thomas A, Iravani A. 18F-fluorodeoxyglucose PET/CT findings in a systemic inflammatory response syndrome after COVID-19 vaccine. *Lancet*. 2021;397(10279):e9.
11. Adin ME, Isufi E, Kulon M, Pucar D. Association of COVID-19 mRNA Vaccine With Ipsilateral Axillary Lymph Node Reactivity on Imaging. *JAMA Oncol*. 2021;7(8):1241-1242.
12. Mascellino MT, Di Timoteo F, De Angelis M, Oliva A. Overview of the Main Anti-SARS-CoV-2 Vaccines: Mechanism of Action, Efficacy and Safety. *Infect Drug Resist*. 2021;14:3459-3476.

Figure legends

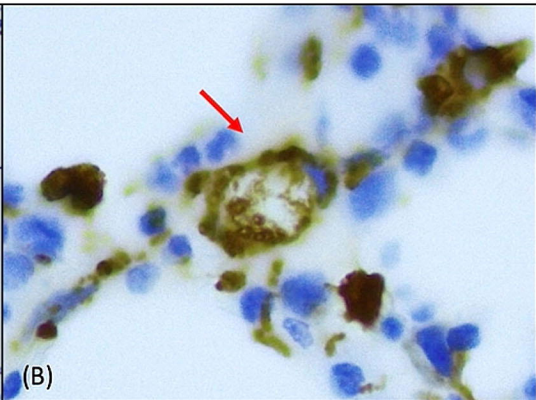
Figure 1. Patient's clinical and radiological findings. **A and B)** Diffuse maculo-papular skin rash; **C and D)** CT scan showing left axillary lymph nodes enlargement.

Figure 2. Lymph node and bone marrow histological findings. **A)** Increased diffusion of histiocytes (brown color) in the bone marrow trephine biopsy; CD68 (PGM1) stain, 10X magnification; **B)** An histiocyte showing phagocytosis of hemopoietic elements; CD68 (PGM1) stain, 60X magnification; **C)** Histiocytes showing phagocytosis of red cells, platelets, erythroid precursor cells; hematoxylin-eosin stain, 60X magnification; **D)** A low power view of the lymph node showing paracortical necrotizing zones (N) in an otherwise preserved architecture; hematoxylin-eosin stain; **E)** The paracortical necrotizing areas were characterized by many reactive T lymphocytes, as showed by immunohistochemistry for CD3; 10X magnification; **F)** The immunostaining for CD68 revealed numerous histiocytes within the necrosis; 10X magnification.

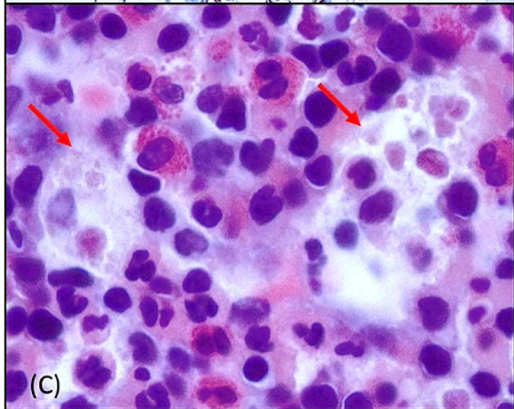




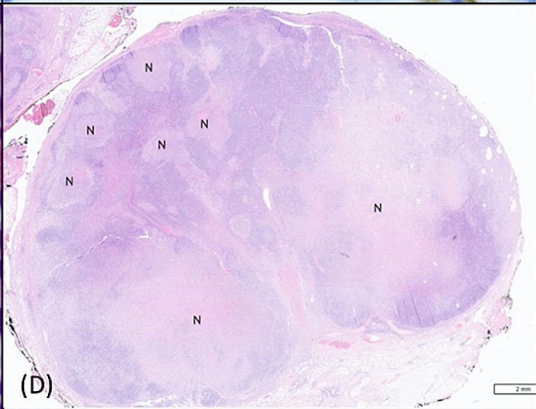
(A)



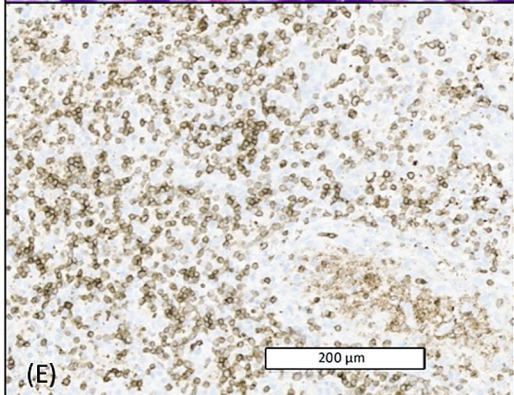
(B)



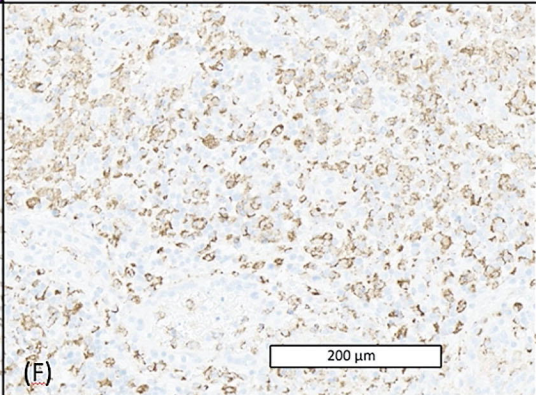
(C)



(D)



(E)



(F)