

Secukinumab for the treatment of palmoplantar psoriasis: a 2-year, multicenter, real-life observational study

Marco Galluzzo, Marina Talamonti, Laura Atzori, Federico Bardazzi, Anna Campanati, Antonella Di Cesare, Federico Diotallevi, Maria Laura Flori, Cristina Mugheddu, Annamaria Offidani, Stefano Piaserico, Filomena Russo, Lidia Sacchelli, Luca Bianchi & Francesca Prignano

To cite this article: Marco Galluzzo, Marina Talamonti, Laura Atzori, Federico Bardazzi, Anna Campanati, Antonella Di Cesare, Federico Diotallevi, Maria Laura Flori, Cristina Mugheddu, Annamaria Offidani, Stefano Piaserico, Filomena Russo, Lidia Sacchelli, Luca Bianchi & Francesca Prignano (2022): Secukinumab for the treatment of palmoplantar psoriasis: a 2-year, multicenter, real-life observational study, Expert Opinion on Biological Therapy, DOI: [10.1080/14712598.2022.2029841](https://doi.org/10.1080/14712598.2022.2029841)

To link to this article: <https://doi.org/10.1080/14712598.2022.2029841>



© 2022 The Author(s). Published by Informa UK Limited, trading as Taylor & Francis Group.



Published online: 20 Jan 2022.



Submit your article to this journal [↗](#)



Article views: 767



View related articles [↗](#)



View Crossmark data [↗](#)

Secukinumab for the treatment of palmoplantar psoriasis: a 2-year, multicenter, real-life observational study

Marco Galluzzo ^{a*}, Marina Talamonti ^{a*}, Laura Atzori ^b, Federico Bardazzi^c, Anna Campanati ^d, Antonella Di Cesare^e, Federico Diotallevi^d, Maria Laura Flori^f, Cristina Mugheddu^b, Annamaria Offidani^d, Stefano Piaserico^g, Filomena Russo^f, Lidia Sacchelli ^c, Luca Bianchi ^{a*} and Francesca Prignano^{e*}

^aDermatology Unit, Department of Systems Medicine, University of Rome "Tor Vergata", Rome, Italy; ^bSection of Dermatology, Department of Medical Sciences and Public Health, University of Cagliari, Cagliari, Italy; ^cDermatology Division, Department of Experimental, Diagnostic and Specialty Medicine, University of Bologna, Bologna, Italy; ^dDermatological Clinic, Department of Clinical and Molecular Sciences, Polytechnic University of the Marche Region, Ancona, Italy; ^eDermatology Clinic, Department of Health Sciences, University of Florence, Florence, Italy; ^fDermatology Section, Department of Medical, Surgical and Neurological Science, University of Siena, S. Maria Alle Scotte Hospital, Siena, Italy; ^gDermatology Unit - Department of Medicine, University of Padova, Padova, Italy

ABSTRACT

Background: Palmoplantar psoriasis is difficult to treat and often recalcitrant to conventional therapies. Clinical trials have demonstrated the efficacy and safety of secukinumab for this debilitating psoriasis form, but real-life evidence is currently limited. Therefore, here we described the outcomes of patients treated with secukinumab in clinical practice.

Research Design and Methods: This was a real-life, retrospective, observational study involving patients with palmoplantar psoriasis treated with secukinumab (300 mg, subcutaneously) at seven dermatologic clinics in Italy. Treatment effectiveness was evaluated based on the changes of the Psoriasis Area and Severity Index (PASI) and palmoplantar (pp) PASI during treatment and by recording safety and tolerability issues over 104 weeks.

Results: Forty-three patients initiated treatment with secukinumab. Previous treatments included topical and systemic therapies; half of patients had already tried one or more biologics. Secukinumab improved mean PASI rapidly and substantially with a 78.2% decrease at 16 weeks. Mean ppPASI also improved substantially, but more gradually, with reductions of 55.0% and 79.3% at 16 and 104 weeks, respectively. Approximately half of patients achieved complete skin clearance at 40 weeks. Secukinumab was well tolerated and no relevant treatment-related adverse events were reported.

Conclusions: Secukinumab appears to be effective for the treatment of palmoplantar psoriasis also in the real-life setting.

ARTICLE HISTORY

Received 23 December 2021
Accepted 12 January 2022

KEYWORDS

Effectiveness; observational; palmoplantar psoriasis; psoriasis; real-life; real-world; secukinumab

1. Introduction

The term palmoplantar psoriasis generally refers to hyperkeratotic psoriasis affecting mainly the palms of hands and/or the soles of feet, with or without the involvement of other body sites. This phenotype is reported to have a > 10% prevalence among patients with psoriasis in epidemiological studies and is characterized by erythema and keratotic plaques, with or without fissures, that can extend to the wrists and margins of the plantar surfaces [1,2]. The burden of palmoplantar psoriasis on patients is substantial and mostly due to functional disability, pain, and visibility of the lesions [3–5]. This results in a greater impairment of health-related quality of life (QoL) of patients with palmoplantar psoriasis compared to patients with psoriasis at other parts of the body [6–8]. In this psoriasis phenotype the extent of body surface area (BSA) affected is often <5% and lower than in other psoriasis forms [4]. However, patients may report greater disability, pain, and

QoL impairment than patients with the involvement of larger, but less difficult sites [4,8]. Palmoplantar psoriasis is often challenging to treat and recalcitrant to conventional treatments of psoriasis [9]. Biologics have proven effective and well tolerated [10].

Secukinumab is a fully human IgG1 monoclonal antibody that binds interleukin (IL)-17A, thereby blocking an inflammatory pathway with a crucial role in the pathogenesis of psoriasis [11–16]. Of note, increased expression of IL-17A has been reported in the palms and soles of patients with palmoplantar pustular psoriasis [17]. Results from phase 2 and 3 clinical trials have demonstrated the efficacy and favorable safety profile of secukinumab in moderate-to-severe psoriasis [18–21]. Secukinumab has also been shown to improve palmoplantar psoriasis [22–24]. Evidence from real-world use of secukinumab for the treatment of palmoplantar psoriasis is limited.

CONTACT Marco Galluzzo  marco.galluzzo@uniroma2.it  University of Rome 'Tor Vergata', Rome, Italy

*these authors contributed equally to this work
these authors are both senior authors

We report here the outcomes of 43 patients with palmoplantar psoriasis who initiated treatment with secukinumab in seven dermatology clinics in Italy and were followed for up to two years. We also include the discussion of five illustrative cases.

2. Patients and methods

2.1. Study design and patients

This real-life, retrospective, observational study included patients with psoriasis from seven dermatologic clinics in Italy who were treated for at least 16 weeks with secukinumab. Patients started treatment at different times. The present study provides therefore a cross-sectional ‘snapshot’ of our experience up to 30 December 2020. Patients were ≥ 18 years old and had a diagnosis of psoriasis with involvement of hand palms and/or foot soles. Patients had been previously treated with other biologics, or were naïve to biologics. Secukinumab was given at the recommended dose of 300 mg by subcutaneous injection at weeks 0, 1, 2, 3, and 4, followed by monthly maintenance injections [11]. Following data were collected for each patient: demographic and clinical characteristics; treatment history; involvement of special body sites; Psoriasis Area and Severity Index (PASI; only in patients with psoriasis at other sites) and palmoplantar PASI (ppPASI) at treatment beginning (week 0) and at weeks 8, 16, 24, 32, 40, 52, 76, 104 from treatment beginning. All patients signed an informed consent prior to enrollment. The study complied with the ethical standards set by the 1975 Declaration of Helsinki.

2.2. Outcome measures

Mean PASI and ppPASI were calculated for treatment beginning and for the various time points during treatment up to 104 weeks from treatment beginning. The PASI and ppPASI range from 0 (no psoriasis) to 72 (psoriasis of maximum severity). A score of 5 to 10 generally defines moderate disease, while a score > 10 defines severe disease [25,26]. The efficacy of secukinumab was evaluated based on the changes (decreases) of mean PASI and ppPASI compared with treatment beginning. The proportions of patients achieving a 50%, 75%, 90%, or 100% reduction in ppPASI (ie, ppPASI₅₀, 75, 90, or 100 responses) were also calculated for the time points considered. Treatment duration, reasons for treatment discontinuation, and adverse events were also recorded.

2.3. Statistical analysis

Data were summarized using descriptive statistics [mean \pm standard deviation (SD) for continuous variables and number and percentage for categorical variables]. Simple univariate and multivariate logistic regression analyses were performed to evaluate the association between dependent variables (eg, gender, age, age at disease onset, disease duration, body weight, BMI, baseline PASI and ppPASI, comorbidities, number of previous biological therapies, presence of psoriatic arthritis) and the achievement of ppPASI₅₀, 75, 90, and 100 responses at various time points during treatment; results are presented

as odds ratio (OR) and 95% confidence intervals (CI). A last observation carried forward (LOCF) approach to missing data was used [27]. A p-value of < 0.05 was considered statistically significant. The software STATA, version 11.2 (Statacorp LP Inc., College Station, TX, USA), was used for the entire statistical analysis.

3. Results

3.1. Patient characteristics

The analysis included 43 patients with psoriasis affecting palms and/or soles, who started treatment with secukinumab at seven dermatologic clinics located in six Italian regions across the entire national territory. Demographic and clinical characteristics at the beginning of treatment with secukinumab are summarized in Table 1. Patients were predominantly male (65.1%) and the mean age was 55.8 years (range 29–82). Mean durations of psoriasis and palmoplantar psoriasis were 18.9 years and 15.5 years, respectively. In most patients (83.7%), psoriasis affected also other body sites, while a minority (16.3%) had palmoplantar psoriasis with no involvement of other sites. In these patients, the diagnosis of psoriasis was confirmed histologically. Psoriatic arthritis was the most common comorbidity (34.9%) followed by hypertension (27.9%) and dyslipidemia (20.9%). Slightly more than half of the patients (53.5%) had already been treated with biologics prior to secukinumab. The mean PASI and ppPASI at the beginning of treatment with secukinumab were, respectively, 15.6 and 11.1, both indicative of severe disease.

Table 1. Baseline demographic and clinical characteristics.

	N = 43
Gender	
Female	15 (34.9%)
Male	28 (65.1%)
Age (years)	55.8 \pm 11.7 (29–82)
Body weight (kg)	77.4 \pm 15.2
BMI (kg/m ²)	26.1 \pm 3.8
BMI < 25	15 (34.9%)
BMI ≥ 25 and ≤ 30	22 (51.2%)
BMI > 30	6 (13.9%)
Age of psoriasis onset (years)	37.1 \pm 15.6 (10–74)
Age of palmoplantar psoriasis onset (years)	40.4 \pm 15.2 (16–74)
Duration of psoriasis (years)	18.9 \pm 13.8 (3–60)
Duration of palmoplantar psoriasis (years)	15.5 \pm 12.2 (1–47)
PASI	15.6 \pm 11.9 (1–56.7)
ppPASI	11.1 \pm 9.4 (1–40)
Current smoker	16 (37.2%)
Comorbidities	
Hypertension	12 (27.9%)
Dyslipidemia	9 (20.9%)
Psoriatic arthritis	15 (34.9%)
Cardiovascular/cerebrovascular diseases	3 (7.0%)
Type II diabetes	3 (7.0%)
Thyroid disorders	2 (4.6%)
Previous treatment with biologics	
No	20 (46.5%)
Yes	23 (53.5%)
1 biologic	15 (34.9%)
2 biologics	6 (14.0%)
3 or more biologics	2 (4.6%)

Data are shown as number of patients (percentage), or as mean value \pm standard deviation and (range). BMI, body mass index; PASI, Psoriasis Area and Severity Index; ppPASI, palmoplantar Psoriasis Area and Severity Index.

3.2. Changes in PASI and ppPASI

Figure 1 shows the changes in mean PASI and ppPASI, and the ppPASI response rates, during treatment with secukinumab. The mean PASI improved rapidly and substantially with decreases from the beginning of treatment to weeks 8, 16, and 24 of, respectively, 62.2%, 78.2%, and 82.7% (Figure 1a). Improved PASI scores were stable to the end of the observation period (week 104). The mean ppPASI also improved substantially with secukinumab treatment, but more gradually and over the entire observation period (Figure 1b). At weeks 8, 16, and 24 the mean ppPASI decreased respectively by 36.9%, 55.0%, and 65.8% compared with the mean score at treatment beginning. At week 104, the mean ppPASI had decreased by 79.3%.

The rates of ppPASI50, ppPASI75, ppPASI90, and ppPASI100 responses also improved steadily, continued to increase after week 16, and reached a plateau after 52 weeks of treatment (Figure 1c). While, at week 16, the ppPASI75, ppPASI90, and ppPASI100 responses were achieved by 38%, 28.6%, and 23.8% of patients, respectively, the highest palmoplantar response peaks were observed between treatment weeks 40 and 52, with approximately half of patients achieving the complete clearance of skin lesions on the palms and soles (ppPASI100 response) and 67.5% of patients achieving ppPASI75 response at week 40. In the long-term, at week 104, 65.5% of patients had a ppPASI75 response, while 51.7% had a ppPASI100 response (Figure 1c).

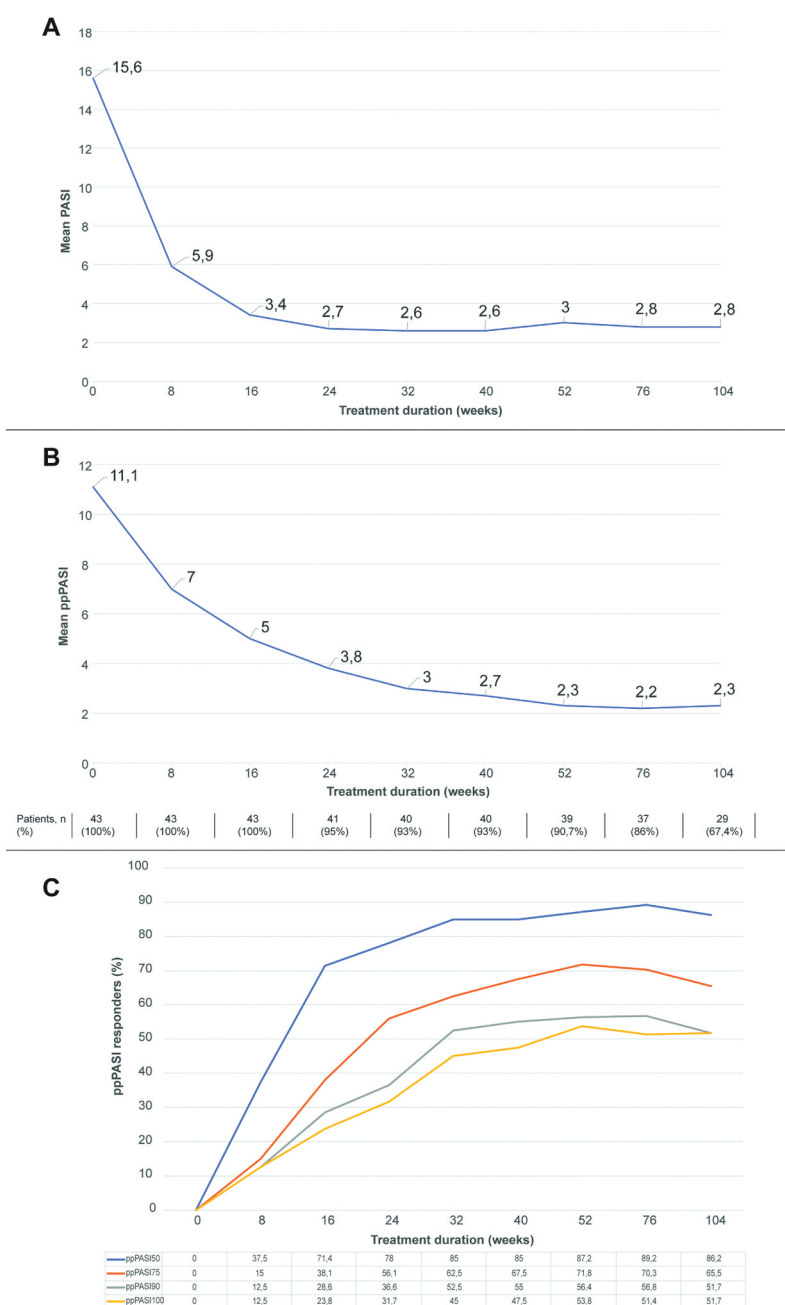


Figure 1. Effect of secukinumab in patients with palmoplantar psoriasis on absolute PASI (A), absolute ppPASI (B), and rates of ppPASI 50, 75, 90 and 100 responses (C) over 104 weeks.

3.3. Variables influencing the achievement of ppPASI responses

Univariate logistic regression identified a lower ppPASI at week 0 as a significant predictor of ppPASI100 response (clear palmoplantar skin) to secukinumab at week 16 (OR 1.43, $p = 0.01$, 95%CI 1.10–1.92). Multivariate logistic regression found a statistically significant correlation between the achievement of a ppPASI50 at week 16 and the variables gender and smoking status: male patients and nonsmokers were more likely to achieve a ppPASI50 response at 16 weeks of treatment with secukinumab (respectively, OR 4.97, $p = 0.04$, 95%CI 1.04–23.7 and OR 5.0, $p = 0.04$, 95%CI 1.04–25).

3.4. Treatment discontinuation, and safety and tolerability of treatment

Of the 43 patients who initiated treatment with secukinumab, 10 patients (23.2%) discontinued it during the observation period. The reasons for discontinuation were: primary lack of efficacy (2 patients; both discontinued after 20 weeks of treatment), loss of efficacy at palms and/or soles (2 patients, after 26 and 90 weeks of treatment), loss of efficacy at other sites with maintenance of response at palms and/or soles (4 patients, after 16, 72, 104, and 209 weeks of treatment), viral pericarditis (1 patient, after 36 weeks of treatment), and 1 patient lost to follow-up. Overall, the treatment was well tolerated and no relevant treatment-related adverse events were reported during the 104 weeks of observation.

3.5. Selected cases

Figure 2–Figure 5 provide an overview of five representative cases of palmoplantar psoriasis treated with secukinumab.

Case 1 was a 44 years old male patient, with a family history of psoriasis, who had been affected by moderate to severe chronic plaques psoriasis with palmoplantar involvement since the age of 27. Prior treatments included topical agents (corticosteroids and vitamin D-derivatives) and systemic therapies, namely cyclosporine A, methotrexate, acitretine, and adalimumab. All four systemic therapies were initially beneficial but had to be eventually discontinued due to loss of efficacy (cyclosporine A, methotrexate, and acitretine), or due to tolerability issues (exhaustion and discomfort with adalimumab). The patient initiated treatment with secukinumab 300 mg in October 2019 (PASI, 8; ppPASI, 30) and had a rapid improvement of PASI and ppPASI already visible at 8 weeks (PASI, 1.2; ppPASI, 5) (Figure 2).

In Case 2, a 67 years old male patient, the onset of palmoplantar was in 2011 and was associated with the grief for the loss of a family member. Disease remission was achieved with topical treatment, but in January 2019 the disease relapsed. Since 2010, the patient had been affected by hypertension and diabetes and had been in treatment for these comorbidities. Relapsing palmoplantar psoriasis was treated with topical agents (corticosteroids, vitamin D-derivatives, keratolytics) and with systemic therapies (acitretin, 20 mg). Acitretin was initially effective but had to be discontinued due to severe hypertriglyceridemia. In October 2019, the patient presented with a ppPASI of 40 and initiated treatment with secukinumab 300 mg. Improvement of ppPASI was slow but continuous and substantial (ppPASI at 12 weeks, 30; at 24 weeks, 18; at 52 weeks, 6) (Figure 3).

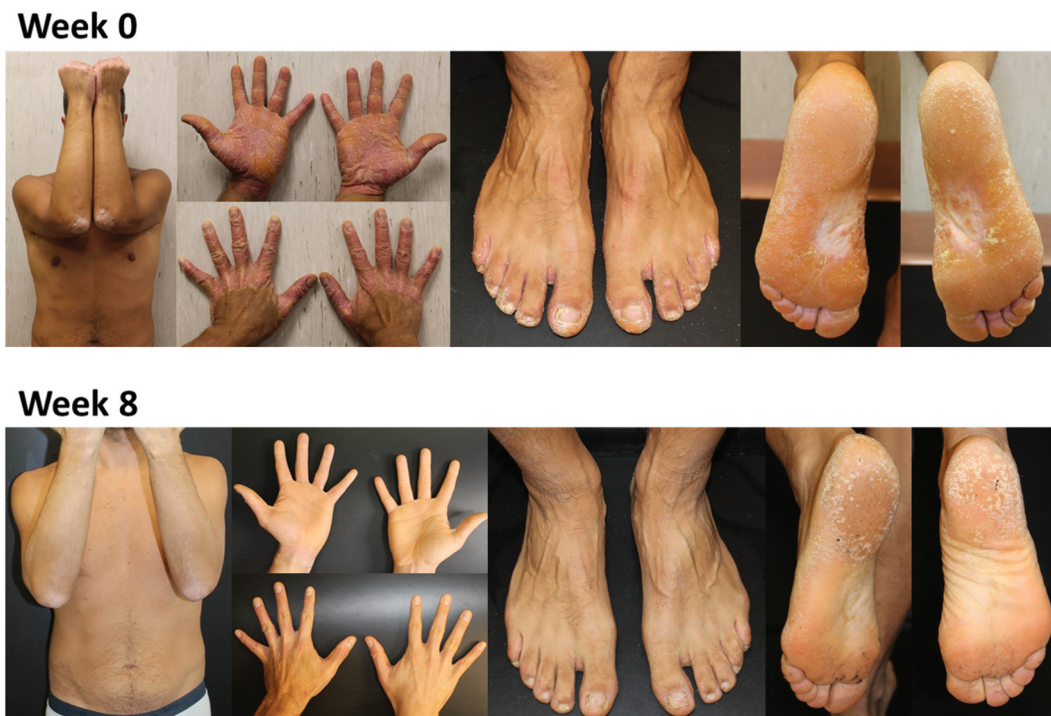

Figure 2. Changes in psoriasis skin lesions during treatment with secukinumab: case 1.

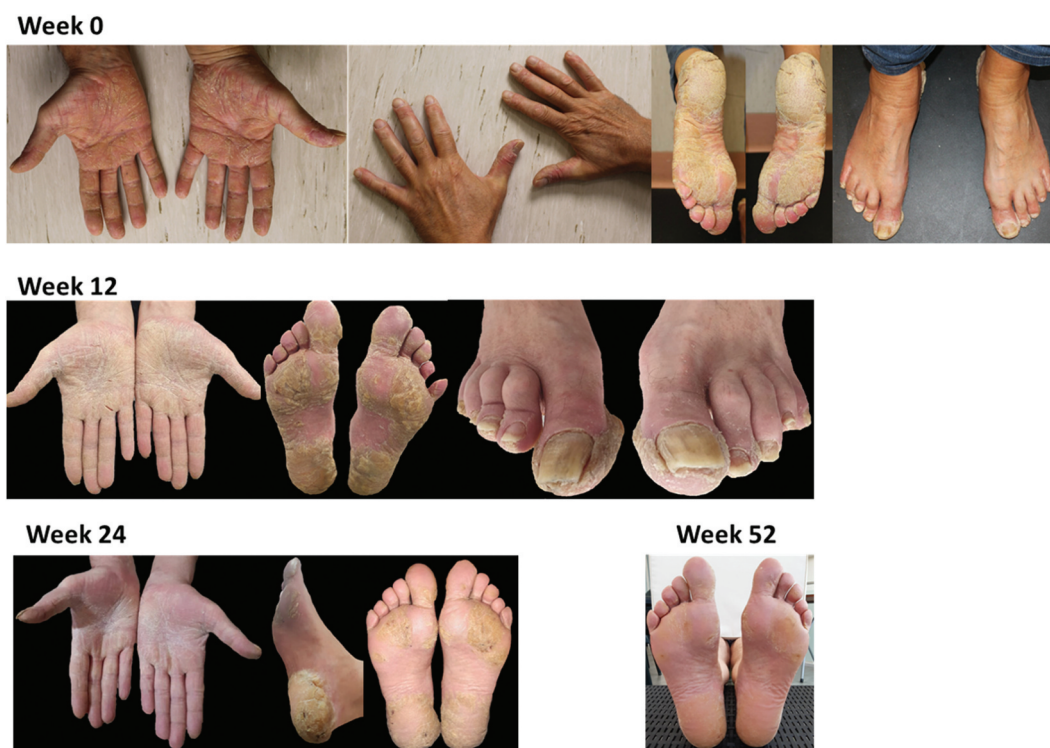

Figure 3. Changes in psoriasis skin lesions during treatment with secukinumab: case 2.

The onset of palmoplantar psoriasis in Case 3, a 69 years old man, was in 2017 and similar to Case 2 it appeared to be related to the loss of a family member. The disease involved only the soles of the feet. The patient, a former smoker, had a 20-year history of diabetes and hypertension and in 2017 had undergone a percutaneous coronary intervention. At presentation he was in treatment for his diabetes and cardiovascular conditions. Palmoplantar psoriasis had been treated initially with topical corticosteroids, vitamin D-derivates and kerolytics. Systemic therapy with acitretin had to be discontinued due to secondary inefficacy. The treatment with secukinumab 300 mg was started in March 2018 (ppPASI, 18). The patient responded well to treatments with secukinumab (ppPASI at 8 weeks, 12) and in September 2018 (week 24) the patient achieved disease remission (ppPASI, 0) (Figure 4). In December 2018 (week 36), the patient continued to be in remission. The secukinumab dose was reduced to 150 mg every 4 weeks in September 2019, with maintenance of disease remission.

Case 4 was a 35 years old male patient with psoriasis since the age of 26 and concomitant psoriatic arthritis. The patient was a former smoker. Since 2019, psoriasis had been localized predominantly to the palms of the hands. Previous therapies had included cyclosporine A, methotrexate, and the biologics adalimumab and etanercept, with unsatisfactory outcomes. Treatment with secukinumab was initiated in March 2019 (PASI, 31.4; ppPASI, 24.3) and led to a substantial improvement after 16 weeks (skin clearance according to PASI; ppPASI, 9) with further improvement of the ppPASI at 24 weeks (clear palms) and maintenance of clear skin over 2 years of observation (Figure 5a).

The patient of Case 5, a 65 years old man, was a smoker and had concomitant hypertension and dyslipidemia. The onset of psoriasis was at the age of 63 years, with a predominantly plantar involvement. The patient had been previously treated with cyclosporine A. At treatment beginning with secukinumab, PASI and ppPASI were, respectively, 45 and

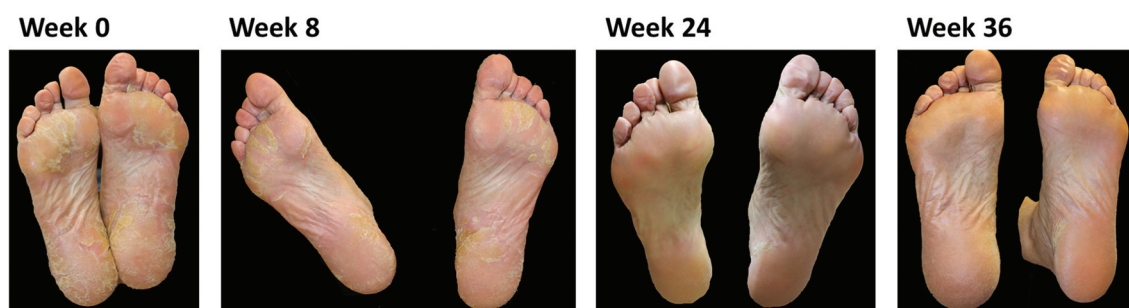

Figure 4. Changes in psoriasis skin lesions during treatment with secukinumab: case 3.

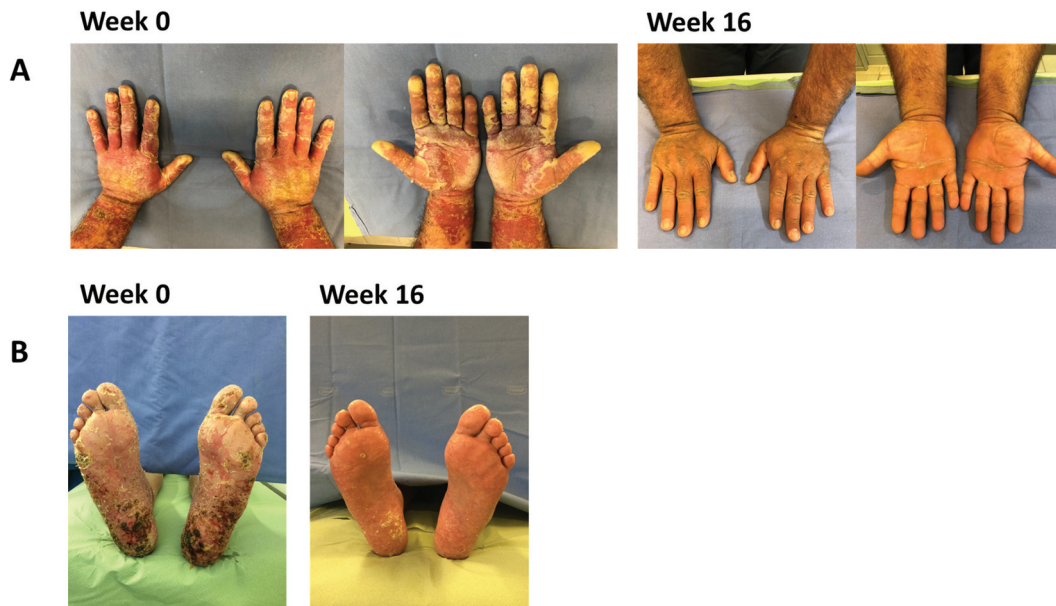


Figure 5. Changes in psoriasis skin lesions during treatment with secukinumab: cases 4 (A) and 5 (B).

18.5. Secukinumab reduced substantially and rapidly the PASI after 16 weeks (PASI, 8) (Figure 5b). The ppPASI score also improved (ppPASI at 16 weeks, 10.1) and continued to improve after 24 weeks of treatment with achievement of completely clear skin and maintenance of palmoplantar disease remission during the 2 years of observation.

4. Discussion

This observational study provides an overview of patients with palmoplantar psoriasis and their outcomes following treatment with secukinumab in real-life practice in Italy. In agreement with other reports concerning this difficult-to-treat subgroup of psoriasis patients, the study population had severe disease and had failed several previous topical and systemic therapies, including biologics [4]. Elevated rates of comorbidities and smoking habit contributed to making the management of these patients even more challenging. The treatment with secukinumab was not associated with relevant adverse events and was well tolerated. Secukinumab improved substantially the PASI with a > 60% decrease at 8 weeks compared with treatment beginning. ppPASI also improved with secukinumab, showing a continuous decrease during the entire observation period of 104 week, when ppPASI improvement versus treatment beginning was about 80%. The representative cases included in this article clearly illustrate the progressive clearance of skin lesions on palms and soles. ppPASI response rates of this difficult-to-treat population were elevated with almost 40% of patients achieving ppPASI75 after 16 weeks of treatment and about half reaching ppPASI100 after 40 weeks.

The outcomes of our real-life population confirm the efficacy and safety data reported in the randomized, double-blind, placebo-controlled, multicenter, phase IIIb trial GESTURE with secukinumab [23,24]. GESTURE was one of the few trials evaluating a therapy specifically in patients

with palmoplantar psoriasis. The study randomized 205 patients to secukinumab 300 mg, secukinumab 150 mg, or placebo. The primary endpoint was palmoplantar Investigator's Global Assessment (ppIGA) 0 or 1, corresponding to 'clear' or 'almost clear' palms and soles skin at 16 weeks [23]. At 16 weeks, significantly more patients treated with 300 mg or 150 mg secukinumab achieved the primary endpoint compared with patients treated with placebo (respectively, 33.3%, 22.1%, and 1.5%, $p < 0.001$). ppPASI also improved with both doses of secukinumab versus placebo (at 16 weeks, - 54.5%, - 35.3%, - 4.0%, $p < 0.001$, respectively). These disease improvements had a positive impact on health-related QoL as measured by the Dermatology Life Quality Index (DLQI). The GESTURE study also evaluated the long-term (2.5-year) efficacy and safety and showed that the effects seen at 16 weeks were sustained, with 53% and 59% of patients reaching at 2.5 years the primary endpoint of mean ppIGA 0 or 1 with, respectively, 300 mg and 150 mg secukinumab [24]. The mean ppPASI continued to improve and the decreases from baseline to 2.5 years accounted to 87.2% and 80.4% in patients treated with secukinumab 300 and 150 mg, respectively [24].

Our real-life observation has confirmed the continuous improvement of ppPASI scores and ppPASI responses over at least one year seen in the GESTURE trial. This may have implications in clinical practice with regard to how long secukinumab should be administered to properly evaluate response to treatment. Evaluation times longer than the usually recommended 16 weeks may be advisable.

Secukinumab effectiveness and tolerability for the treatment of psoriasis in real-life have been extensively investigated [28,29]. A recent meta-analysis of 43 real-life studies has concluded on the effectiveness of this biologic for moderate-to-severe psoriasis and pointed out the elevated drug retention rates, favorable tolerability profile, and improved patient reported outcomes [29]. Real-life evidence about the

use of secukinumab for the treatment of palmoplantar psoriasis, on the other hand, is very limited [30–32]. A recent real-life study in 83 psoriasis patients, 25.3% of whom had palmoplantar psoriasis confirmed the effectiveness and high retention rates of secukinumab and found that patients naïve to biologics and without coexisting psoriatic arthritis had the greatest benefits [32]. A significant correlation between response to secukinumab and no previous use of biologics was reported in a retrospective analysis of real-life data from 151 patients with moderate-to-severe plaque psoriasis, including subjects with palmoplantar psoriasis [28]. In the population of the present study, 46.5% of patients were naïve to biologics; the small sample size did however not allow us to conclude whether these patients had better outcomes.

A significant correlation between lower ppPASI values at treatment start and the achievement of completely clear palm and/or foot skin at week 16 was found in our observation, which suggests that early secukinumab treatment beginning, before the disease has progressed to a severe stage, may be beneficial. Multivariate logistic regression identified nonsmoker status and male gender as significant predictors of ppPASI50 response at 16 weeks. While the impact of gender on treatment response is currently hard to explain, smoking is a recognized trigger of palmoplantar psoriasis and may therefore have a negative impact on treatment outcomes [5].

Our observation is limited by its retrospective nature, the small size of the population and by the fact that data were pooled from different settings of palmoplantar psoriasis treatment. Despite these limitations, this study provides much needed real-life evidence about a possible strategy to a challenging and disabling psoriasis form.

5. Conclusions

Our findings suggest that secukinumab is a successful treatment option for the difficult-to-treat subgroup of psoriasis patients with affected palms and soles encountered in clinical practice. Effectiveness, tolerability profile, and timing of secukinumab action described in our non-selected patient population overlap with those reported in the controlled setting of clinical trials.

Acknowledgments

We thank Lorenza Lanini, who provided medical writing assistance on behalf of Health Publishing & Services Srl. This unconditional support was funded by Novartis Farma SpA.

Author's contributions statement

Marco Galluzzo, Marina Talamonti, Luca Bianchi and Francesca Prignano conceived and designed the study; all authors recruited patients and were involved in data acquisition; Marco Galluzzo and Marina Talamonti were involved in the analysis and interpretation of the data; all authors contributed to drafting the paper and revising it critically for intellectual content. All authors have read and agreed to the published version of the manuscript.

Declaration of interests

The authors have no other relevant affiliations or financial involvement with any organization or entity with a financial interest in or financial conflict with the subject matter or materials discussed in the manuscript.

Reviewer Disclosures

Peer reviewers on this manuscript have no relevant financial relationships or otherwise to disclose.

Funding

This paper was not funded.

ORCID

Marco Galluzzo  <http://orcid.org/0000-0002-3424-5175>
 Marina Talamonti  <http://orcid.org/0000-0002-3070-4071>
 Laura Atzori  <http://orcid.org/0000-0002-8105-1402>
 Anna Campanati  <http://orcid.org/0000-0002-3740-0839>
 Lidia Sacchelli  <http://orcid.org/0000-0003-4388-4523>
 Luca Bianchi  <http://orcid.org/0000-0001-8697-6896>

References

Papers of special note have been highlighted as either of interest (*) or of considerable interest (***) to readers.

1. Kumar B, Saraswat A, Kaur I. Palmoplantar lesions in psoriasis: a study of 3065 patients. *Acta Derm Venereol.* 2002;82(3):192–195.
2. Merola JF, Li T, Li WQ, et al. Prevalence of psoriasis phenotypes among men and women in the USA. *Clin Exp Dermatol.* 2016;41(5):486–489.
3. Pettey A, Balkrishnan R, Rapp SR, et al. Patients with palmoplantar psoriasis have more physical disability and discomfort than patients with other forms of psoriasis: implications for clinical practice. *J Am Acad Dermatol.* 49(2): 271–275. 2003.
- **Comprehensive assessment of patients with psoriasis showing that those with palmoplantar involvement experience significantly greater physical disability and discomfort.**
4. Merola JF, Qureshi A, Husni ME. Underdiagnosed and undertreated psoriasis: nuances of treating psoriasis affecting the scalp, face, intertriginous areas, genitals, hands, feet, and nails. *Dermatol Ther.* 2018;31(3):e12589.
- **Good review of psoriasis phenotypes, including palmoplantar psoriasis, that are difficult to manage.**
5. Miceli A, Schmieder GJ. Palmoplantar Psoriasis. 2021 Aug 7. StatPearls [Internet]: Treasure Island (FL): StatPearls Publishing. [cited 2021 Dec 20]. PMID: 28846363. Available from: <https://www.ncbi.nlm.nih.gov/books/NBK448142/>
6. Farley E, Masrour S, McKey J, et al. Palmoplantar psoriasis: a phenotypical and clinical review with introduction of a new quality-of-life assessment tool. *J Am Acad Dermatol.* 2009;60(6):1024–1031.
7. Chung J, Callis Duffin K, Takeshita J, et al. Palmoplantar psoriasis is associated with greater impairment of health-related quality of life compared to moderate-to-severe plaque psoriasis. *J Am Acad Dermatol.* 71(4): 623–632. 2014.
- **First study to quantify the differences in patient-reported outcomes (health-related QoL) between patients with palmoplantar psoriasis and patients with plaque psoriasis.**
8. Dopytalska K, Sobolewski P, Blaszczak A, et al. Psoriasis in special localizations. *Reumatologia.* 2018;56(6):392–398.
9. Al-Mutairi A, Abdalla TO, Nour TM. Resistant palmoplantar lesions in patients of psoriasis: evaluation of the causes and comparison of the frequency of delayed-type hypersensitivity in patients without palm and sole lesions. *Med Princ Pract.* 2014;23(6):561–567.

10. Sanchez IM, Sorensen E, Levin E, et al. The efficacy of biologic therapy for the management of palmoplantar psoriasis and palmoplantar pustulosis: a systematic review. *Dermatol Ther.* 2017;7(4):425–446.
 - **Systematic analysis of studies investigating the efficacy of biologics for the treatment of palmoplantar psoriasis and palmoplantar pustulosis.**
11. Sanchez IM, Sorensen E, Levin E, et al. EMA Summary of product characteristics. [cited 2021 Dec 20]. Available from: https://www.ema.europa.eu/en/documents/product-information/cosentyx-epar-product-information_en.pdf
12. Prinz I, Sandrock I, Mrowietz U. Interleukin-17 cytokines: effectors and targets in psoriasis – a breakthrough in understanding and treatment. *J Exp Med.* 2020;217(1):e20191397.
13. Frieder J, Kivelevitch D, Menter A. Secukinumab: a review of the anti-IL-17A biologic for the treatment of psoriasis. *Ther Adv Chronic Dis.* 2018;9(1):5–21.
14. Tokuyama M, Mabuchi T. New treatment addressing the pathogenesis of psoriasis. *Int J Mol Sci.* 2020;21(20):7488.
15. Aboobacker S, Kurn H, Aboud A, et al. 2021 Jun 29; StatPearls [Internet]. Treasure Island (FL): StatPearls Publishing. 2021, Jan PMID: 30725776.
16. Raharja A, Mahil SK, Barker JN. Psoriasis: a brief overview. *Clin Med.* 2021;21(3):170–173.
17. Bissonnette R, Nigen S, Langley RG, et al. Increased expression of IL-17A and limited involvement of IL-23 in patients with palmoplantar (PP) pustular psoriasis or PP pustulosis; results from a randomised controlled trial. *J Eur Acad Dermatol Venereol.* 28(10): 1298–1305. 2014.
 - **Small study highlighting the involvement of the IL-17 signaling pathway in palmoplantar psoriatic disease.**
18. Papp KA, Langley RG, Sigurgeirsson B, et al. Efficacy and safety of secukinumab in the treatment of moderate-to-severe plaque psoriasis: a randomized, double-blind, placebo-controlled phase II dose-ranging study. *Br J Dermatol.* 2013;168(2):412–421.
19. Rich P, Sigurgeirsson B, Thaci D, et al. Secukinumab induction and maintenance therapy in moderate-to-severe plaque psoriasis: a randomized, double-blind, placebo-controlled, phase II regimen-finding study. *Br J Dermatol.* 2013;168:402–411.
20. Langley RG, Elewski BE, Lebwohl M, et al. Secukinumab in plaque psoriasis results of two phase 3 trials. *N Engl J Med.* 2014;371:326–338.
21. Paul C, Lacour JP, Tedremets L, et al. Efficacy, safety, and usability of secukinumab administration by autoinjector/pen in psoriasis a randomized, controlled trial (JUNCTURE). *J Eur Acad Dermatol Venereol.* 2015;29(6):1082–1090.
22. Paul C, Reich K, Gottlieb AB, et al. Secukinumab improves hand, foot and nail lesions in moderate-to-severe plaque psoriasis: subanalysis of a randomized, double-blind, placebo-controlled, regimen-finding phase 2 trial. *J Eur Acad Dermatol Venereol.* 2014;28(12):1670–1675.
23. Gottlieb A, Sullivan J, van Doorn M, et al. Secukinumab shows significant efficacy in palmoplantar psoriasis: results from GESTURE, a randomized controlled trial. *J Am Acad Dermatol.* 2017;76(1):70–80.
 - **16-week results from GESTURE, one of the largest randomized controlled trials to evaluate a biologic specifically in patients with palmoplantar psoriasis.**
24. Gottlieb AB, Kubanov A, van Doorn M, et al. Sustained efficacy of secukinumab in patients with moderate-to-severe palmoplantar psoriasis: 2.5-year results from GESTURE, a randomized, double-blind, placebo-controlled trial. *Br J Dermatol.* 182(4): 889–899. 2020.
 - **2.5-year results from the GESTURE trial.**
25. Langley RG, Ellis CN. Evaluating psoriasis with psoriasis area and severity index, psoriasis global assessment, and lattice system physician's global assessment. *J Am Acad Dermatol.* 2004;51(4):563–569.
26. Clinical Review Report: Guselkumab (Tremfya) (Janssen Inc.): indication: for the treatment of adult patients with moderate-to-severe plaque psoriasis who are candidates for systemic therapy or phototherapy [Internet]. Ottawa (ON): Canadian Agency for Drugs and Technologies in Health; 2018 Mar. Appendix 5, Validity of Outcome Measures.
27. Papp KA, Fonjallaz P, Casset-Semanaz F, et al. Analytical approaches to reporting long-term clinical trial data. *Curr Med Res Opin.* 2008;24(7):2001–2008.
28. Galluzzo M, D'Adamio S, Silvaggio D, et al. In which patients the best efficacy of secukinumab? Update of a real-life analysis after 136 weeks of treatment with secukinumab in moderate-to-severe plaque psoriasis. *Expert Opin Biol Ther.* 2020;20(2):173–182.
29. Augustin M, Jullien D, Martin A, et al. Real-world evidence of secukinumab in psoriasis treatment – a meta-analysis of 43 studies. *J Eur Acad Dermatol Venereol.* 2020;34(6):1174–1185.
30. Rocamora V, Garcias-Ladaria J. Complete response of secukinumab in palmoplantar psoriasis. *Dermatol Online J.* 2017;23(10):23.
31. Megna M, Cirillo T, Balato A, et al. Real-life effectiveness of biological drugs on psoriatic difficult-to-treat body regions: scalp, palmoplantar area and lower limbs. *J Eur Acad Dermatol Venereol.* 2019;33(1):e22–e23.
32. Rompoti N, Katsimbri P, Kokkalis G, et al. Real world data from the use of secukinumab in the treatment of moderate-to-severe psoriasis, including scalp and palmoplantar psoriasis: a 104-week clinical study. *Dermatol Ther.* 2019;32(5):e13006.