

World Journal of *Clinical Cases*

World J Clin Cases 2021 July 16; 9(20): 5352-5753



EDITORIAL

- 5352 COVID-19: Considerations about immune suppression and biologicals at the time of SARS-CoV-2 pandemic
Costanzo G, Cordeddu W, Chessa L, Del Giacco S, Firinu D

REVIEW

- 5358 Obesity in people with diabetes in COVID-19 times: Important considerations and precautions to be taken
Alberti A, Schuelter-Trevisol F, Iser Betine PM, Traebert E, Freiburger V, Ventura L, Rezin GT, da Silva BB, Meneghetti Dallacosta F, Grigollo L, Dias P, Fin G, De Jesus JA, Pertille F, Rossoni C, Hur Soares B, Nodari Junior RJ, Comim CM
- 5372 Revisiting delayed appendectomy in patients with acute appendicitis
Li J

MINIREVIEWS

- 5391 Detection of short stature homeobox 2 and RAS-associated domain family 1 subtype A DNA methylation in interventional pulmonology
Wu J, Li P
- 5398 Borderline resectable pancreatic cancer and vascular resections in the era of neoadjuvant therapy
Mikulic D, Mrzljak A
- 5408 Esophageal manifestation in patients with scleroderma
Voulgaris TA, Karamanolis GP
- 5420 Exploration of transmission chain and prevention of the recurrence of coronavirus disease 2019 in Heilongjiang Province due to in-hospital transmission
Chen Q, Gao Y, Wang CS, Kang K, Yu H, Zhao MY, Yu KJ
- 5427 Role of gastrointestinal system on transmission and pathogenesis of SARS-CoV-2
Simsek C, Erul E, Balaban HY

ORIGINAL ARTICLE**Case Control Study**

- 5435 Effects of nursing care in fast-track surgery on postoperative pain, psychological state, and patient satisfaction with nursing for glioma
Deng YH, Yang YM, Ruan J, Mu L, Wang SQ

Retrospective Study

- 5442 Risk factors related to postoperative recurrence of dermatofibrosarcoma protuberans: A retrospective study and literature review
Xiong JX, Cai T, Hu L, Chen XL, Huang K, Chen AJ, Wang P

- 5453** Prediction of presence and severity of coronary artery disease using prediction for atherosclerotic cardiovascular disease risk in China scoring system

Hong XL, Chen H, Li Y, Teeroovengadum HD, Fu GS, Zhang WB

- 5462** Effects of angiotensin receptor blockers and angiotensin-converting enzyme inhibitors on COVID-19

Li XL, Li T, Du QC, Yang L, He KL

- 5470** Prognostic factors and its predictive value in patients with metastatic spinal cancer

Gao QP, Yang DZ, Yuan ZB, Guo YX

Clinical Trials Study

- 5479** Prospective, randomized comparison of two supplemental oxygen methods during gastro-scopy with propofol mono-sedation in obese patients

Shao LJZ, Hong FX, Liu FK, Wan L, Xue FS

SYSTEMATIC REVIEWS

- 5490** Herb-induced liver injury: Systematic review and meta-analysis

Ballotin VR, Bigarella LG, Brandão ABM, Balbinot RA, Balbinot SS, Soldera J

META-ANALYSIS

- 5514** Type 2 diabetes mellitus increases liver transplant-free mortality in patients with cirrhosis: A systematic review and meta-analysis

Liu ZJ, Yan YJ, Weng HL, Ding HG

CASE REPORT

- 5526** Duplication of 19q (13.2-13.31) associated with comitant esotropia: A case report

Feng YL, Li ND

- 5535** Multiple left ventricular myxomas combined with severe rheumatic valvular lesions: A case report

Liu SZ, Hong Y, Huang KL, Li XP

- 5540** Complete pathological response in locally advanced non-small-cell lung cancer patient: A case report

Parisi E, Arpa D, Ghigi G, Micheletti S, Neri E, Tontini L, Pieri M, Romeo A

- 5547** Successful reversal of ostomy 13 years after Hartmann procedure in a patient with colon cancer: A case report

Huang W, Chen ZZ, Wei ZQ

- 5556** Delayed papillary muscle rupture after radiofrequency catheter ablation: A case report

Sun ZW, Wu BF, Ying X, Zhang BQ, Yao L, Zheng LR

- 5562** Temporary coronary sinus pacing to improve ventricular dyssynchrony with cardiogenic shock: A case report

Ju TR, Tseng H, Lin HT, Wang AL, Lee CC, Lai YC

- 5568** Hemoglobin Fukuoka caused unexpected hemoglobin A_{1c} results: A case report
Lin XP, Yuan QR, Niu SQ, Jiang X, Wu ZK, Luo ZF
- 5575** Giant androgen-producing adrenocortical carcinoma with atrial flutter: A case report and review of the literature
Costache MF, Arhirii RE, Mogos SJ, Lupascu-Ursulescu C, Litcanu CI, Ciuranghel AI, Cucu C, Ghiciuc CM, Petris AO, Danila N
- 5588** Can kissing cause paraquat poisoning: A case report and review of literature
Ly B, Han DF, Chen J, Zhao HB, Liu XL
- 5594** Spinal dural arteriovenous fistula 8 years after lumbar discectomy surgery: A case report and review of literature
Ouyang Y, Qu Y, Dong RP, Kang MY, Yu T, Cheng XL, Zhao JW
- 5605** Perianal superficial CD34-positive fibroblastic tumor: A case report
Long CY, Wang TL
- 5611** Low-dose clozapine-related seizure: A case report and literature review
Le DS, Su H, Liao ZL, Yu EY
- 5621** Rapid diagnosis of disseminated *Mycobacterium mucogenicum* infection in formalin-fixed, paraffin-embedded specimen using next-generation sequencing: A case report
Liu J, Lei ZY, Pang YH, Huang YX, Xu LJ, Zhu JY, Zheng JX, Yang XH, Lin BL, Gao ZL, Zhuo C
- 5631** Cytomegalovirus colitis induced segmental colonic hypoganglionosis in an immunocompetent patient: A case report
Kim BS, Park SY, Kim DH, Kim NI, Yoon JH, Ju JK, Park CH, Kim HS, Choi SK
- 5637** Primary extra-pancreatic pancreatic-type acinar cell carcinoma in the right perinephric space: A case report and review of literature
Wei YY, Li Y, Shi YJ, Li XT, Sun YS
- 5647** Muscular atrophy and weakness in the lower extremities in Behçet's disease: A case report and review of literature
Kim KW, Cho JH
- 5655** Novel technique of extracorporeal intrauterine morcellation after total laparoscopic hysterectomy: Three emblematic case reports
Macciò A, Sanna E, Lavra F, Calò P, Madeddu C
- 5661** Rare isolated extra-hepatic bile duct injury: A case report
Zhao J, Dang YL, Lin JM, Hu CH, Yu ZY
- 5668** Gelfoam embolization for distal, medium vessel injury during mechanical thrombectomy in acute stroke: A case report
Kang JY, Yi KS, Cha SH, Choi CH, Kim Y, Lee J, Cho BS

- 5675** Oncocytic adrenocortical tumor with uncertain malignant potential in pediatric population: A case report and review of literature
Chen XC, Tang YM, Mao Y, Qin DR
- 5683** Submucosal hematoma with a wide range of lesions, severe condition and atypical clinical symptoms: A case report
Liu L, Shen XJ, Xue LJ, Yao SK, Zhu JY
- 5689** Chorioamnionitis caused by *Serratia marcescens* in a healthcare worker: A case report
Park SY, Kim MJ, Park S, Kim NI, Oh HH, Kim J
- 5695** Endoscopic management of biliary ascariasis: A case report
Wang X, Lv YL, Cui SN, Zhu CH, Li Y, Pan YZ
- 5701** Role of ranulas in early diagnosis of Sjögren's syndrome: A case report
Chen N, Zeng DS, Su YT
- 5709** Sacral chondroblastoma — a rare location, a rare pathology: A case report and review of literature
Zheng BW, Niu HQ, Wang XB, Li J
- 5717** Primary liver actinomycosis in a pediatric patient: A case report and literature review
Liang ZJ, Liang JK, Chen YP, Chen Z, Wang Y
- 5724** Splenosis masquerading as gastric stromal tumor: A case report
Zheng HD, Xu JH, Sun YF
- 5730** Hemorrhagic transformation of ischemic cerebral proliferative angiopathy: A case report
Xia Y, Yu XF, Ma ZJ, Sun ZW
- 5737** Multidisciplinary team therapy for left giant adrenocortical carcinoma: A case report
Zhou Z, Luo HM, Tang J, Xu WJ, Wang BH, Peng XH, Tan H, Liu L, Long XY, Hong YD, Wu XB, Wang JP, Wang BQ, Xie HH, Fang Y, Luo Y, Li R, Wang Y
- 5744** Histopathology and immunophenotyping of late onset cutaneous manifestations of COVID-19 in elderly patients: Three case reports
Mazzitelli M, Dastoli S, Mignogna C, Bennardo L, Lio E, Pelle MC, Treccarichi EM, Pereira BI, Nisticò SP, Torti C

CORRECTION

- 5752** Corrigendum to "Probiotic mixture VSL#3: An overview of basic and clinical studies in chronic diseases"
Sang LX

ABOUT COVER

Editorial Board Member of *World Journal of Clinical Cases*, Fan-Zheng Meng, MD, PhD, Director, Professor, Department of Pediatrics, The First hospital of Jilin University, Changchun 130021, Jilin Province, China. mengfanzheng1972@163.com

AIMS AND SCOPE

The primary aim of *World Journal of Clinical Cases (WJCC, World J Clin Cases)* is to provide scholars and readers from various fields of clinical medicine with a platform to publish high-quality clinical research articles and communicate their research findings online.

WJCC mainly publishes articles reporting research results and findings obtained in the field of clinical medicine and covering a wide range of topics, including case control studies, retrospective cohort studies, retrospective studies, clinical trials studies, observational studies, prospective studies, randomized controlled trials, randomized clinical trials, systematic reviews, meta-analysis, and case reports.

INDEXING/ABSTRACTING

The *WJCC* is now indexed in Science Citation Index Expanded (also known as SciSearch®), Journal Citation Reports/Science Edition, Scopus, PubMed, and PubMed Central. The 2021 Edition of Journal Citation Reports® cites the 2020 impact factor (IF) for *WJCC* as 1.337; IF without journal self cites: 1.301; 5-year IF: 1.742; Journal Citation Indicator: 0.33; Ranking: 119 among 169 journals in medicine, general and internal; and Quartile category: Q3. The *WJCC*'s CiteScore for 2020 is 0.8 and Scopus CiteScore rank 2020: General Medicine is 493/793.

RESPONSIBLE EDITORS FOR THIS ISSUE

Production Editor: Jia-Hui Li; Production Department Director: Yu-Jie Ma; Editorial Office Director: Jin-Lai Wang.

NAME OF JOURNAL

World Journal of Clinical Cases

ISSN

ISSN 2307-8960 (online)

LAUNCH DATE

April 16, 2013

FREQUENCY

Thrice Monthly

EDITORS-IN-CHIEF

Dennis A Bloomfield, Sandro Vento, Bao-Gan Peng

EDITORIAL BOARD MEMBERS

<https://www.wjgnet.com/2307-8960/editorialboard.htm>

PUBLICATION DATE

July 16, 2021

COPYRIGHT

© 2021 Baishideng Publishing Group Inc

INSTRUCTIONS TO AUTHORS

<https://www.wjgnet.com/bpg/gerinfo/204>

GUIDELINES FOR ETHICS DOCUMENTS

<https://www.wjgnet.com/bpg/GerInfo/287>

GUIDELINES FOR NON-NATIVE SPEAKERS OF ENGLISH

<https://www.wjgnet.com/bpg/gerinfo/240>

PUBLICATION ETHICS

<https://www.wjgnet.com/bpg/GerInfo/288>

PUBLICATION MISCONDUCT

<https://www.wjgnet.com/bpg/gerinfo/208>

ARTICLE PROCESSING CHARGE

<https://www.wjgnet.com/bpg/gerinfo/242>

STEPS FOR SUBMITTING MANUSCRIPTS

<https://www.wjgnet.com/bpg/GerInfo/239>

ONLINE SUBMISSION

<https://www.f6publishing.com>

Novel technique of extracorporeal intrauterine morcellation after total laparoscopic hysterectomy: Three emblematic case reports

Antonio Macciò, Elisabetta Sanna, Fabrizio Lavra, Piergiorgio Calò, Clelia Madeddu

ORCID number: Antonio Macciò 0000-0003-0577-7217; Elisabetta Sanna 0000-0002-6680-5560; Fabrizio Lavra 0000-0001-7881-7895; Piergiorgio Calò 0000-0001-9637-1145; Clelia Madeddu 0000-0001-8940-6987.

Author contributions: Macciò A was responsible for manuscript intellectual content; Macciò A and Madeddu C contributed to manuscript drafting, data analysis, interpretation, reviewed the literature and were responsible for the revision of the manuscript; Macciò A, Sanna E and Lavra F were the gynecological surgeons, performed the data analysis and interpretation and contributed to manuscript drafting; Calò PG contributed to manuscript drafting, data interpretation, review of the literature, manuscript revision; all authors issued final approval for the version to be submitted.

Informed consent statement: Informed consent was obtained from all subjects involved in the study.

Conflict-of-interest statement: The authors declare no conflict of interest.

CARE Checklist (2016) statement: The authors have read the CARE Checklist (2016), and the manuscript was prepared and

Antonio Macciò, Elisabetta Sanna, Fabrizio Lavra, Department of Gynecologic Oncology, Businco Hospital, ARNAS G. Brotzu, Cagliari 09100, Italy

Piergiorgio Calò, Department of Surgical Sciences, University of Cagliari, Cagliari 09100, Italy

Clelia Madeddu, Department of Medical Sciences and Public Health, University of Cagliari, Cagliari 09100, Italy

Corresponding author: Antonio Macciò, MD, Chief Doctor, Department of Gynecologic Oncology, Businco Hospital, ARNAS G. Brotzu, Via Jenner, Cagliari 09100, Italy. clelia.madeddu@tiscali.it

Abstract

BACKGROUND

In the presence of a large uterus, total laparoscopic hysterectomy (TLH), always requires morcellation to allow removal of the tissues from the abdominal cavity. However, uncontained morcellation has been scrutinized because of the possible spread of occult leiomyosarcoma. Therefore, in-bag extracorporeal morcellation has been developed. However, tissue containment and extraction are extremely challenging, especially when considering the increasing uterine size to be removed through minimally invasive surgery.

CASE SUMMARY

Herein, we describe a novel technique for extracorporeal intrauterine morcellation using the uterus outermost layer as a bag to achieve tissue extraction of very large uteri with suspected occult leiomyosarcoma after TLH. The study enrolled patients who were planned for TLH for large uteri (weight > 500 g). TLH was performed following the procedure reported in our previous studies. The novel technique has been described step-by-step in a video, which representatively describes the preoperative imaging and morcellation procedure of three very large uteri weighing 1500 g, 1700 g, and 3700 g, respectively. The procedures were performed without any complications. The patients had an uneventful postoperative course, and in all cases, the pathology was benign leiomyoma.

CONCLUSION

Extracorporeal intrauterine morcellation using the uterus outmost layer as a bag was found to be a feasible technique that allows a careful diagnosis and safe removal of suspected occult malignancies. The technique herein presented may be adopted in surgical practice, by adding it to the other available techniques of

revised according to the CARE Checklist (2016).

Open-Access: This article is an open-access article that was selected by an in-house editor and fully peer-reviewed by external reviewers. It is distributed in accordance with the Creative Commons Attribution NonCommercial (CC BY-NC 4.0) license, which permits others to distribute, remix, adapt, build upon this work non-commercially, and license their derivative works on different terms, provided the original work is properly cited and the use is non-commercial. See: <http://creativecommons.org/licenses/by-nc/4.0/>

Manuscript source: Unsolicited manuscript

Specialty type: Obstetrics and gynecology

Country/Territory of origin: Italy

Peer-review report's scientific quality classification

Grade A (Excellent): 0
Grade B (Very good): 0
Grade C (Good): C
Grade D (Fair): 0
Grade E (Poor): 0

Received: February 28, 2021

Peer-review started: February 28, 2021

First decision: April 29, 2021

Revised: May 10, 2021

Accepted: May 24, 2021

Article in press: May 24, 2021

Published online: July 16, 2021

P-Reviewer: Garg P

S-Editor: Ma YJ

L-Editor: A

P-Editor: Li JH



contained morcellation. It may represent a valid and feasible alternative, especially useful in cases of very large uteri exceeding the capacity of specimen retrieval bags.

Key Words: Laparoscopy; Minimally invasive surgery; Morcellation; myomas; Large uterus; Total laparoscopic hysterectomy; Case report

©The Author(s) 2021. Published by Baishideng Publishing Group Inc. All rights reserved.

Core Tip: In presence of large uteri, to preserve minimally invasive surgery morcellation is required to allow removal of the specimens from the abdominal cavity. However, uncontained morcellation has been banned because of the possible spread of occult leiomyosarcoma. Therefore, a variety of tissue containment systems have been developed; in particular, in case of very large specimen the practice of in-bag extracorporeal morcellation has been tested. Herein, we describe a novel technique for extracorporeal intrauterine morcellation using the uterus outermost layer as a bag to achieve tissue extraction of very large uteri after total laparoscopic hysterectomy. Such technique showed to be feasible and safe; it may be adopted in surgical practice, as an additional alternative to the currently available techniques of contained morcellation.

Citation: Macciò A, Sanna E, Lavra F, Calò P, Madeddu C. Novel technique of extracorporeal intrauterine morcellation after total laparoscopic hysterectomy: Three emblematic case reports. *World J Clin Cases* 2021; 9(20): 5655-5660

URL: <https://www.wjgnet.com/2307-8960/full/v9/i20/5655.htm>

DOI: <https://dx.doi.org/10.12998/wjcc.v9.i20.5655>

INTRODUCTION

In the presence of large uteri, minimally invasive surgeries, always require morcellation to reduce the uterine size and thereby allowing removal of the tissues through small incisions or with laparoscopic instruments. Over time several approaches have been developed for morcellation. It was at first executed manually utilizing scissors or scalpels throughout vaginal and mini-laparotomy approaches; thereafter, in 1993 an electromechanical morcellator was introduced and gained popularity for its efficiency and time and cost-saving[1]. Different techniques have been also reported to aid uterine tissue removal including bivalving, wedge resection, coring, and the "EXCITE" or "extracorporeal C-incision tissue extraction" technique[2,3]. Transvaginal morcellation or by a posterior colpotomy has been additionally described and can represent a suitable option[4]. However, the uncontained morcellation of the uterus and myomas have been inspected owing to the potential dissemination of occult leiomyosarcoma [5]. Given this potential risk in 2014, the Food and Drug Administration warned against the utilization of laparoscopic power morcellation in case of laparoscopic hysterectomy or myomectomy for presumed benign uterine myomas[6] and recommended the use of contained morcellation systems[7]. The employment of containment bags as a supplement to power morcellation has been recommended to restrict tissue spreading during the tissue extraction[8]. Such procedure was firstly described by Shibley[9] that used power morcellation to remove a uterus inside a bowel isolation bag. Different authors described feasible variants of such procedure, without major complications[10-14]. Retrospective studies showed that contained power morcellation necessitates an extra operative time of 20-26 minutes in comparison to uncontained power morcellation, with similar postoperative results[15, 16]. A lot of these studies on contained power morcellation utilized bags not strictly developed for this specific intention[17]. Then, different containment tools have been developed to aid laparoscopic power morcellation, such as the Pneumoliner, the More-Cell-Safe[18] and the MorSAfe[19] in-bag contained power morcellation systems. Also, in case of manual morcellation the use of containment bag is important to limit tissue spillage and a variety of tissue containment bag have been employed with feasibility[4, 13,20,21]. However, the majority of containment bag have not been specifically labeled for the indication of manual morcellation[17].

Then, the tissue containment and extraction have become extremely challenging, especially when considering the increasing uterine size to be removed through minimally invasive techniques. Notably, for some large masses, there are not large enough endobags to fit them in for extraperitoneal morcellation. Consistently, the American Association of Gynecologic Laparoscopists (AAGL) Practice Report highlighted that the use of specimen retrieval pouches should be investigated further [22]. With this background, here we aim to describe a new technique for extracorporeal intrauterine morcellation utilizing the uterus outermost layer as a bag to achieve tissue extraction of large myomatous uteri.

CASE PRESENTATION

Chief complaints

Case 1: The patient referred progressive increase in abdominal circumference.

Case 2: At admission patient referred progressive increase in abdominal circumferences associated with constipation and swallowing problems

Case 3: The patient came to our attention complaining symptoms related to an enlarged uterus, *i.e.*, constipation, swallowing difficulties, increasing dyspnea, and pain, accompanied by ongoing enlargement of abdominal circumference.

History of present illness

Three patients were candidates to undergo total laparoscopic hysterectomy (TLH) for large fibromatous uteri (weight > 500 g) and were referred to our tertiary referral center, Department of Gynecologic Oncology, Azienda Ospedaliera Brotzu, Cagliari. The study was carried out following the principles of the Declaration of Helsinki. According to the Italian Regulatory Agency for observational trials not involving drugs, the protocol was disclosed and authorized by the Institutional Ethics Committee of “Azienda Ospedaliero Universitaria di Cagliari”, Cagliari, Italy. The patients gave written informed consent for the study enrolment, surgical procedure, and publication of the data and imaging.

History of past illness

In all cases patients' past medical history was unremarkable.

Personal and family history

In all cases patients' personal and family history was unremarkable.

Physical examination

Physical examination and bimanual pelvic examination at admission showed enlarged uterus accompanied by enlarged abdominal circumference in all three cases.

Laboratory examinations

Before the surgery each patients underwent cervicovaginal smear, and endometrial sampling based on endometrial thickness: In all cases malignancy was excluded.

Imaging examinations

Before the surgery, each patient underwent abdominal and transvaginal ultrasonography, as well as magnetic resonance (MR) or computed tomography (CT) of the abdomen. Specifically, the video 1 reports in detail the findings of the preoperative diagnostic imaging (computed tomography and magnetic resonance) of three emblematic cases.

FINAL DIAGNOSIS

In all three cases the diagnosis was very large fibromatous uteri (weight > 500 g) with suspected occult leiomyosarcoma. In detail, the uterine weight was 1500 g, 1700 g, and 3700 g in case 1, case 2 and case 3, respectively (Video 1). In all cases, pathological examination revealed benign leiomyoma.

TREATMENT

All cases underwent TLH, that was carried out following a procedure already described in our previous studies[23]. The description of TLH technique is outside the scope of the study and it is not reported in the video. All three patients underwent extracorporeal intrauterine morcellation according to the technique described below. The video 1 describes in detail the procedure carried out in each patient.

Detailed description of extracorporeal intrauterine morcellation technique

An accessory abdominal very-low or periumbilical transverse mini-laparotomy port site incision ranging from 4–9 cm depending on the uterine size was made. The uterine cervix was extracted from the mini-laparotomy and a wide trachelectomy was completed. Four traction forceps were placed at the four corners of the uterus to gradually extract the uterus through the minilaparotomy during the procedure. Then, we proceeded to gradual manual morcellation with cold scalpel, using the outermost layer of the uterus as a bag. The uterine myomas/tissue was gradually morcellated with caution and repeatedly exploring the depth of the uterine cavity. Morcellation continued till the uterus could be safely and entirely extracted by the minilaparotomy. During the procedure, the removed specimens were also sent immediately for an extemporaneous histological examination, which is routinely being performed during our surgical procedures. To verify the maintenance of the integrity of the uterine wall during morcellation, once removed the uterus was filled with water, thus confirming its capacity of a safe containment as a bag (video 1 and [Figure 1](#)). Following the suture of the accessory low mini-laparotomy, we laparoscopically assessed the abdominal cavity for any blood loss and organ injury and many times washed it carefully to remove any potential remaining tissue.

OUTCOME AND FOLLOW-UP

The procedures were performed without any complications in all patients. All three patients had uneventful postoperative courses. Pathological examination revealed benign leiomyoma in all cases.

DISCUSSION

A crucial condition for TLH in the presence of a large uterus is morcellation, during which larger specimens are broken into little fragment to remove them from the abdominal cavity *via* small incisions. However, intracorporeal uncontained morcellation may lead to unintentional peritoneal dissemination of occult cancers. To avoid such risk, the utilization of contained in-bag morcellation has been developed[3,19,24-26]. However, the usage of containment bags is limited to a determined uterine weight [27]. At this regard, a study reported successful in-bag contained procedures of power morcellation for samples varying from 300 to 2134 g, with no bag rupture or bag-associated complications[14]. To date, few studies tested the use of in-bag contained extracorporeal manual morcellation for large uteri after TLH, with the largest specimen weighing 1930 g[20,28]. In case of very large specimen, mostly single case reports, educational video articles and retrospective series with different technique and investigational devices have been reported[13,29,30]. To address these concerns, we developed an additional alternative technique of extracorporeal intrauterine morcellation carried out within the uterus utilizing its outer wall as a bag. The present video shows that such a technique is safe, feasible, and reproducible. It may allow to maintain the advantages of a minimally invasive approach while trying to lessen the risk of spreading throughout TLH. The final step of the procedure reported in the video confirmed the capability to preserve the integrity of the uterine wall during the cautious manual intrauterine morcellation and gradual uterus extraction. Our technique is comparable in term of outcomes (spillage, visually detectable rupture of containment system, or complications) with the other contained extracorporeal manual morcellation approaches described in literature[20]. The main challenge of our procedure could be the longest timing needed to perform the morcellation and extraction. Thus, our technique may represent a valid alternative to the other procedures of contained morcellation and be especially useful in cases of very large uteri exceeding the capacity of specimen retrieval bags. It cannot represent the only

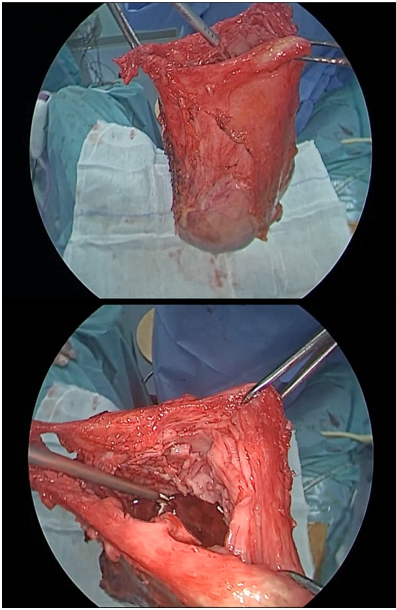


Figure 1 Evaluation of uterine wall integrity after uterus removal.

method applicable for morcellation and the gynecological surgeons should be also familiar with the other techniques.

CONCLUSION

We believe that such a novel technique presented herein may be useful to the readers who may consider adopting it in their practice, by adding it to the other available methods of contained morcellation. Further scientific evaluation of this technique in larger prospective studies is warranted.

ACKNOWLEDGEMENTS

The authors thank Dr. Martina Mura for her technical support.

REFERENCES

- 1 **Glaser LM**, Friedman J, Tsai S, Chaudhari A, Milad M. Laparoscopic myomectomy and morcellation: A review of techniques, outcomes, and practice guidelines. *Best Pract Res Clin Obstet Gynaecol* 2018; **46**: 99-112 [PMID: 29078975 DOI: 10.1016/j.bpobgyn.2017.09.012]
- 2 **Adelman MR**. The Morcellation Debate: The History and the Science. *Clin Obstet Gynecol* 2015; **58**: 710-717 [PMID: 26512438 DOI: 10.1097/GRF.0000000000000150]
- 3 **Kho KA**, Brown DN. Surgical Treatment of Uterine Fibroids Within a Containment System and Without Power Morcellation. *Clin Obstet Gynecol* 2016; **59**: 85-92 [PMID: 26670832 DOI: 10.1097/GRF.0000000000000168]
- 4 **Ghezzi F**, Casarin J, De Francesco G, Puggina P, Uccella S, Serati M, Cromi A. Transvaginal contained tissue extraction after laparoscopic myomectomy: a cohort study. *BJOG* 2018; **125**: 367-373 [PMID: 28467660 DOI: 10.1111/1471-0528.14720]
- 5 **Senapati S**, Tu FF, Magrina JF. Power morcellators: a review of current practice and assessment of risk. *Am J Obstet Gynecol* 2015; **212**: 18-23 [PMID: 25072737 DOI: 10.1016/j.ajog.2014.07.046]
- 6 **McCarthy M**. US agency warns against morcellation in hysterectomies and myomectomies. *BMJ* 2014; **348**: g2872 [PMID: 24755656 DOI: 10.1136/bmj.g2872]
- 7 The FDA recommends performing contained morcellation in women when laparoscopic power morcellation is appropriate. [cited 2 February 2020] Available from: URL: <https://www.fda.gov/medical-devices/safetycommunications/update-fda-recommends-performing-contained-morcellation-women-when-laparoscopic-power-morcellation>
- 8 **Clark NV**, Cohen SL. Tissue Extraction Techniques During Laparoscopic Uterine Surgery. *J Minim Invasive Gynecol* 2018; **25**: 251-256 [PMID: 28866098 DOI: 10.1016/j.jmig.2017.07.030]

- 9 **Shibley KA**. Enclosed morcellation using a large bowel isolation bag. *OBG Manag* 2014; 26
- 10 **Einarsson JI**, Cohen SL, Fuchs N, Wang KC. In-bag morcellation. *J Minim Invasive Gynecol* 2014; 21: 951-953 [PMID: 24769447 DOI: 10.1016/j.jmig.2014.04.010]
- 11 **McKenna JB**, Kanade T, Choi S, Tsai BP, Rosen DM, Cario GM, Chou D. The Sydney Contained In Bag Morcellation technique. *J Minim Invasive Gynecol* 2014; 21: 984-985 [PMID: 25048565 DOI: 10.1016/j.jmig.2014.07.007]
- 12 **Cohen SL**, Einarsson JI, Wang KC, Brown D, Boruta D, Scheib SA, Fader AN, Shibley T. Contained power morcellation within an insufflated isolation bag. *Obstet Gynecol* 2014; 124: 491-497 [PMID: 25162248 DOI: 10.1097/AOG.0000000000000421]
- 13 **Srouji SS**, Kaser DJ, Gargiulo AR. Techniques for contained morcellation in gynecologic surgery. *Fertil Steril* 2015; 103: e34 [PMID: 25712576 DOI: 10.1016/j.fertnstert.2015.01.022]
- 14 **Steller C**, Cholkeri-Singh A, Sasaki K, Miller CE. Power Morcellation Using a Contained Bag System. *JSLs* 2017; 21 [PMID: 28352146 DOI: 10.4293/JSLs.2016.00095]
- 15 **Winner B**, Porter A, Velloze S, Biest S. Uncontained Compared With Contained Power Morcellation in Total Laparoscopic Hysterectomy. *Obstet Gynecol* 2015; 126: 834-838 [PMID: 26348168 DOI: 10.1097/AOG.0000000000001039]
- 16 **Vargas MV**, Cohen SL, Fuchs-Weizman N, Wang KC, Manoucheri E, Vitonis AF, Einarsson JI. Open power morcellation vs contained power morcellation within an insufflated isolation bag: comparison of perioperative outcomes. *J Minim Invasive Gynecol* 2015; 22: 433-438 [PMID: 25452122 DOI: 10.1016/j.jmig.2014.11.010]
- 17 **Mynbaev OA**, Sparic R, Stark M, Malvasi A, Marinelli E, Zaami S, Tinelli A. The Medical Device Applied to Uterine Fibroids Morcellation: Analysis of Critical Biological Issues and Drawbacks from A Medical-Legal Prospective. *Curr Pharm Des* 2020; 26: 318-325 [PMID: 32013843 DOI: 10.2174/1381612826666200204093737]
- 18 **Rimbach S**, Holzknecht A, Schmedler C, Nemes C, Offner F. First clinical experiences using a new in-bag morcellation system during laparoscopic hysterectomy. *Arch Gynecol Obstet* 2016; 294: 83-93 [PMID: 26690354 DOI: 10.1007/s00404-015-3986-5]
- 19 **Paul PG**, Thomas M, Das T, Patil S, Garg R. Contained Morcellation for Laparoscopic Myomectomy Within a Specially Designed Bag. *J Minim Invasive Gynecol* 2016; 23: 257-260 [PMID: 26260302 DOI: 10.1016/j.jmig.2015.08.004]
- 20 **Serur E**, Zambrano N, Brown K, Clemetson E, Lakhi N. Extracorporeal Manual Morcellation of Very Large Uteri Within an Enclosed Endoscopic Bag: Our 5-Year Experience. *J Minim Invasive Gynecol* 2016; 23: 903-908 [PMID: 27058770 DOI: 10.1016/j.jmig.2016.03.016]
- 21 **Venturella R**, Rocca ML, Lico D, La Ferrera N, Cirillo R, Gizzo S, Morelli M, Zupi E, Zullo F. In-bag manual vs uncontained power morcellation for laparoscopic myomectomy: randomized controlled trial. *Fertil Steril* 2016; 105: 1369-1376 [PMID: 26801067 DOI: 10.1016/j.fertnstert.2015.12.133]
- 22 **AAGL Advancing Minimally Invasive Gynecology Worldwide**. AAGL practice report: Morcellation during uterine tissue extraction. *J Minim Invasive Gynecol* 2014; 21: 517-530 [PMID: 24865630 DOI: 10.1016/j.jmig.2014.05.010]
- 23 **Macciò A**, Chiappe G, Kotsonis P, Lavra F, Sanna E, Collu I, Nemolato S, Madeddu C. Feasibility and safety of total laparoscopic hysterectomy for uteri weighing from 1.5 kg to 11.000 kg. *Arch Gynecol Obstet* 2021; 303: 169-179 [PMID: 32949285 DOI: 10.1007/s00404-020-05799-6]
- 24 **Cholkeri-Singh A**, Miller CE. Power morcellation in a specimen bag. *J Minim Invasive Gynecol* 2015; 22: 160 [PMID: 25460317 DOI: 10.1016/j.jmig.2014.10.012]
- 25 **Walid MS**, Heaton RL. Use of bowel bags in gynecologic laparoscopy. *Arch Gynecol Obstet* 2009; 279: 777-779 [PMID: 19151992 DOI: 10.1007/s00404-008-0923-x]
- 26 **Zullo F**, Venturella R, Raffone A, Saccone G. In-bag manual vs uncontained power morcellation for laparoscopic myomectomy. *Cochrane Database Syst Rev* 2020; 5: CD013352 [PMID: 32374421]
- 27 **Ark C**, Güngördük K, Celebi I, Celikkol O. Experience with laparoscopic-assisted vaginal hysterectomy for the enlarged uterus. *Arch Gynecol Obstet* 2009; 280: 425-430 [PMID: 19184075 DOI: 10.1007/s00404-009-0944-0]
- 28 **Husslein H**, Frecker H, Shore E, Satkunaratnam A, Lefebvre G. Comparing Two Devices of Uterine Manipulation and Vaginal Fornix Delineation at Total Laparoscopic Hysterectomy - Preliminary Results. *J Minim Invasive Gynecol* 2015; 22: S107 [PMID: 27678577 DOI: 10.1016/j.jmig.2015.08.289]
- 29 **Cesta M**, Kennedy B, Pasic R. Total Laparoscopic Hysterectomy of a 7400 g Uterus. *J Minim Invasive Gynecol* 2021; 28: 748-749 [PMID: 32610076 DOI: 10.1016/j.jmig.2020.06.019]
- 30 **Haber HR**, Namazi G, Pepin K, Einarsson JI. Minimally Invasive Surgical Techniques for Tissue Extraction. *J Minim Invasive Gynecol* 2021; 28: 388 [PMID: 32882408 DOI: 10.1016/j.jmig.2020.08.021]



Published by **Baishideng Publishing Group Inc**
7041 Koll Center Parkway, Suite 160, Pleasanton, CA 94566, USA
Telephone: +1-925-3991568
E-mail: bpgoffice@wjgnet.com
Help Desk: <https://www.f6publishing.com/helpdesk>
<https://www.wjgnet.com>

