




Diagnostic accuracy of transvaginal sonography for detecting parametrial involvement in women with deep endometriosis: systematic review and meta-analysis

S. GUERRIERO¹ , L. MARTINEZ², I. GOMEZ³, M. A. PASCUAL⁴ , S. AJOSSA⁵, M. PAGLIUCA⁵ and J. L. ALCÁZAR⁶ 

¹Centro Integrato di Procreazione Medicalmente Assistita (PMA) e Diagnostica Ostetrico-Ginecologica, Policlinico Universitario Duilio Casula, Monserrato, and University of Cagliari, Cagliari, Italy; ²Department of Gynecology, Reina Sofia University Hospital, Murcia, Spain; ³Department of Obstetrics and Gynecology, Virgen de la Arrixaca University Hospital, Murcia, Spain; ⁴Department of Obstetrics, Gynecology and Reproduction, Hospital Universitari Dexeus, Barcelona, Spain; ⁵Department of Obstetrics and Gynecology, University of Cagliari, Policlinico Universitario Duilio Casula, Cagliari, Italy; ⁶Department of Obstetrics and Gynecology, Clínica Universidad de Navarra, Pamplona, Spain

KEYWORDS: endometriosis; parametrium; transvaginal ultrasound

CONTRIBUTION

What are the novel findings of this work?

This is the first meta-analysis to evaluate the diagnostic accuracy of transvaginal sonography for detecting parametrial deep endometriosis. Visualization of a lesion suspected to be parametrial deep endometriosis on transvaginal sonography increased significantly the post-test probability of parametrial deep endometriosis. However, the number and quality of the included studies were moderate.

What are the clinical implications of this work?

The findings of this systematic review highlight the importance of assessing the parametrium in women with suspected deep endometriosis, as well as the current limitations of such assessment. Further studies are necessary to define more accurately the ultrasound criteria that should be used for evaluating parametrial involvement, as well as the technique and its reproducibility.

ABSTRACT

Objective To evaluate the accuracy of transvaginal sonography (TVS) for detecting parametrial deep endometriosis, using laparoscopy as the reference standard.

Methods A search was performed in PubMed/MEDLINE and Web of Science for studies evaluating TVS for detecting parametrial involvement in women with

suspected deep endometriosis, as compared with laparoscopy, from January 2000 to December 2020. The Quality Assessment of Diagnostic Accuracy Studies-2 (QUADAS-2) tool was used to evaluate the quality of the studies. Pooled sensitivity, specificity and positive and negative likelihood ratios for TVS in the detection of parametrial deep endometriosis were calculated, and the post-test probability of parametrial deep endometriosis following a positive or negative test was determined.

Results The search identified 134 citations. Four studies, comprising 560 patients, were included in the analysis. The mean prevalence of parametrial deep endometriosis at surgery was 18%. Overall, the pooled estimated sensitivity, specificity and positive and negative likelihood ratios of TVS in the detection of parametrial deep endometriosis were 31% (95% CI, 10–64%), 98% (95% CI, 95–99%), 18.5 (95% CI, 8.8–38.9) and 0.70 (95% CI, 0.46–1.06), respectively. The diagnostic odds ratio was 26 (95% CI, 10–68). Heterogeneity was high. Visualization of a lesion suspected to be parametrial deep endometriosis on TVS increased significantly the post-test probability of parametrial deep endometriosis.

Conclusion TVS has high specificity but low sensitivity for the detection of parametrial deep endometriosis. © 2021 The Authors. *Ultrasound in Obstetrics & Gynecology* published by John Wiley & Sons Ltd on behalf of International Society of Ultrasound in Obstetrics and Gynecology.

Correspondence to: Prof. J. L. Alcázar, Department of Obstetrics and Gynecology, Clínica Universidad de Navarra, Avenida Pío XII 36, 3110 Pamplona, Spain (e-mail: jlalcazar@unav.es)

Accepted: 28 July 2021

INTRODUCTION

Transvaginal sonography (TVS) is the first-line imaging technique for diagnosing deep endometriosis in several locations of the pelvis^{1,2}, with different accuracies depending on the location^{3–6}. In 2016, a consensus opinion from the International Deep Endometriosis Analysis (IDEA) group was published, proposing standardized ultrasonographic characteristics of deep endometriosis in different pelvic locations⁷. A systematic four-step approach was proposed for the examination of women with suspected deep endometriosis, but sonographic evaluation of the lateral compartment (i.e. the parametrium) was not included owing to the scarcity of studies on this topic at the time of drafting the consensus.

However, from a surgical point of view, a parametrial deep endometriotic lesion represents a severe form of disease that is frequently associated with ureteral stenosis and requires complex, usually multidisciplinary, surgery with a high risk of intra- and postoperative complications^{8–11}. For these reasons, preoperative assessment of this compartment is desirable. According to the study of Exacoustos *et al.*¹², parametrial involvement is suggested when infiltrating, irregular, hypoechogenic tissue extending laterally to the cervix or vagina can be seen on TVS.

To the best of our knowledge, no meta-analysis has been published regarding the role of ultrasonography in the diagnosis of deep endometriosis of the lateral compartment. The aim of the present systematic review was to evaluate the diagnostic accuracy of TVS in detecting parametrial deep endometriosis, using laparoscopy as the reference standard.

METHODS

Protocol and registration

This systematic review and meta-analysis was performed according to Synthesizing Evidence from Diagnostic Accuracy TESts (SEDATe) guidelines and the Preferred Reporting Items for Systematic Reviews and Meta-Analyses (PRISMA) statement^{13,14}. All methods regarding inclusion/exclusion criteria, data extraction and quality assessment were specified *a priori*. The protocol did not require registration, and institutional review board approval was waived owing to the study's nature and design.

Data sources and search

Two of the authors (I.G., L.M.) searched two electronic databases (PubMed/MEDLINE and Web of Science) to identify potentially eligible studies published between January 2000 and December 2020. The search terms were as follows: 'endometriosis', 'endometriotic', 'parametrium', 'parametrial', 'pelvic side wall', 'broad ligament', 'ultrasound', 'sonography' and 'echography'. No language restriction was set.

Although the terms 'pelvic side wall' and 'broad ligament' are not synonyms for 'parametrium', we

decided to use these terms in the search strategy since the parametrium is bordered laterally by the pelvic wall¹⁵ and the broad ligament is related anatomically to the parametrium at the level of the inferior mesometrium^{16,17}.

Study selection and data collection process

Three authors (J.L.A., I.G., L.M.) screened the titles and abstracts of identified articles in order to exclude those that were irrelevant, i.e. studies not strictly related to the topic of the review, such as those that used magnetic resonance imaging (MRI) instead of ultrasound as the diagnostic method or those that did not use laparoscopy as the reference standard, reviews, letters to the editor and case reports. The full texts of relevant articles were then obtained, and the reviewers applied independently the following inclusion criteria: (1) prospective or retrospective cohort study with at least 20 women included (sample size was set arbitrarily); (2) participants were premenopausal women with clinical suspicion of deep endometriosis; (3) the index test was TVS performed by an expert sonologist; (4) laparoscopy with or without pathological correlation was used as the reference standard; and (5) the reported data were sufficient to construct a 2 × 2 table of diagnostic performance as a minimum data requirement.

Studies that assessed endometriosis involving the urinary tract were not considered for this meta-analysis. The 'snowball strategy' was used to identify potentially relevant papers from the reference lists of those selected for full-text assessment. In cases of missing relevant data, we sought to contact the authors to request this information.

The Patients, Intervention, Comparator, Outcomes, Study design (PICOS) criteria were used to describe the included studies. Diagnostic accuracy results and additional useful information about patients and procedures were retrieved independently from the selected primary studies by four of the authors (J.L.A., S.G., I.G., L.M.). Disagreements in the process of study selection and data collection were resolved by consensus among all the authors.

Risk of bias in individual studies

Quality assessment was carried out using the Quality Assessment of Diagnostic Accuracy Studies-2 (QUADAS-2) tool, adapted for use in this meta-analysis. The QUADAS-2 tool includes four domains: (1) patient selection; (2) index test; (3) reference standard; and (4) flow and timing. For each domain, the risk of bias and concerns regarding applicability were classified as high, low or unclear. The results of quality assessment were used for descriptive purposes to evaluate the overall quality of the included studies and to investigate potential sources of heterogeneity. Three authors (J.L.A., I.G., L.M.) assessed independently the methodological quality, using a standard form with quality assessment criteria and a flow diagram; disagreements were resolved by

discussion to reach a consensus. The authors determined the risk of selection bias based on the description of the inclusion and exclusion criteria of the studies. The descriptions of the technique for diagnosing affected parametrium and its reproducibility provided in the studies were assessed in order to classify the index-test domain. For evaluation of the reference-standard domain, the method that the study used to determine the presence of deep endometriosis in the parametrium was assessed. For evaluation of the flow-and-timing domain, the description of the time elapsed between the index-test assessment and the reference-standard result was evaluated.

GRADE assessment

We used the Grading of Recommendations Assessment, Development and Evaluation (GRADE) methodology for assessing the quality of the body of retrieved evidence. The online GRADE tool was used (<http://GRADEPro.org>; accessed 23 April 2021).

Statistical analysis

Data on the diagnosis of parametrial involvement performed using TVS were extracted or derived from the included studies, considering the test to be positive when infiltrating, irregular, hypoechoic tissue extending laterally to the cervix or vagina was observed, and negative when those structures were completely free of lesion. The reference standard was endometrial tissue found in at least one resected lesion in the parametrium or direct visualization of a deep endometriotic lesion in the parametrium at laparoscopy.

The primary outcome was the pooled sensitivity, specificity and positive and negative likelihood ratios (LR+ and LR-) of TVS in the detection of parametrial deep endometriosis. True-positive, true-negative, false-positive and false-negative values were obtained from each study. Post-test probabilities were calculated and plotted on Fagan nomograms.

The presence of heterogeneity in sensitivity and specificity was assessed graphically, by plotting forest plots, as well as using Cochran's Q statistic and the I^2 index. Tests for heterogeneity examine the null hypothesis that all studies are evaluating the same effect; $P < 0.1$ indicates heterogeneity. According to Higgins *et al.*¹⁸, I^2 values of 25%, 50% and 75% are considered to indicate low, moderate and high heterogeneity, respectively. A summary receiver-operating-characteristics (sROC) curve was plotted to illustrate the relationship between sensitivity and specificity.

Statistical analysis was performed using Meta-analytical Integration of Diagnostic Accuracy Studies (MIDAS) and METANDI commands in Stata version 12 for Windows (StataCorp., College Station, TX, USA). $P < 0.05$ was considered to indicate statistical significance.

RESULTS

Search results

A flowchart summarizing literature identification and selection of studies is given in Figure 1. The electronic search identified a total of 134 citations (121 in PubMed and 13 in Web of Science). After removal of five duplicate records, 129 citations remained. Of these, 120 were excluded because they were a review ($n = 22$), a case report ($n = 37$), a letter to the editor ($n = 1$), an opinion ($n = 1$), a correspondence ($n = 1$) or were not relevant ($n = 58$). We examined the full text of the remaining nine articles. Three studies were selected^{12,19,20} and six studies were excluded because deep endometriosis of the parametrium was not assessed ($n = 4$) or no data were available on the sensitivity of TVS for deep endometriosis of the parametrium ($n = 2$). One additional relevant study was identified from the references cited in the included studies identified from the electronic search (snowball technique)²¹. Therefore, four studies were finally included in the analysis^{12,19-21}. All included studies analyzed the accuracy of preoperative TVS in the prediction of parametrial involvement in women with suspected deep

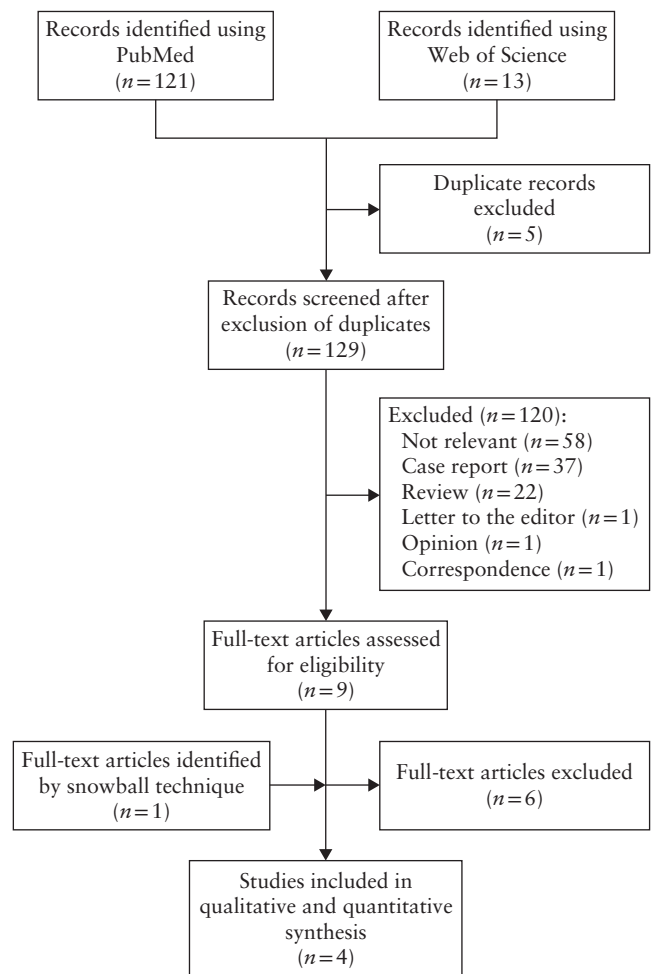


Figure 1 Flowchart summarizing selection of studies evaluating the diagnostic accuracy of transvaginal sonography for parametrial involvement in women with suspected deep endometriosis.

endometriosis. There was no need to contact the authors for any of the studies, as all relevant data to perform the meta-analysis were available.

Characteristics of included studies

Table 1 shows the PICOS characteristics of the four included studies. The studies were published between 2013 and 2021 and reported on 560 patients. Among these 560 patients, 110 had parametrial involvement at laparoscopy, with or without pathological correlation. When considering hemipelvs as the unit of analysis, 1120 hemipelvs were included, of which 126 had a lesion in the parametrium diagnosed at laparoscopy, with or without pathological correlation. The mean prevalence of deep endometriosis of the parametrium at surgery was 17.5% (range, 2.5–35.0%).

The mean age of the patients was reported in all four studies^{12,19–21}. Two studies were observational prospective studies and two were retrospective. Two of the studies were multicenter^{12,19}. None of the four studies specified whether patient recruitment was consecutive.

The method for diagnosing parametrial involvement was the presence of an echogenic tissue area extending laterally to the cervix or vagina on TVS performed by an expert sonologist. However, in two studies, the

sonologists did not specifically describe the lesion as being in the parametrium, instead referring to the pelvic side wall¹⁹ or broad ligament²¹. In three of the studies, there was just one observer^{12,20,21}, while in the other study¹⁹, two different observers performed the ultrasound examinations. In all four studies, the reference standard was laparoscopic findings.

The interval between TVS and surgery was specified in three of the studies. In one study¹², surgery was performed within 3 months after ultrasound evaluation and in another it was performed within 2 weeks²¹. In the other study, the mean interval between TVS and surgery was 139 days (range, 1–385 days)²⁰.

Methodological quality of included studies

The results of the evaluation of the risk of bias and concerns regarding applicability of the included studies, according to the QUADAS-2 tool, are summarized in Figure 2. Two studies were considered to have a high risk for patient selection bias^{12,21}. In one of these studies, only patients who were scheduled to undergo surgery were included²¹ and the authors selected retrospectively only those sonographic examinations that were performed by a radiologist who was highly experienced in gynecological imaging. In the second study, patients without deep

Table 1 Characteristics of studies included in systematic review evaluating the diagnostic accuracy of transvaginal sonography (TVS) for detecting parametrial involvement in women with suspected deep endometriosis, according to PICOS criteria

Study	Study design	Multicenter	Consecutive patient selection	Mean age (years)	Patients (n)	Hemipelvs (n)	Parametrium affected (n/N)	Index test	Observers (n)	Reference standard	Surgeons blinded
Holland (2013) ¹⁹	Prospective	Yes	NS	35	198	396	13/396	TVS	2	LPS only	Yes
Exacoustos (2014) ¹²	Prospective	Yes	NS	35.6	104	208	61/208	TVS	1	LPS + P	No
Yin (2020) ²¹	Retrospective	No	NS	35.4	198	396	10/396	TVS	1	LPS*	NS
Bazot (2021) ²⁰	Retrospective	No	NS	33	60	120	42/120	TVS	1	LPS + P	No

Only first author of each study is given. *Study did not specify whether diagnosis was confirmed by pathological correlation (P). LPS, laparoscopy; NS, not stated; PICOS, Patients, Intervention, Comparator, Outcomes, Study design.

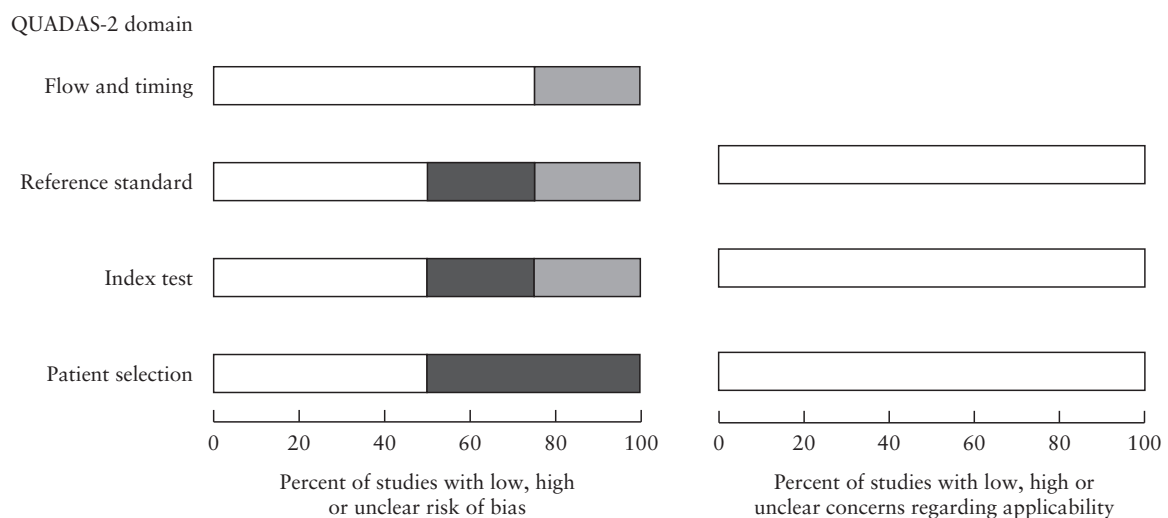


Figure 2 Summary of quality assessment (risk of bias and concerns regarding applicability) for studies included in the meta-analysis, according to the Quality Assessment of Diagnostic Accuracy Studies-2 (QUADAS-2) tool. □, low risk; ■, high risk; ▒, unclear risk.

endometriosis observed on ultrasound were excluded¹². The designs of these two studies could increase the number of false positives owing to patients with more severe disease, according to either ultrasound diagnosis or requirement for surgery, being included. Regarding the inclusion criteria, all studies included patients with clinical suspicion of deep endometriosis (mainly owing to chronic pelvic pain, dysmenorrhea, dyspareunia, dyschezia or dysuria) with or without a history of endometriosis, who underwent operative laparoscopy for this reason. Regarding the exclusion criteria, three studies^{12,20,21} did not state an age limit, while the other study¹⁹ required patients to be at least 16 years old and premenopausal. All patients in the four studies underwent a TVS scan, with patients who could not undergo TVS excluded specifically in one study²⁰. Two studies^{19,21} excluded specifically women who became pregnant while awaiting surgery.

For the index test, only two studies described correctly and adequately the characteristics that they considered to indicate parametrial involvement and were therefore considered low risk^{12,20}. One study was considered to have an unclear risk, as the characteristics were not described appropriately¹⁹. The remaining study was considered high risk because the parametrium was specified as the broad ligament without describing identification of the structure²¹. In all studies, the TVS examination was performed at any phase of the menstrual cycle, regardless of hormonal therapy, and the examiners had a high level of expertise^{12,19–21} or had received professional training²¹. In two of the studies^{20,21}, the examiners were blinded to the findings from the physical examination and previous imaging examinations.

Concerning the flow-and-timing domain, the time elapsed between the index test and the reference standard was reported in three of the four studies, which were therefore considered as low risk^{12,20,21}. The remaining study had an unclear risk, as it did not specify the time interval¹⁹.

For the reference test, the diagnostic performance of direct or indirect ultrasound criteria was evaluated with respect to its correlation with surgical findings. In all the studies, the surgeons had extensive experience in radical laparoscopic resection of deep endometriosis. Two of the four studies^{12,20} selected women who underwent surgery followed by pathological biopsy correlation and were therefore considered low risk. One study was considered to have an unclear risk, as it did not specify whether the diagnosis was confirmed by pathological correlation²¹. In the other study¹⁹, confirmation was obtained only by surgery and it was therefore considered high risk.

Regarding applicability, all studies were deemed to include patients that matched the review question. For the index-test domain, all four studies were considered to have low concerns for applicability, as the index test was described sufficiently for study replication. All studies presented low concerns regarding the reference-standard domain.

Diagnostic accuracy of TVS for deep endometriotic parametrial involvement

The overall sensitivity and specificity of TVS were evaluated in all studies to determine the pooled sensitivity, specificity, LR+ and LR– of TVS in diagnosing deep endometriosis of the parametrium. The respective values were 31% (95% CI, 10–64%), 98% (95% CI, 95–99%), 18.5 (95% CI, 8.8–38.9) and 0.70 (95% CI, 0.46–1.06) (Figure 3). The diagnostic odds ratio was 26 (95% CI, 10–68). Heterogeneity was high for both sensitivity (Cochran's $Q = 31.39$, $P < 0.001$; $I^2 = 90.44\%$) and specificity (Cochran's $Q = 22.04$, $P < 0.001$; $I^2 = 86.39\%$). The 95% CI was wide for sensitivity but acceptable for specificity. Despite finding high heterogeneity, meta-regression was not used owing to the limited number of studies. The sROC curve is shown in Figure 4; the area under the curve was 0.94 (95% CI, 0.92–0.96).

The Fagan nomogram showed that a positive result on TVS in women with suspected deep endometriosis

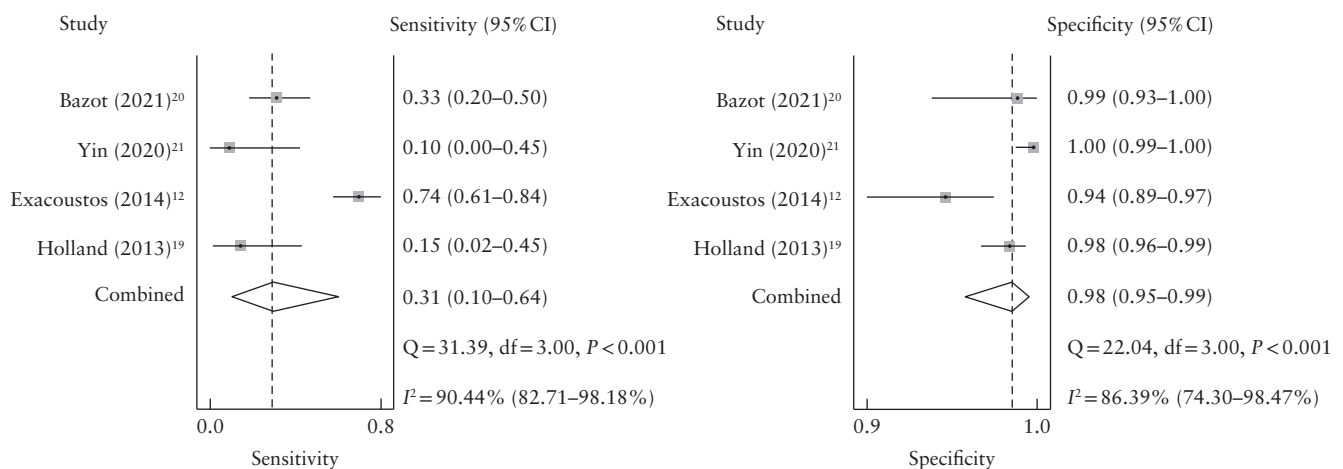


Figure 3 Forest plots of sensitivity and specificity of transvaginal sonography in the detection of parametrial involvement in women with suspected deep endometriosis.

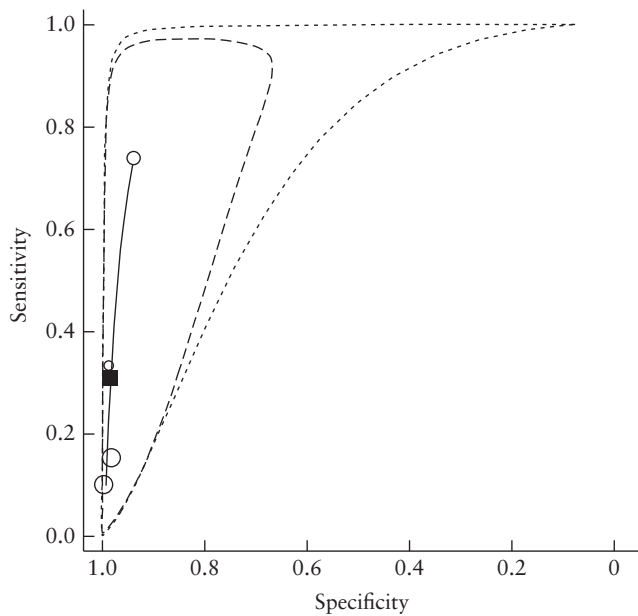


Figure 4 Hierarchical summary receiver-operating-characteristics curve (—) for transvaginal sonography in detecting parametrial involvement in women with suspected deep endometriosis. O, study estimate; ■, summary point; - - - - , 95% prediction region; - · - · , 95% confidence region.

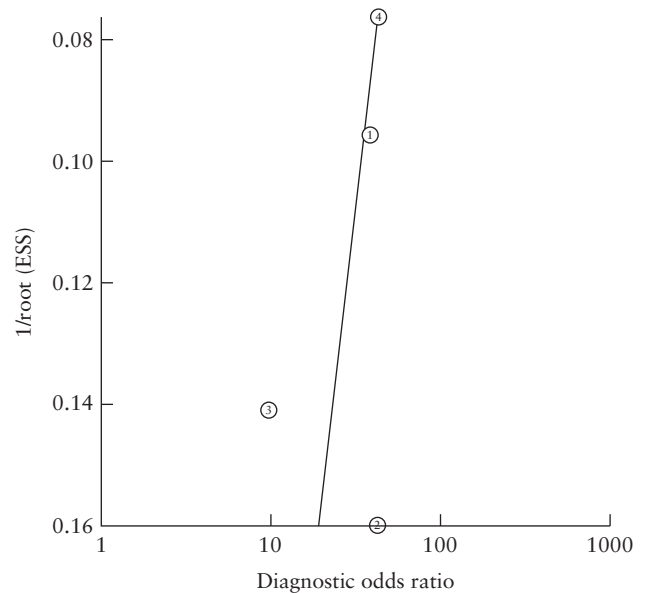


Figure 6 Funnel plot for assessment of publication bias in studies evaluating the diagnostic accuracy of transvaginal sonography for detecting parametrial involvement in women with suspected deep endometriosis. O, study; —, regression line; Deeks' funnel plot asymmetry test $P = 0.44$. ESS, effective sample size.

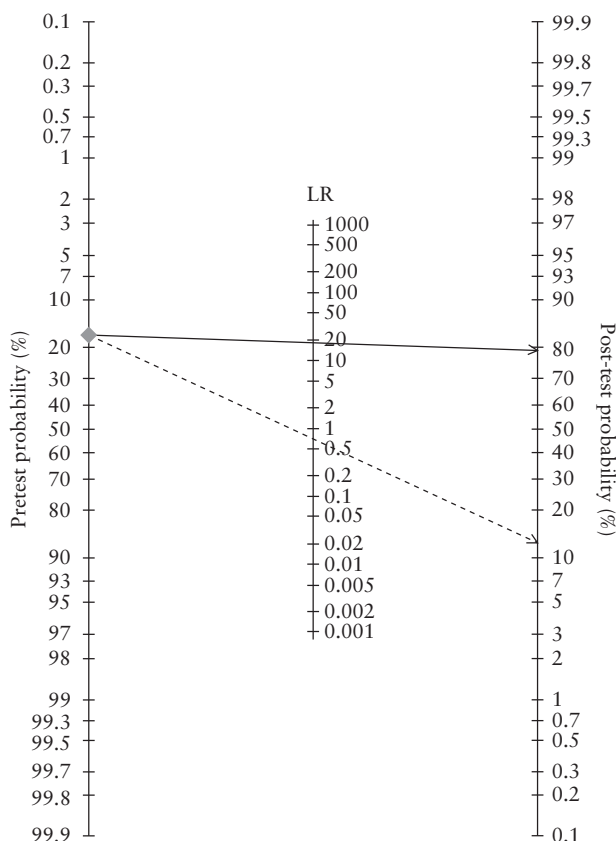


Figure 5 Fagan's nomogram for transvaginal sonography (TVS) in detecting parametrial involvement in women with suspected deep endometriosis. The prior probability \blacklozenge was 18%. The post-test probability was 79% following a positive TVS result (—→; positive likelihood ratio (LR) of 19) and 13% following a negative TVS result (- - -→; negative LR of 0.70).

increased significantly the post-test probability of deep endometriotic parametrial involvement, from 18% to 79%, while a negative test decreased the post-test probability only slightly, from 18% to 13% (Figure 5). No publication bias was observed (Figure 6).

DISCUSSION

Summary of evidence

In this meta-analysis, we observed that the diagnostic performance of TVS for deep endometriotic parametrial involvement in women with suspected deep endometriosis was moderate, with a pooled sensitivity of 31% and a pooled specificity of 98%.

Interpretation of results

Parametrial deep endometriosis can be associated with infiltration of the ureters and represents a critical factor for the complexity of the surgery and perioperative morbidity in women with deep infiltrating endometriosis requiring surgery^{11,15,22}. Preoperative assessment of parametrial involvement is important for optimizing preoperative counseling and informed consent (with regard to the risk of postoperative bladder dysfunction), as well as ensuring that expert surgeons are involved during the surgery¹⁵. Moreover, Touboul *et al.*²³ emphasized that the ureteral path running through the parametrium represents a surgical risk factor, with an increased incidence of injury to the lower urinary tract.

Despite the substantial impact of parametrial deep endometriosis, only a few studies have evaluated its diagnosis, prevalence and clinical features^{12,19-21}. Even

in the most recent consensus opinion from the IDEA group, which presents a systematic approach to the sonographic evaluation of the pelvis in women with suspected endometriosis, parametrial involvement is not mentioned⁷. Our data confirm the limited number of studies addressing the diagnostic accuracy of ultrasound for parametrial involvement in women with suspected deep endometriosis. In addition, the studies included in this meta-analysis were heterogeneous and of moderate quality.

Our results reveal that TVS has high specificity but low sensitivity for the detection of parametrial deep endometriosis. Data on parametrial involvement in other clinical situations, such as in cervical cancer, have also been reported. A recent meta-analysis reported that the diagnostic accuracy of ultrasound for parametrial involvement in cervical cancer was moderate (sensitivity, 0.78; specificity, 0.96) and comparable with the performance of MRI (sensitivity, 0.70; specificity, 0.93)²⁴.

Although we did not include in our meta-analysis studies assessing the role of MRI in detecting parametrial involvement in deep endometriosis, reports have shown that MRI has good diagnostic performance, with higher sensitivity than that of ultrasound reported in this meta-analysis²⁵. There is therefore substantial room for improvement in the performance of ultrasound diagnosis, particularly in its sensitivity for parametrial involvement in the context of deep endometriosis.

These issues in the sonographic evaluation of parametrial involvement in women with suspected deep endometriosis prompt the need to: (1) standardize the exploratory technique, which provides a method for clear visualization of deep endometriotic parametrial lesions; (2) establish common terminology for describing the anatomy on imaging and at surgery in order to overcome discrepancies in clinical and research settings and to explain how to diagnose accurately the presence of lesions in the parametrium; (3) investigate the reproducibility of sonographic evaluation of the parametrium; and (4) assess the learning curves of trainees during a structured offline or hands-on training program for the ultrasonographic diagnosis of parametrial involvement.

Strengths and limitations

The strength of this meta-analysis resides in the fact that, to the best of our knowledge, it is the first meta-analysis to analyze specifically the diagnostic accuracy of ultrasound for deep endometriotic parametrial involvement.

Several limitations of this meta-analysis should be considered. We believe that the main limitation is the small number of included studies. Two of the included studies used alternative terminology for the parametrium ('pelvic side wall' and 'broad ligament', respectively), and it is unclear how to define accurately deep endometriotic parametrial involvement on ultrasound. Furthermore, diagnosing accurately deep endometriotic parametrial involvement is highly dependent on the examiner's skills and experience, and we should take

into account that not all examiners have high experience in ultrasound²⁶. Similarly, the reported prevalence of parametrial involvement at laparoscopy may vary depending on the surgeon's skills. Although the included studies stated that surgery was performed by experienced surgeons, most did not give details of how thoroughly the parametrium had been evaluated surgically, and we therefore cannot assume that the abdominal cavity was inspected properly.

Conclusions

Parametrial involvement in women with deep endometriosis is an occult and not uncommon condition that reflects a more severe manifestation of the disease and requires more aggressive surgery. Patients should be evaluated thoroughly and counseled properly during the preoperative examination, taking into account the significant associated morbidity, particularly regarding pelvic organ dysfunction. A prospective study establishing a standardized examination technique and precise anatomical terminology would be useful for assessing the actual diagnostic accuracy of ultrasound for parametrial involvement in women with suspected deep endometriosis.

ACKNOWLEDGMENT

This study was partly supported by Fondazione di Sardegna grant F74I19001010007.

REFERENCES

- Piketty M, Chopin N, Dousset B, Millischer-Bellaische AE, Roseau G, Leconte M, Borghese B, Chapron C. Preoperative work-up for patients with deeply infiltrating endometriosis: transvaginal ultrasonography must definitely be the first-line imaging examination. *Hum Reprod* 2009; 24: 602–607.
- Bazot M, Daraï E. Diagnosis of deep endometriosis: clinical examination, ultrasonography, magnetic resonance imaging, and other techniques. *Fertil Steril* 2017; 108: 886–894.
- Guerriero S, Ajossa S, Minguez JA, Jurado M, Mais V, Melis GB, Alcazar JL. Accuracy of transvaginal ultrasound for diagnosis of deep endometriosis in uterosacral ligaments, rectovaginal septum, vagina and bladder: systematic review and meta-analysis. *Ultrasound Obstet Gynecol* 2015; 46: 534–545.
- Nisenblat V, Bossuyt PM, Farquhar C, Johnson N, Hull ML. Imaging modalities for the non-invasive diagnosis of endometriosis. *Cochrane Database Syst Rev* 2016; 2: CD009591.
- Guerriero S, Ajossa S, Orozco R, Perniciano M, Jurado M, Melis GB, Alcazar JL. Accuracy of transvaginal ultrasound for diagnosis of deep endometriosis in the rectosigmoid: systematic review and meta-analysis. *Ultrasound Obstet Gynecol* 2016; 47: 281–289.
- Guerriero S, Saba L, Pascual MA, Ajossa S, Rodriguez I, Mais V, Alcazar JL. Transvaginal ultrasound vs magnetic resonance imaging for diagnosing deep infiltrating endometriosis: systematic review and meta-analysis. *Ultrasound Obstet Gynecol* 2018; 51: 586–595.
- Guerriero S, Condous G, van den Bosch T, Valentin L, Leone FP, Van Schoubroeck D, Exacoustos C, Installé AJ, Martins WP, Abrao MS, Hudelist G, Bazot M, Alcazar JL, Gonçalves MO, Pascual MA, Ajossa S, Savelli L, Dunham R, Reid S, Menakaya U, Bourne T, Ferrero S, Leon M, Bignardi T, Holland T, Jurkovic D, Benacerraf B, Osuga Y, Somigliana E, Timmerman D. Systematic approach to sonographic evaluation of the pelvis in women with suspected endometriosis, including terms, definitions and measurements: a consensus opinion from the International Deep Endometriosis Analysis (IDEA) group. *Ultrasound Obstet Gynecol* 2016; 48: 318–332.
- Ceccaroni M, Clarizia R, Roviglione G, Bruni F, Ruffo G, Peters I, De Placido G, Minelli L. Deep rectal and parametrial infiltrating endometriosis with monolateral pudendal nerve involvement: case report and laparoscopic nerve-sparing approach. *Eur J Obstet Gynecol Reprod Biol* 2010; 153: 227–229.
- Ballester M, Santulli P, Bazot M, Coutant C, Rouzier R, Daraï E. Preoperative evaluation of posterior deep-infiltrating endometriosis demonstrates a relationship with urinary dysfunction and parametrial involvement. *J Minim Invasive Gynecol* 2011; 18: 36–42.

10. Ballester M, Chereau E, Dubernard G, Coutant C, Bazot M, Darai E. Urinary dysfunction after colorectal resection for endometriosis: results of a prospective randomized trial comparing laparoscopy to open surgery. *Am J Obstet Gynecol* 2011; **204**: 303.e1–6.
11. Mabrouk M, Raimondo D, Arena A, Iodice R, Altieri M, Sutherland N, Salucci P, Moro E, Seracchioli R. Parametrial Endometriosis: The Occult Condition that Makes the Hard Harder. *J Minim Invasive Gynecol* 2019; **26**: 871–876.
12. Exacoustos C, Malzoni M, Di Giovanni A, Lazzeri L, Tosti C, Petraglia F, Zupi E. Ultrasound mapping system for the surgical management of deep infiltrating endometriosis. *Fertil Steril* 2014; **102**: 143–150.e2.
13. Moher D, Liberati A, Tetzlaff J, Altman DG; PRISMA Group. Preferred reporting items for systematic reviews and meta-analyses: the PRISMA statement. *BMJ* 2009; **339**: b2535.
14. Sotiriadis A, Papatheodorou SI, Martins WP. Synthesizing Evidence from Diagnostic Accuracy TESts: the SEDATE guideline. *Ultrasound Obstet Gynecol* 2016; **47**: 386–395.
15. Scioscia M, Scardapane A, Virgilio BA, Libera M, Lorusso F, Noventa M. Ultrasound of the Uterosacral Ligament, Parametrium, and Paracervix: Disagreement in Terminology between Imaging Anatomy and Modern Gynecologic Surgery. *J Clin Med* 2021; **10**: 437.
16. Scioscia M. Ureteral endometriosis: correlation between ultrasonography and laparoscopy. *Ultrasound Obstet Gynecol* 2019; **53**: 706–708.
17. Ayra LA, Schwartz N. Female Reproductive System. In *Gray's Anatomy* (41st edn), Stranding S (ed). Elsevier: London, UK, 2016; 1288–1315.
18. Higgins JP, Thompson SG, Deeks JJ, Altman DG. Measuring inconsistency in meta-analyses. *BMJ* 2003; **327**: 557–560.
19. Holland TK, Cutner A, Saridogan E, Mavrelou D, Pateman K, Jurkovic D. Ultrasound mapping of pelvic endometriosis: does the location and number of lesions affect the diagnostic accuracy? A multicentre diagnostic accuracy study. *BMC Womens Health* 2013; **13**: 43.
20. Bazot M, Delaveau M-C, Darai E, Bendifallah S. Value of sonography in assessing parametrial endometriotic involvement: Preliminary results. *J Endometriosis Pelvic Pain Disorders* 2021; **13**: 58–65.
21. Yin S, Lin Q, Xu F, Xu J, Zhang Y. Diagnosis of Deep Infiltrating Endometriosis Using Transvaginal Ultrasonography. *Front Med (Lausanne)* 2020; **7**: 567929.
22. Mariani LL, Mancarella M, Novara L, Biglia N. Sonographic features of endometriosis infiltrating the lateral parametrium. *J Gynecol Obstet Hum Reprod* 2021; **50**: 102116.
23. Touboul C, Fauconnier A, Zareski E, Bouhanna P, Darai E. The lateral infraureteral parametrium: myth or reality? *Am J Obstet Gynecol* 2008; **199**: 242.e1–6.
24. Alcazar JL, García E, Machuca M, Quintana R, Escrig J, Chacón E, Mínguez JA, Chiva L. Magnetic resonance imaging and ultrasound for assessing parametrial infiltration in cervical cancer. A systematic review and meta-analysis. *Med Ultrason* 2020; **22**: 85–91.
25. Bazot M, Jarbouli L, Ballester M, Touboul C, Thomassin-Naggara I, Darai E. The value of MRI in assessing parametrial involvement in endometriosis. *Hum Reprod* 2012; **27**: 2352–2358.
26. Leonardi M, Ong J, Espada M, Stamatopoulos N, Georgousopoulou E, Hudelist G, Condous G. One-Size-Fits-All Approach Does Not Work for Gynecology Trainees Learning Endometriosis Ultrasound Skills. *J Ultrasound Med* 2020; **39**: 2295–2303.