Journal Pre-proof



Oral-ocular trans infection of Epstein Barr virus. A possible new way of transmission by wearing masks in the SARS-CoV-2 era

Enrico Peiretti, Giuseppe Demarinis, Cinzia Casu, Alessandra Scano, Orru' Germano

PII: S2451-9936(22)00372-3

DOI: https://doi.org/10.1016/j.ajoc.2022.101626

Reference: AJOC 101626

To appear in: *American Journal of Ophthalmology Case Reports*

Received Date: 21 October 2021

Revised Date: 26 May 2022

Accepted Date: 15 June 2022

Please cite this article as: E. Peiretti, G. Demarinis, C. Casu, A. Scano, Orru'. Germano, Oral-ocular trans infection of Epstein Barr virus. A possible new way of transmission by wearing masks in the SARS-CoV-2 era, *American Journal of Ophthalmology Case Reports* (2022), doi: https://doi.org/10.1016/j.ajoc.2022.101626.

Oral-ocular trans infection of Epstein Barr virus.

A possible new way of transmission by wearing masks in the SARS-CoV-2 era

Enrico Peiretti[(1)], MD, Giuseppe Demarinis[(1)], MD, Cinzia Casu[(2)], DMD, Alessandra Scano[(3)], MD, Germano Orru'[(3)], PhD.

(1) Eye Clinic, Department of Surgical Science, University of Cagliari, Cagliari, Italy

(2) International PhD in Innovation Sciences and Technologies (IST), University of Cagliari

(3) Department of Surgical Sciences, Molecular Biology Service (MBS), University of Cagliari, 09124 Cagliari, Italy

Corresponding author:

Enrico Peiretti, MD

Eye Clinic, University of Cagliari,

Via Ospedale 48, 09124 Cagliari, Italy

Phone: 00390706092283

Fax: 00390706092319

Email: enripei@hotmail.com

Abstract

Purpose

To describe a case of an infective vitreitis with an exudative retinal detachment in a 56-year-old lady who was previously affected by severe acute respiratory syndrome coronavirus 2 (SARS-CoV-2).

Observations

A broad workup for infections including the main viruses and bacteria was performed. Salivary droplets, tear film and vitreous samples were collected, resulting positive only for Epstein-Barr virus (EBV). Viraemia and immunoglobulin M for EBV negative, whereas immunoglobulin G positive. The patient showed a simultaneous painless erosion on the right margin of the tongue that's with the lab swab demonstrated the presence of EBV at the same time the vitreitis in the left eye was present.

Conclusions and Importance

Our speculation is that a continuous use of the mask, especially in immunocompromised subjects, it might create a new route for spreading infectious oral agents in the ocular area, and this case is a warning for all the ophthalmologists that have to be aware of this threatening possibility in the COVID era.

Keywords: COVID-19, MASK, ORAL-OCULAR INFECTION

1. INTRODUCTION

Epstein-Barr Virus (EBV), also known as Human HerpesVirus-4 (HHV-4), is a γ-type herpesvirus with a global infection prevalence of over 95%. This was discovered in the 1964 by electron microscopy of cells cultured from Burkitt's lymphoma tissue by Epstein, Achong, and Barr.[1] Four years later, EBV was shown to be the etiologic agent of heterophile-positive infectious mononucleosis.[2] Subsequently in 1970, EBV DNA was detected in tissues from patients with nasopharyngeal carcinoma.[3] Since then, EBV was found to be associated with non-Hodgkin's lymphoma, oral hairy leucoplakia in patients with the acquired immunodeficiency syndrome and in tissues from other cancer: T-cell lymphomas and Hodgkin's disease.[4,6]

The reported ocular manifestations of systemic EBV infection, described in all segments of the eye, commonly involve external and anterior segment surface.[7] In this context, conjunctival inflammation has been reported in association with keratitis, with the description ranging from mild hyperaemia to mild follicular reaction of the superior and inferior tarsal conjunctiva.[8] Ocular EBV infection was described also as uveitis, vitreitis and optic disc vasculitis.[9] In this context, sporadic case reports described ocular manifestations involving the posterior segment in patients with evidence of EBV infection e.g. uveitis in two patients with clinical and serologic signs of "chronic" EBV infection or EBV retinitis. [10,11] To date, there are four reports of Acute Retinal Necrosis (ARN) in immunodepressed patients.[12,14]A recent case report described an immunocompetent patient who developed EBV-associated ARN (EBV–ARN). [15]

We report herein a presumed case of EBV infection of the retina in a healthy woman who was previously affected by severe acute respiratory syndrome coronavirus 2 (SARS-CoV-2).

2. CASE REPORT

A 51-year-old-woman was referred to our retina unit after 2 weeks from a previous diagnosis of unidentified panuveitis. She first attended our clinic complaining a progressive and painless vision loss in the left eye for the past 3-4 weeks. Her disorder occurred 10 days after the first positive swab for COVID. Until SARS-CoV-2 infection, her past medical history was unremarkable. In addition, she reported non-specific symptoms like fatigue, insomnia, headaches, myalgia, and confusion a few days before the worsening of visual acuity (VA). Therefore, physical and ophthalmological investigations were done. Concerning the latter, the VA was light perception in the left eye and 20/20 in the right eye. Anterior segment evaluation revealed anterior chamber cell traits and normal examination in the right eye. Intraocular pressure was 18 in both eyes. Fundus examination was not evaluable for a dense vitreitis. The right eye fundus was unremarkable. Moreover, a B-scan ultrasonography was performed, and it showed an exudative total retinal detachment (Fig.1a). While, on physical examination no abnormalities were found, except for the oral district, where a painless erosion was reported on the right margin of her tongue (Fig.1b). Considering these results, a broad workup for infections, inflammatory and

masquerade aetiologies was done. Serum Test for HIV, Syphilis and Tuberculosis were negative. Blood titers were positive for Herpes Simplex Virus 1 IgG, Toxoplasmosis IgG, Rubeola IgG, Cytomegalovirus (CMV) IgG and SARS-CoV-2 IgG. Epstein Barr Virus (EBV) nuclear antigen IgG was elevated, whereas IgM specific antibodies to EBV capsid antigen were negative. Investigation including complete blood count, erythrocytes sedimentation rate, C-reactive protein, electrolytes, creatinine and liver panel were normal.

Therefore, a diagnostic vitrectomy was performed, and a vitreous sample was sent to the laboratory to perform Polymerase Chain Reaction (PCR) for Herpes Simplex Virus 1-2, CMV, EBV, Tuberculosis, Toxoplasmosis, Rubeola, SARS-CoV-2. PCR of vitreous sample was only positive for EBV virus. EBV DNA was also detected in the tear film of the left eye ($2.5*10^3$ viral genomes/mL real time qPCR method). (Fig.1c). Further investigation revealed the presence of EBV DNA in the swab on the cheeks, on the tongue erosion, and in the saliva, with a viral titer $4.5*10^4$ viral genomes/mL real time qPCR method. EBV-DNA was also detected in the salivary droplets of the breath air exhaled and was recovered by syringe, titer $1.7*10^2$ viral genomes/mL air. (Fig.1c). DNA blood samples analyzed daily for the subsequent two weeks, with cycle threshold (CT) in real time qPCR >40, confirmed the absence of both EBV and SARS-CoV-2 virus. The patient underwent pars plana vitrectomy combined with lens removal and silicone oil tamponade. The second vitreous sample, taken at the time of surgery, confirmed the only presence of EBV virus. Both one month and three months after surgery, the entire retina was attached and VA improved to 6/120.

3. DISCUSSION

Vitreitis is a serious complication of inflammatory or infectious disease of the eye, once diagnosed, the challenge is to find the cause and eliminate it. To achieve this, the patient undergoes a battery of exams, that often turn out to be inadequate and further invasive investigations are necessary.

In this case, the patient's blood tests were negative for any kind of ongoing infection and as a result a diagnostic vitrectomy was required. The result of the analysis of the vitreous sample was a posterior uveitis caused by Epstein-Barr (EBV). EBV is a ubiquitous virus associated with a variety of different diseases and disorders. Acute EBV infection is associated with infectious mononucleosis, while chronic EBV infection is characterized by lifelong latency in transformed B lymphocytes, with the potential for reactivation.[16] EBV can be reactivated as the result of a variety of stressor events.[17] In a study by Gold et al, authors suggests that EBV reactivation occurred soon after or concurrently with contraction of the SARS-CoV-2 infection.[18] The current patient was previously affected by Covid-19 and after a short period of time she manifested ocular and general symptoms. The ocular examination alone could only suggest EBV reactivation following a Sars-CoV-2 infection that resulted in uveitis, but negative blood tests prompted us to carry out additional investigations. The only finding detected was the presence of a painless erosion in the oral cavity on the right margin of patient’s tongue. More extensive examinations revealed not only the presence of EBV DNA near this lesion, but also the presence of EBV-DNA in the

saliva, droplets of the breath air exhaled and tear film of the left eye. In a recent article by Dbouk and Drikakis, the authors investigated the flow physics of respiratory droplets arising from coughing around and through a face mask. They reported that the mask to face fitting is important. Even in the case of a tight fitting scenario, if there exist some small openings, this can lead to additional leakage of droplets around the mask.[19]

To our knowledge this is the first case of the simultaneous presentation of two lesions in two different district due to EBV reactivation in an immunocompetent patient after Covid-19. We can speculate that the SARS-CoV-2 infection played a role in the reactivation of the EBV specifically in oro-facial district, but not as a systemic reactivation, as the blood tests suggested. This scenario could be a consequence not only of the anatomical continuity of these districts but also of presence of a new path created by mask-wearing. Facial masks are currently required indoors and within human communities. Masks prevent the spread of infected salivary droplets to subjects nearby. Furthermore, droplet salivary flux changes direction in mask wearers (Fig 1d), in particular towards the eyes. In this context, the oral and ocular mucosae, strongly connected by a continuous salivary bridge, could increase the risk of spreading oral pathogens to the ocular area. This hypothesis could be validated by a prompt clinical observation of simultaneous oral/ocular infection. Although more cases are necessary to confirm this hypothesis, we speculate that oral-ocular infection *due to mask* could be possible.

4. CONCLUSIONS

A concomitant oral-ocular Epstein Barr virus infection was observed in a 56-year-old patient, in whom "infection by mask" was confirmed by clinical and laboratory observations. In conclusion, this case is a warning for all the ophthalmologists that have to be aware of this threatening oral ocular condition in the COVID era, especially in immunocompromised patients.

Patient consent

The patient consented to publication of the case in writing.

Acknowledgments and Disclosures

Funding: No funding or grant support

Conflicts of Interest: The following authors have no financial disclosures: (E.P., G.D., C.C.,A.S., G.O.)

Authorship: All authors attest that they meet the current ICMJE criteria for Authorship

Acknowledgments: The authors would like to express our special thanks to Michele Loi, who referred the patient to our attention. (Michele Loi, MD from the Eye Clinic of San Francesco Hospital, Nuoro, Italy)

References

1. Epstein MA, Achong BG, Barr YM, Virus Particles in Cultured Lymphoblasts from Burkitt's Lymphoma. *Lancet*. 1964;1(7335):702-703.
2. Griffin BE. Relation of Burkitt's tumor-associated herpes-type virus to infectious mononucleosis. *Rev Med Virol*. 1998;8(2):61-66.
3. zur Hausen H, Schulte-Holthausen H, Klein G, et al. EBV DNA in biopsies of Burkitt tumours and anaplastic carcinomas of the nasopharynx. *Nature*. 1970;228(5276):1056-1058.
4. Ziegler JL, Drew WL, Miner RC, et al. Outbreak of Burkitt's-like lymphoma in homosexual men. *Lancet*. 1982;2(8299):631-633.
5. Greenspan JS, Greenspan D, Lennette ET, et al. Replication of Epstein-Barr virus within the epithelial cells of oral "hairy" leukoplakia, an AIDS-associated lesion. *N Engl J Med*. 1985;313(25):1564-1571.
6. Jones JF, Shurin S, Abramowsky C, et al. T-cell lymphomas containing Epstein-Barr viral DNA in patients with chronic Epstein-Barr virus infections. *N Engl J Med*. 1988;318(12):733-741.
7. Wong KW, D'Amico DJ, Hedges TR 3rd, Soong HK, Schooley RT, Kenyon KR. Ocular involvement associated with chronic Epstein-Barr virus disease. *Arch Ophthalmol*. 1987;105(6):788-792.
8. Matoba AY, Wilhelmus KR, Jones DB. Epstein-Barr viral stromal keratitis. *Ophthalmology*. 1986;93(6):746-751.
9. Hershberger VS, Hutchins RK, Witte DP, Schneider S, Harris RE, McGonegle SJ. Epstein-Barr virus-related bilateral acute retinal necrosis in a patient with X-linked lymphoproliferative disorder. *Arch Ophthalmol*. 2003;121(7):1047-1049.

227 10. Lee JH, Agarwal A, Mahendradas P, et al. Viral posterior uveitis. *Surv Ophthalmol*.
228 2017;62(4):404-445.
229 11. Takahashi H, Takase H, Arai A, Mochizuki M, Ohno-Matsui K. Bilateral granulomatous
230 panuveitis in two patients with T-cell type of chronic active Epstein-Barr virus
231 infection. *BMC Ophthalmol*. 2019;19(1):83. Published 2019 Mar 29.
232 doi:10.1186/s12886-019-1090-5
233 12. Hamam RN, Mansour A, El Mollayess G. Positive Epstein-Barr virus polymerase chain
234 reaction in a case of acute retinal necrosis. *Can J Ophthalmol*. 2012;47(6):e61-e62.
235 13. Schaal S, Kagan A, Wang Y, Chan CC, Kaplan HJ. Acute retinal necrosis associated with
236 Epstein-Barr virus: immunohistopathologic confirmation. *JAMA Ophthalmol*.
237 2014;132(7):881-882.
238 14. Oe C, Hiraoka M, Tanaka S, Ohguro H. Acute Retinal Necrosis Associated with Epstein-
239 Barr Virus in a Patient Undergoing Immunosuppressive Therapy. *Case Rep Ophthalmol*.
240 2016;7(1):195-201. Published 2016 Apr 12.
241 15. Chan EW, Sun V, Eldeeb M, Kapusta MA. Epstein-Barr Virus Acute Retinal Necrosis in an
242 Immunocompetent Host. *Retin Cases Brief Rep*. 2021;15(4):412-416.
243 16. Walling DM, Flaitz CM, Nichols CM. Epstein-Barr virus replication in oral hairy
244 leukoplakia: response, persistence, and resistance to treatment with valacyclovir. *J*
245 *Infect Dis*. 2003;188(6):883-890.
246 17. Glaser R, Rice J, Sheridan J, et al. Stress-related immune suppression: health
247 implications. *Brain Behav Immun*. 1987;1(1):7-20.
248 18. Gold JE, Okyay RA, Licht WE, Hurley DJ. Investigation of Long COVID Prevalence and Its
249 Relationship to Epstein-Barr Virus Reactivation. *Pathogens*. 2021;10(6):763. Published
250 2021 Jun 17.

19. Dbouk T, Drikakis D. On respiratory droplets and face masks. *Phys Fluids (1994)*. 2020;32(6):063303.

Figure Captions

Fig. 1 (A). Left eye ultrasound shows a V shaped elevation of the neurosensory layers (yellow arrow) with diffuse mobile opacities on high gain, taking on a "snow globe" appearance. **(B).** Tongue erosion bigger than 1,5 cm on the right margin (yellow arrow) in which EBV DNA has been found (**C).** Viral titre (genomes/mL) detected in three biological samples(**D).** Mouth-eye contamination through simulation with medical manikin wearing surgical mask (yellow arrow). It is possible to notice how the aerosol coming from the mouth is directed into the ocular area.

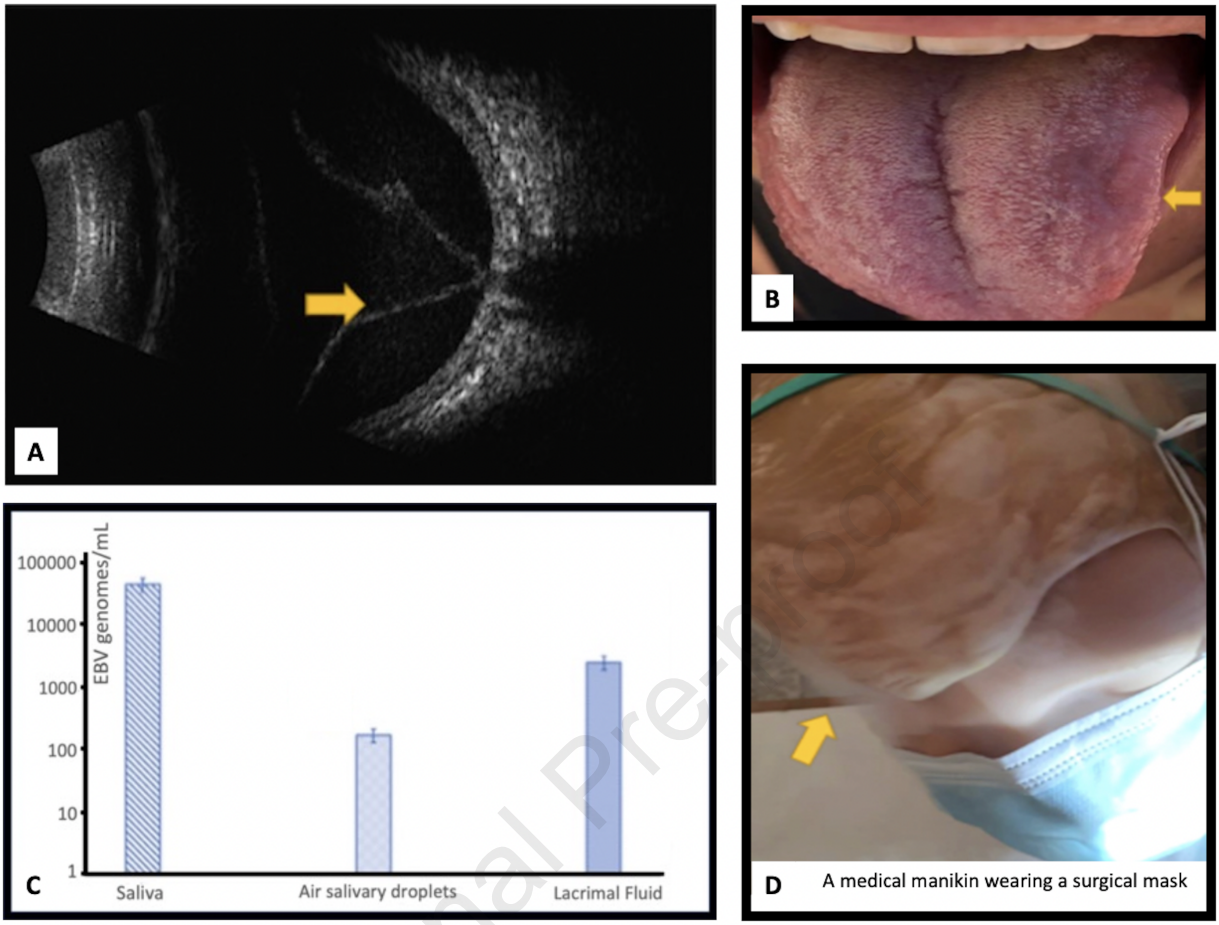

Author declaration

[Instructions: Please check all applicable boxes and provide additional information as requested.]

1. Conflict of Interest

Potential conflict of interest exists:

We wish to draw the attention of the Editor to the following facts, which may be considered as potential conflicts of interest, and to significant financial contributions to this work:

The nature of potential conflict of interest is described below:

☒No conflict of interest exists.

We wish to confirm that there are no known conflicts of interest associated with this publication and there has been no significant financial support for this work that could have influenced its outcome.

2. Funding

☐Funding was received for this work.

All of the sources of funding for the work described in this publication are acknowledged below:

[List funding sources and their role in study design, data analysis, and result interpretation]

☒No funding was received for this work.

3. Intellectual Property

☒We confirm that we have given due consideration to the protection of intellectual property associated with this work and that there are no impediments to publication, including the timing of publication, with respect to intellectual property. In so doing we confirm that we have followed the regulations of our institutions concerning intellectual property.

4. Research Ethics

☒We further confirm that any aspect of the work covered in this manuscript that has involved human patients has been conducted with the ethical approval of all relevant bodies and that such approvals are acknowledged within the manuscript.

☐IRB approval was obtained (required for studies and series of 3 or more cases)

☒Written consent to publish potentially identifying information, such as details or the case and photographs, was obtained from the patient(s) or their legal guardian(s).

5. Authorship

The International Committee of Medical Journal Editors (ICMJE) recommends that authorship be based on the following four criteria:

1. Substantial contributions to the conception or design of the work; or the acquisition, analysis, or interpretation of data for the work; AND

2. Drafting the work or revising it critically for important intellectual content; AND

3. Final approval of the version to be published; AND

4. Agreement to be accountable for all aspects of the work in ensuring that questions related to the accuracy or integrity of any part of the work are appropriately investigated and resolved.

All those designated as authors should meet all four criteria for authorship, and all who meet the four criteria should be identified as authors. For more information on authorship, please see http://www.icmje.org/recommendations/browse/roles-and-responsibilities/defining-the-role-of-authors-and-contributors.html#two.

☒All listed authors meet the ICMJE criteria. We attest that all authors contributed significantly to the creation of this manuscript, each having fulfilled criteria as established by the ICMJE.

☐One or more listed authors do(es) not meet the ICMJE criteria.

We believe these individuals should be listed as authors because:

[Please elaborate below]

☒We confirm that the manuscript has been read and approved by all named authors.

☒We confirm that the order of authors listed in the manuscript has been approved by all named authors.

6. Contact with the Editorial Office

The Corresponding Author declared on the title page of the manuscript is:

ENRICO PEIRETTI

☒This author submitted this manuscript using his/her account in EVISE.

☒We understand that this Corresponding Author is the sole contact for the Editorial process (including EVISE and direct communications with the office). He/she is responsible for communicating with the other authors about progress, submissions of revisions and final approval of proofs.

☒We confirm that the email address shown below is accessible by the Corresponding Author, is the address to which Corresponding Author's EVISE account is linked, and has been configured to accept email from the editorial office of American Journal of Ophthalmology Case Reports:

enripei@hotmail.com

☐Someone other than the Corresponding Author declared above submitted this manuscript from his/her account in EVISE:

[Insert name below]

☒We understand that this author is the sole contact for the Editorial process

(including EVISE and direct communications with the office). He/she is responsible for communicating with the other authors, including the Corresponding Author, about progress, submissions of revisions and final approval of proofs.

We the undersigned agree with all of the above.

Author's name (First, Last)	Signature	Date
1. Enrico Peiretti	_____.	20/10/2020
2. Giuseppe Demarinis	_____	20/10/2020
3. Cinzia Casu	_____	20/10/2020
4. Alessandra Scano	_____	21/10/2020
5. Germano Orrù	_____	21/10/2020
6. _____	_____	_____
7. _____	_____	_____
8. _____	_____	_____
9. _____	_____	_____
10. _____	_____	_____